International Journal of Allied Medical Sciences and Clinical Research (IJAMSCR)

ISSN:2347-6567

IJAMSCR | Volume 9 | Issue 2 | Apr - Jun - 2021
www.ijamscr.com

Research Study | Medical research

Salivary gland Lesions – A Histopathological study in a Tertiary care centre

Dr. Yadav Chavan[1], Dr. Natasha Patel[2]

[1]Associate Professor, [2]Resident Doctor (3rd year), Department of Pathology, Dr.Shankarrao Chavan Government Medical College and Hospital Nanded, India

***Corresponding Author**: **Dr. Natasha Patel**
Email id: natashapatel450@gmail.com

ABSTRACT

Introduction: Salivary gland lesions constitute <1% of all tumors and about less than 4% of all epithelial neoplasm in head and neck region and are therefore relatively rare. These tumors not uncommonly pose problems in diagnosis due to rarity, broad morphologic spectrum and morphologic overlap among the different tumor types .Proper diagnosis of malignant tumors with accurate staging is very important in the treatment and management of the patient

Aims and objectives: To study the histopathological spectrum of salivary gland neoplasm in patients presenting to a tertiary care center

Materials and methods: The present study was conducted in the Pathology department of Dr.Shankarrao Chavan Government Medical College and Hospital , Nanded , on the surgically resected salivary gland tumor specimens received for routine histopathological evaluation, from January 2020 to January 2021.

Results: In the present study parotid gland was the most commonly affected i.e., in 41(78.85%) patients followed by submandibular gland in 9 (17.31%) patients and 2(3.84%) patients had lesions in minor salivary glands. Among the 43 neoplastic lesions, 31 (72.09%) cases were be nignneoplasms and 12(27.91%) were malignantneoplasms. Pleomorphic Adenoma was the most common salivary gland tumor followed by war thin tumor. Mucoepidermoid carcinoma was reported to be the most common malignant salivary gland tumor

Conclusion: Salivary gland tumors are relatively less common and they exhibit a wide variety of microscopic appearances even within one particular lesion. Accurate diagnosis is essential as salivary gland neoplasm have diverse clinical and prognostic outcomes.

Keywords: Histopathology, salivary gland tumors, pleomorphic adenoma, benign neoplasm

INTRODUCTION

Salivary gland lesions constitute <1% of all tumors and about less than 4% of all epithelial neoplasm in head and neck region and are therefore relatively rare [1].

There are three major salivary glands-parotid, submandibular, and sublingual as well as minor salivary glands distributed throughout the mucosa of the oral cavity. Minor glands are present in the mucosal lining of the upper aero digestive tract and can be found in lips, gingiva, floor of the mouth, cheek, hard and soft palate, tongue, tonsillar areas and oropharynx [2,3]

The lesions of salivary glands are commonly encountered clinical problems and range from non neoplastic lesions like inflammation (sialadenitis) and cysts, commonest benign tumour like pleomorphic adenoma to malignant lesions of variable malignant potential[4].

A salivary gland neoplasm consists of a wide variety of benign and malignant tumors.

Salivary gland tumors are 12 times more frequent in parotid gland than in submandibular gland. The majority are benign and largely represented by pleomorphic adenoma[5,6] .

Parotid gland accounts for nearly 80% of the salivary gland tumors followed by the submandibular gland accounting for approximately 10-15% of the tumors. 80-85% of the tumors

are benign in nature with Pleomorphic adenoma being the most common tumor constituting 70% of benign tumours[7].
These tumors not uncommonly pose problems in diagnosis due to rarity, broad morphologic spectrum and morphologic overlap among the different tumor types. These tumors exhibit differences in biological behavior and also in prognosis.
As a general rule in clinical practice, the smaller the salivary gland is, the more likely the tumor is malignant. Proper diagnosis of malignant tumors with accurate staging is very important in the treatment and management of the patient
With this background we intend to study the wide array of histopathology of salivary gland at our tertiary care centre.

OBJECTIVES

To study the histopathological spectrum of salivary gland neoplasm in patients presenting to a tertiary care center.

MATERIALS AND METHODS

The present study was conducted in the Pathology department of Dr.Shankarrao Chavan Government Medical College and Hospital , Nanded , on the surgically resected salivary gland tumor specimens received for routine histopathological evaluation, from January 2020 to January 2021.

METHOD OF DATA COLLECTION

For prospective cases, we studied the salivary gland tumor specimens received in the Pathology department in 10% formalin. In every case the standard protocol for surgical grossing of the specimens was followed.
After conventional processing, paraffin sections of 5µm thickness were stained by haematoxylin and eosin (H & E) for histopathological study. For the retrospective cases, the histopathology reports, slides and paraffin blocks were retrieved from the archives. Additional sections were made from the retrieved paraffin blocks.
Sample size - A total of 52 cases were studied.

RESULTS

Out of 52 cases, majority of the patients, 30 were females accounting for57.7% and 22were males (42.3%) ,with male to female ratio of 1:1.36. The youngest female was 16 year old and oldest was 70 year old.

Table1:Age and Sex Distribution of the Cases

AGE (YEARS)	MALES (Number)	PERCENTAGE Males(%)	FEMALE (Number)	PERCENTAGE Females(%)	TOTAL CASES
11-20	4	18.18	5	16.67	9
21-30	2	9.09	8	26.66	10
31-40	7	31.82	5	16.67	12
41-50	2	9.09	6	20	8
51-60	5	22.73	3	10	8
61-70	2	9.09	3	10	5
TOTAL	**22**	**100**	**30**	**100**	**52**

In the present study parotid gland was the most commonly affected i.e., in 41(78.85%) patients followed by submandibular gland in 9 (17.31%) patients and 2(3.84%) patients had lesions in minorsali vary glands. Among 9 non neoplasticlesions, 5 (55.6%) patients had chronic sialadenitis, followed by cysticlesions in 2(22.22%) cases andone(11.11%)case of eachof acute sialadenitis and mucocele .

Table 2:Site and Sex Distribution of cases

SITE	SEX	NOOF PATIENTS	PERCENTAGE(%)
PAROTID	MALE	17	77.27
	FEMALE	24	80
SUBMANDIBULAR	MALE	5	22.73
	FEMALE	4	13.33
MINORSALIVARY GLANDS	MALE	0	0
	FEMALE	2	6.67
TOTAL		**52**	**100**

Table3: Distribution of Non Neoplastic Lesions

LESIONS	NOOFPATIENTS	PERCENTAGE(%)
Acutesialadenitis	1	11.11
Chronicsialadenitis	5	55.56

Cystic lesion	2	22.22
Mucocele	1	11.11
TOTAL	**9**	**100**

Among the 43 neoplastic lesions, 31 (72.09%) cases were benign neoplasmsand12(27.91%) were malignantneoplasms. Asdepicted in the table, out of 31 benign neoplastic lesions, 29 (93.55%) patients had pleomorphic adenoma followed by 2 (6.45%) cases of Warthin‟ stumour. Out of 12 malignant neoplasticlesions, 10 (83.34%) cases were low grade Mucoepidermoid carcinoma, 2(16.66%) was adenoid cystic carcinoma .

Table4: Distribution of Neoplastic Lesions

BENIGNNEOPLASTICLESIONS			**MALIGNANTNEOPLASTICLESIONS**		
LESION	**NO OF PATIENTS**	**PERCENTAGE(%)**	**LESION**	**NO OF PATIENTS**	**PERCENTAGE(%)**
Pleomorphicadenoma	29	93.55	Muco-epidermoidcarcinoma Low grade	10	83.34
			Highgrade	0	0
Warthin‟stumour	2	6.45	Adenoidcystic carcinoma	2	16.66
Total	31	100	Total	12	100

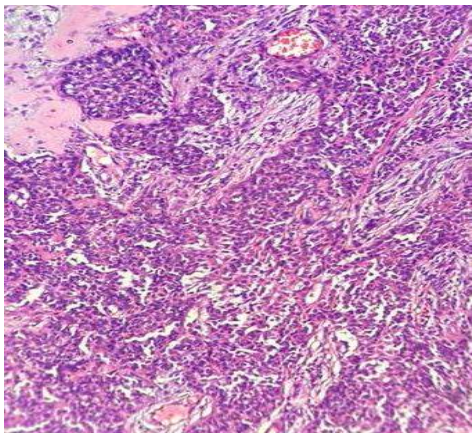

Fig 1: Pleomorphic adenoma, H & E stain(10X)

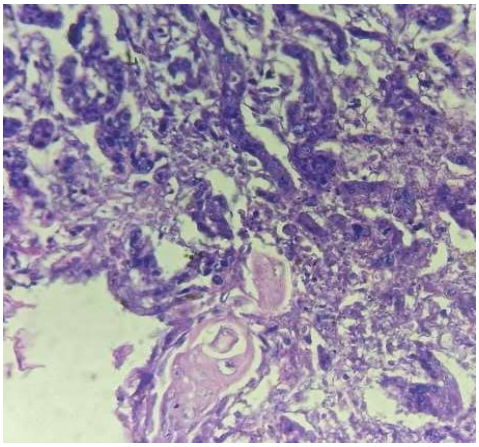

Fig 2: Mucoepidermoid carcinoma, H & E stain(10X)

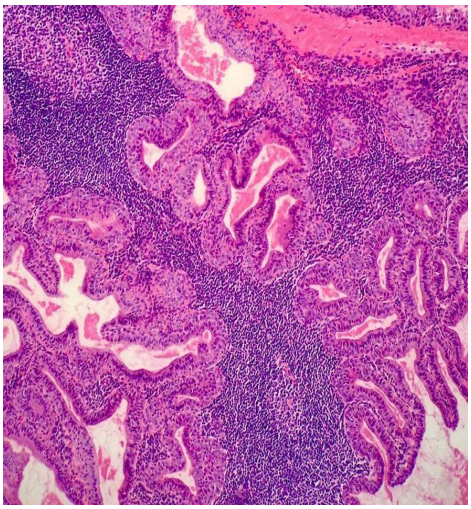

Fig 3: Warthin's tumor, H & E stain(10X)

DISCUSSION

Present study included 52 cases of salivary gland neoplasm. Most of the patients with salivary gland tumors were between the age group of 20-40 years .

Benign tumors constituted majority of the cases. Out of 66 cases, 38 cases (57%) were benign tumors and 28 cases (43%) were malignant tumors. This observation was similar to the studies by Nepal *et al*. [8], Ali *et al*. [9] and Moghadam SA *et al*. [10] in which they have observed predominance of benign tumors over the malignant ones .

All salivary gland tumors were common in women except warthin tumor which was common in males. Dandapat *et al*. [11] and Rewsuwan *et al*. [12] also reported a female preponderance in their series

Pleomorphic Adenoma was the most common salivary gland tumor followed by warthin tumor. There were 29 cases of Pleomorphic adenoma, representing 93.5% of benign and 67.4% of total salivary gland neoplasm

The observed findings were similar to the studies conducted by Shrestha S *et al*. [13], Bashir *et al*. [14] and Ali *et al*. [9] in which pleomorphic adenoma was the most common benign tumor followed by Warthin tumor.

Mucoepidermoid carcinoma was reported to be the most common malignant salivary gland tumor. Richardson *et al*. [15] and Ali *et al*. [9] also observed mucoepidermoid carcinoma to be the most common salivary gland tumor in their studies.

Adenoid Cystic Carcinoma constituted 10.6% of all tumors and 25% of malignant ones. It is the second common malignant tumor in our study. This observation is similar to studies by Vergas *et al*. [16]. The common location of Adenoid cystic carcinoma was in minor salivary glands this is similar to the observations done by Bhavani *et al*. [17] and Rewusuwan*et al*. [12]

In our study parotid gland was the commonest site for salivary gland tumors (78.84%) which is similar to the observations by Ahmed *et al*. [18], Pablo *et al*. [21], Rewusuwan*et al*. [12] and Bashir S *et al*. [19].

CONCLUSION

The present study was a single institutional experience where analysis of 52 cases of salivary gland tumors was carried out. The findings of age, sex, site distribution and pathologic features encountered in our study were comparable with other studies. Most common benign tumor of salivary gland was Pleomorphic adenoma followed by Warthin's tumor. Most common malignant tumor of salivary gland was Mucoepidermoid carcinoma. Salivary gland tumors are relatively less common and they exhibit a wide variety of microscopic appearances even within one particular lesion. Accurate diagnosis is essential as salivary gland neoplasm have diverse clinical and prognostic outcomes.

REFERENCES

1. Luukkaa H. Salivary gland cancer in Finland incidence, histological distribution, outcome and prognostic factors. Turku, Finland: University of Turku; 2010.
2. Akhter J, Hirachand S, Lakhey M. Role of FNAC in the diagnosis of salivary gland swellings. Kathmandu Univ Med J. 2008; 6(22):204-08.
3. Gandhi SH, Purohit TM, Purohit MB, Jethwani D, Vidja M. FNAC Diagnosis of Salivary Gland Lesions With Histopathological correlation. NJIRM.2013; 4(3):70-7.
4. Zajicek J, Eneroth CM, Jakobsson P. Aspiration biopsy of salivary gland tumors. VI. Morphologic studies on smears and histologic sections from mucoepidermoid carcinoma. Acta Cytol. 1976; 20(1):35-41. PMID 1063519.
5. Eveson JW, Cawson RA. Salivary gland tumours. A review of 2410 cases with particular reference to histological types, site, age and sex distribution. J Pathol. 1985; 146(1):51-8. doi: 10.1002/path.1711460106, PMID 4009321.
6. Spiro RH. Salivary neoplasm: overview of a 35-year experience with 2,807 patients. Head Neck Surg. 1986; 8(3):177-84. doi: 10.1002/hed.2890080309, PMID 3744850.
7. Arey LB. Developmental anatomy. Philadelphia: W B Saunders; 1974.
8. Nepal A, Chettri ST, Joshi RR, Bhattarai M, Ghimire A, Karki S. Primary salivary gland tumors in Eastern Nepal tertiary Care Hospital. J Nepal Health Res Counc. 2010; 8(1):31-4. PMID 21879011.
9. Ali NS, Nawaz A, Rajput S, Ikram M. Parotidectomy: a review of 112 patients treated at a teaching hospital in Pakistan. Asian Pac J Cancer Prev. 2010; 11(4):1111-3. PMID 21133633.
10. Moghadam SA, Moghadam FA, Dad far M. Epithelial salivary gland tumors in Ahvaz, Southwest of Iran. J Dent Res Dent Clin Dent Prospect. 2010; 4:120-23.
11. Dandapat MC, Rath BK, Patnaik BK, Dash SN. Tumors of salivary glands. Indian J Surg. 1991; 53:200.
12. Rewusuwan S, Settakorn J, Mahanupab P. Salivary gland tumors in MaharajNakorn Chiang Mai hospital: A retrospective study of 198 cases. Chiang Mai Bull. 2006; 45(2):45-3.
13. Shrestha S, Pandey G, Pun C, Bhatta R, Shahi R. Histopathological Pattern of Salivary Gland Tumors. J Pathol Nep. 2014; 4(7):520-4. doi: 10.3126/jpn.v4i7.10291.
14. Bashir S, Mustafa F, Malla HA, Khan AH, Rasool M, Sharma S. Histopathological spectrum of salivary gland tumors: A 10 year experience. Sch. J. App. Med Sci. 2013; 1(6):1070-4.
15. Richardson GS, Dickason WL, Gaisford JC, Hanna DC. Tumors of salivary glands. An analysis of 752 cases. Plast Reconstr Surg. 1975; 55(2):131-8. doi: 10.1097/00006534-197502000-00001, PMID 1118472.
16. Vargas PA, Gerhard R, Araújo Filho VJ, de Castro IV. Salivary gland tumors in a Brazilian population: a retrospective study of 124 cases. Rev Hosp Clin Fac Med Sao Paulo. 2002; 57(6):271-6. doi: 10.1590/s0041-87812002000600005. PMID 12612759.
17. K B, Urs A N R, J V, Kotasthane S D, G K HISTOPATHOLOGICAL STUDY OF SALIVARY GLAND TUMOURS. jemds. 2016; 5(72):5240-4. doi: 10.14260/jemds/2016/1187.

18. Ahmad S, Lateef M, Ahmad R. Clinic pathological study of primary salivary gland tumors in Kashmir. JK Pract. 2002; 9(4):231-3.
19. Bashir S, Mustafa F, Malla HA, Khan AH, Rasool M, Sharma S. Histopathological spectrum of salivary gland tumors: A 10 year experience. Sch. J. App. Med Sci. 2013; 1(6):1070-4.

How to cite this article: Dr. Yadav Chavan, Dr. Natasha Patel. Salivary gland Lesions – A Histopathological study in a Tertiary care centre. Int J of Allied Med Sci and Clin Res 2021; 9(2): 576-586.

Source of Support: Nil. **Conflict of Interest:** None declared.