International Journal of Allied Medical Sciences and Clinical Research (IJAMSCR)

ISSN:2347-6567

IJAMSCR | Volume 9 | Issue 2 | Apr - Jun - 2021
www.ijamscr.com

Review Study *Medical research*

Review article on keratomalacia –from xerophthalmia due to vitamin a deficiency

Dr.R.Manivannan[1], Dr.S.Kameshwaran[2], V.Srividhya[3*], U.Jegatheesh[4], S.Balaji[5]

Excel College Of Pharmacy, Komarapalayam, Namakkkal-637303,Tamilnadu, India.

***Corresponding author: V.Srividhya**
Email id: srividhyaveeramuthu1995@gmail.com

ABSTRACT

An significant cause of pediatric ocular morbidity remains vitamin A deficiency, more than five million children are affected due to this condition.Annually, xerophthalmia leaves a quarter of a million or more blind.It is also a causes of route, particularly in Africa, for measles-associated blindness.Keratomalacia is uncommon in neonates because it is related to vitamin A deficiency, but it is recorded from developed countries in infants. Malnutrition is one of the primary causes of vitamin A deficiency-blinding deficiency. The treatment is practical and affordable, dependent on oral administration of 200,000 IU of vitamin A for two consecutive days at a cost of 10 cents U.S. Prevention is perhaps more important than care, considering the possible rapidity of corneal necrosis (keratomalacia) and the relative inaccessibility of clinical facilities to those at greatest risk. Oral administration of high-dose vitamins (2000,000 IU per 3 to 6 months), vitamin A fortification of widely eaten products, or, most of all, improved nutritional consumption of natural vitamin A sources will decrease the number of young children who are unnecessarily blind. Given recent evidence that vitamin A deficiency greatly increases overall mortality, even among children without evidence of xerophthalmia, the same prophylactic regimen may improve child survival by 35% or more.

Keywords: Keratomalacia, Ulceration of cornea,Vitamin A deficiency, Xerophthalmia

INTRODUCTION

Keratomalacia, which begins with xerophthalmia, is a chronic condition. Xerophthalmia is an eye disease caused by a deficiency in vitamin A that may lead to keratomalacia if left untreated. It is marked by abnormal dryness in the eyes. The disease begins with conjunctiva dryness, also known as conjunctivalxerosis. It then advances to corneal dryness, or corneal xerosis. Then it leads to corneal dryness, or corneal xerosis. Xerophthalmia evolves into keratomalacia in its late stages.[1].

HISTORY

Keratomalacia is an eye (ocular) disease that usually affects both eyes (bilateral) and is a result of extreme vitamin A deficiency. Dietary (i.e., intake) or metabolic deficit may be this deficiency (i.e., absorption**).** For normal vision as well as proper bone formation, healthy skin and the protection of the mucous membranes of the digestive, respiratory and urinary tracts from infection, vitamin A is important**.**

Weak vision at night or in dim light (night blindness) and excessive dryness of the eyes (i.e. xerophthalmia) can be early symptoms, accompanied by wrinkling, gradual cloudiness, and increasing softening of the corneas (i.e., keratomalacia). With progressing vitamin A deficiency, on the delicate membranes covering the whites of the eyes, dry,' foamy,' silver-gray deposits (Bitot spots) can appear. Increasing softening of the corneas can lead to corneal inflammation, rupture (perforation), and degenerative tissue changes without appropriate treatment, resulting in blindness. Furthermore, vitamin A deficiency may have additional effects in some cases, particularly during infancy and childhood. Vitamin A deficiency in the diet and related keratomalacia are a significant cause of childhood blindness in some developed countries. Vitamin A deficit in certain regions also arises in babies and young children as part of non-selective general malnutrition. Vitamin A deficiency and keratomalacia, although rare in developed countries, can

occur secondary to conditions associated with impaired vitamin A absorption, storage or transport, such as celiac disease, ulcerative colitis, cystic fibrosis, liver disease, or bowel bypass surgery, and any condition affecting the absorption of fat-soluble vitamins.[2][3][4]

PATHOLOGY

Characteristic pathological changes that are meant to be attributable to vitamin A deficiency are xerophthalmia and keratomalacia man. It is not straightforward to secure approval for the removal of orbital structures for necropsy. In 1 percent only small account was found of pathological changes. Man Leber (1885) first described the histological changes of the conjunctiva as a bulbar conjunctiva thickening and hyperplasia, with pronounced flattening and cornificatian of the superficial cells, no explanation of changes in corneal epithelium epithelium was found. Sweet and Kang (1935) suggested that a hyaline-like alteration in the superficial cells of the cornea and conjunctiva was the first morphological change (stage of pre-xerosis). Such cells are quickly underpinned and removed by karatohyaline-laden, flattened deeper layer cells that eventually coraify. A hyperplastic, keratinized stratified epithelium is gradually formed. The cornea displays opaqueness, thickening, and patchy areas of xerosis with the cornificatian of surface epithelium (Pillat, 1929), close to Bitot's conjunctiva spots (Mason, 1954), which constitute one of the most distinctive characteristics of well-established xerophthalmia. This state is accompanied by exfoliation and oedema of the stroma and bacterial infiltration of the keratinized surface epithelium thickening. Axis infiltation of lymphoid cells and leucocytes into the t tissues of the cornea and focal necrosis with the formation of new blood vessels, contributing to ulceration and results. Thomas (1955) suggested that there is sub-epithelial vascularization and lymphocytic penetration as the diagnosis of xerosishas progress-sed to keratomalacia. Epithelium displays xerosis-induced thickening, epidermialization, acanthosis, rete peg formation and keratinization. The membrane of Bowman can be damaged. There is cornea perforation of prolapsed iris in the advanced stage (illustrated microphotographically by Friedenwald, Wilder, Maumene, Sanders, Keyes, Hogan, Owens and Owens, 1957c).[5]

RISK FACTORS

In much of the developing world, primary vitamin A deficiency is widespread, especially endemic in South and East Asia, where rice is the staple food.Kids have far smaller reserves of vitamin A than adults. The diet is likely to be low in vitamin A due to decreased consumption, but hunger still influences vitamin A metabolism. Protein-energy malnutrition is linked with keratomalacia. It can lead to zinc deficiency and iron deficiency.[6]. A systemic illness such as measles ('measles blindness'), pneumonia or diarrhoea can precipitate it.[7].It is more likely to occur in the West in the form of: With alcoholism. Extreme mental illness or nutritional limitation, eating disorder.

Fat-soluble vitamin malabsorption - e.g. from cystic fibrosis, celiac disease, pancreatic diseases, liver disease, intestinal bypass surgery, bariatric surgery or inflammatory bowel disease.[8].Biliopancreatic diversion can lead to serious deficiency of vitamin A. The onset of symptoms will take place several years after intestinal surgery. Keratomalacia may occur due to maternal vitamin A deficiency in neonates.Older individuals may also be at higher risk of vitamin A deficiency.[9] In those with low levels of vitamin A, Isotretinoin therapy can precipitate symptoms. Keratomalacia due to unregulated phenylketonuria is described in a case study.[10]

ETIOLOGY

The human body primarily retains vitamin A in the liver. In reconstituting a visual pigment (rhodopsin) within retinal rods that is essential for night vision, vitamin A plays a prime role. It is also essential for the growth and ripening of epithelial cells and proper bone and tooth development. Fish-liver oils, liver, whole cow's milk, other dairy products (e.g. yogurt, cheese), egg yolks, green leafy vegetables, and yellow vegetables and fruits are among the sources of dietary vitamin A. Very commonly, keratomalacia is caused by excessive dietary vitamin A deficiency (i.e., primary vitamin A deficiency). In some areas where rice is a major component of the diet (e.g. East and South Asia), primary vitamin A deficiency is common; rice does not produce beta-carotene, Keratomalacia is also widespread in many malnutrition conditions due to inadequate protein and energy intake (i.e., protein-calorie malnutrition, such as kwashiorkor). In such cases, deficiency of vitamin A can result from dietary malnutrition, as well as vitamin A storage and transport failure which is converted by the body into vitamin A. Vitamin A deficiency and related keratomalacia can also be at risk for babies and children who are allergic to milk or consume dilute formula. (Adequate sources of vitamin A are whole cow's milk and breast milk.). Deficiency of vitamin A and keratomalacia can also occur secondary to certain disorders or conditions marked by incomplete conversion of beta-carotene to vitamin A or impairment of vitamin A storage, absorption or transport (secondary vitamin A deficiency). For example, persistent intestinal disorders such as ulcerative colitis, sprue or celiac disease, cystic fibrosis or other disorders marked by pancreatic insufficiency and related malabsorption, or intestinal bypass surgery may occur with compromised absorption or storage of vitamin A. (duodenal bypass). Impairment of vitamin A storage or absorption can also be linked with small intestine inflammation (giardiasis); partial restriction of the small intestine at birth; obstruction of the bile ducts; or liver disease, such as internal scarring and reduced liver function (cirrhosis). [11],[12]

LIST OF COLOUR PLATES

TABLE:1[Alfred Sommer,vitamin a deficiency and its consequences,a guidebook to detection and control,3rd ed,world health organization: Geneva: 1995.]

COLOUR PLATES	DESCRIPTION
1	Diagram showing xerophthalmia-affected sites
2	Diagrammatic representation of Lesions of Xerophthalmia
3	Conjunctivalxerosis and keratinized surface with a prominent granular cell layer (haematoxylin and eosin) (x 250)
4	Specially stained conjunctivalxerosis to reveal the highly keratinized surface (Dane's stain) (x 185)
5	Temporal patch of conjunctivalxerosis (X1A)
6	Temporal patch of conjunctivalxerosis (X1A)
7-11	Typically foamy Bitot's spots Plate 10, from a South Indian girl, demonstrates marked pigmentation occasionally present in the same area
12-13	Typically "cheesy" Bitot's spots
14-16	Advanced conjunctivalxerosis (X1A) involving all of the bulbar con] unctiva, and mild to moderate corneal xerosis (X2) having a dry, hazy appearance
17	Epithelial punctate lesions with early corneal involvement, bright fluorescein staining
18	Diffuse haze of corneal xerosis (X2)
19-20	Dry, granular appearance of corneal xerosis (X2)
21	Xerosis of the Conjunctival (X1A) and Corneal (X2) Cornea! The interpalpebral zone surface is highly keratinized and surrounded by tenacious debris.
22	Classical "punched-out", peripheral xerophthalmic ulcer (X3A) Corneal surface keratinized inferiorly
23	Hypopyon fluorescein stained oval xerophthalmic ulcer (X3A) and conjunctival injection are present.
24	Multiple corneal lesions invaded and deeply inflamed conjunctiva, often implying secondary infection.
25	Conjunctivalxerosis (X!A) and localized necrosis/keratomalacia involving less than 1/3 of the corneal surface (X3A)
26	Same eye as in Plate 25, one month after vitamin A therapy The localized necrosis has healed as an adherent leukoma (XS)
27-29	Necrosis/keratomalacia affecting the entire cornea (X3B) The conjunctiva is deeply inflamed in Plate 28
30	Widespread necrosis and corneal tissue sloughing culminated in a large decemetocele (XS) that was slow to recover.
31	A damaged, anteriorly bowed, scarred corneal surface, a staphyloma, may result in the healing of extensive necrosis (XS)
32	White retinal specks characteristic of the xerophthalmic fundus (XF)



FIGURE:1 Plate 25. X3A (localized necrosis)[Alfred Sommer,vitamin a deficiency and its consequences,a field guide to detection and control,world health organization:



Figure:2 Plate27. X3B (generalized necrosis)[Alfred Sommer,vitamin a deficiency and its consequences,a field guide to detection and control,3rd ed,world health organization

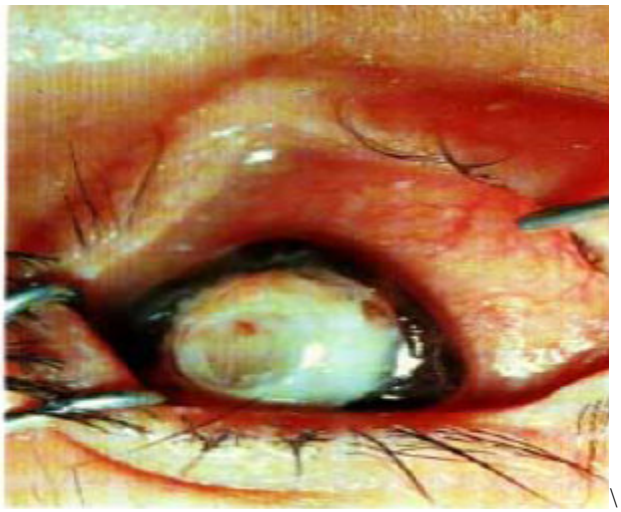

Figure:3 Plate 27. X3B (generalized necrosis)[Alfred Sommer,vitamin a deficiency and its consequences,a field guide to detection and control,3rd ed,world health organization

Ulceration/keratomalacia means that a component is permanently destroyed. All or all of the corneal stroma, which results in irreversible cellular structure Modification. Ulcers are "punched-out" defects which are classically circular or oval, as if a trephine or cork-borer were added to the eye (Plates 22, 23). Generally xerotic, but otherwise transparent, the underlying cornea lacks the gray, infiltrated presence of ulcers of bacterial origin (Plate 24). Small ulcers are almost always limited to the periphery of the cornea, especially its inferior and nasal aspects. The ulceration can be superficial, but deep perforations are typically plugged with iris, retaining the anterior chamber with surgery, Superficial ulcers frequently heal with relatively little scarring, with thick peripheral adherent leukomas developing deeper ulcers, particularly perforations (Plate 26). It first occurs as an opaque, gray to yellow mound or outpouching of the corneal base. Localized keratomalacia is an increasingly progressive disease involving the entire thickness of the cornea (Plate 25). The necrotic stroma sloughs, leaving a more advanced illness. Like for minor ulcers, this is typically a major ulcer or descemetocele. Peripheral, and recovers as a thick, white, leukoma adherent (Plate 26). Ulceration/keratomalacia of less than one-third of the sum.In general, the corneal surface (X3A) spared the central pupillary region,Usually, timely and prompt counseling maintains effective vision. More widespread involvement (X3B), especially widespread liquefaction involvement.

Necrosis (Plates 27-29) typically results in perforation, intraocular material extrusion, and globe destruction. Prompt therapy will also preserve the other eye and the life of the infant. It is not always possible to differentiate cases of ulceration/ necrosis. Infections are caused by vitamin A deficiencies due to bacterial or fungal infections, primarily because vitamin A-related lesions may become secondary diseases. In addition, the conjunctiva typically becomes inflamed once ulceration/keratomalacia develops (Plates 23, 28), and for purposes that are not fully known, Conjunctivalxerosis disappears in the other, unulcerated eye, but not invariably, the true nature of the issue can be exposed. As the vitamin A condition deteriorates precipitously, as in measles, extreme gastroenteritis or kwashiorkor may precede the occurrence of night blindness or conjunctivalxerosis in children previously in borderline

vitamin A balance corneal necrosis. It is best in such situations to conclude that there is a vitamin A deficiency and infection and to treat the children accordingly[13].

PREVENTION

The link between clinically evident symptoms and signs and a bad diet was suggested in humans around 1860, and subsequently verified in many cultures. In the early years of topical treatment or consumption of animal and fish liver, and later years of ingestion of plant food containing green and yellow pigments, cure has been associated with certain foods. McCollum and Davies identified the keratomalacia-preventing, growth-limiting, fat-soluble substances isolated from effective foods, followed shortly afterwards by Osborne and Mendel. These compounds were later designated to be vitamin A and carotenoids.

Daily dietary consumption by breastfeeding and lactating mothers and children under 5 years of age of vitamin A rich foods. The value of avoiding vitamin A deficiency must be made clear to mothers and children participating in the ICDS (Integrated Child Development Services) programme. Breastfeeding and colostrum feeding should be promoted. Vitamin A and green leafy vegetables and yellow and orange vegetables and fruits such as pumpkin, carrots, papaya, mango oragen, cereal and pulse are precursors of bpcarotene-rich foods.[14]

REFERENCES

1. https://www.healthline.com/health/malabsorption#treatment, retrived on jan 28,2021.
2. Sommer A. Xerophthalmia and vitamin A status. ProgRetin Eye Res. 1998;17:9-31.
3. Sommer A. Xerophthalmia, keratomalacia and nutritional blindness. IntOphthalmol. 1990;14:195-99.
4. Newell FW, ed. Ophthalmology: Principles and Concepts. 7th ed. St Louis, Mo: Mosby-Year Book, Inc; 1992:241-43.
5. https://shodhganga.inflibnet.ac.in/bitstream/10603/165659/7/07_chapter%203.pdfretrived on jan 28,2021.
6. Ansstas G et al, Vitamin A Deficiency, eMedicine, Dec 2010
7. Vajpayee RB, Vanathi M, Tandon R, et al; Keratoplasty for keratomalacia in preschool children. Br J Ophthalmol. 2003 May
8. Huerta S, Rogers LM, Li Z, et al; Vitamin A deficiency in a newborn resulting from maternal hypovitaminosis A after Am J ClinNutr. 2002 Aug76(2):426-9
9. Welsh BM, Smith AL, Elder JE, et al; Night blindness precipitated by isotretinoin in the setting of hypovitaminosis A. Australas J Dermatol. 1999 Nov40(4):208-10
10. Danby FW; Night blindness, vitamin A deficiency, and isotretinoinpsychotoxicity. Dermatol Online J. 2003 Dec9(5):30
11. Feng CM. The causes of blindness by corneal diseases in 3,499 cases. Chung Hua Yen KoTsaChih. 1990;26:151-53.
12. Vitte S, et al. Xerophthalmia: current data. Med Trop (Mars). 1995;55:434-38.
13. Alfred Sommer, vitamin a deficiency and its consequences, a field guide to detection and control,World health organization: Geneva: 1995.
14. http://nhm.gov.in/images/pdf/programmes/child-health/guidelines/goi_vit_a.pdfretrived on jan 28,2021

How to cite this article: Dr.R.Manivannan, Dr.S.Kameshwaran,V.Srividhya,U.Jegatheesh, S.Balaji. Review article on keratomalacia –from xerophthalmia due to vitamin a deficiency. Int J of Allied Med Sci and Clin Res 2021; 9(2): 98-102.

Source of Support: Nil. **Conflict of Interest:** None declared.