International Journal of Allied Medical Sciences and Clinical Research (IJAMSCR)

ISSN:2347-6567

IJAMSCR |Volume 9 | Issue 2 | Apr - Jun - 2021
www.ijamscr.com

Research Study *Medical research*

Extracorporeal Irradiation with Limb Salvage Surgery on Femur Osteosarcoma at Dr Kariadi Hospital Semarang

Endah Kurniati*

Radiotherapy Unit, Radiology Department, Dr. Kariadi Hospital, Semarang, Indonesia.

***Corresponding Author**: **Endah Kurniati**
Email: endahgrafer.rsdk@yahoo.com

ABSTRACT

This study aims to determine the procedures, techniques, reasons and evaluation of extracorporeal bone irradiation (ECI) technique with limb salvage surgery (LSS) action on femur osteosarcoma that has been done in Radiotherapy unit of Dr. Kariadi Hospital Semarang. This technique is very rare and for the first time done in Dr. Kariadi Hospital Semarang. The results showed that the ECI technique with the LSS action on the osteosarcoma femur includes the process of bone removal, wrapping, transport, handover, simulator, single dose 50 Gy, 2D TPS technique, irradiation, and bone organ resubmission. Reason for choosing this technique is to save the femur. The evaluation is carried out in stages to monitor the progress of the wound and also the clinical progress after ECI .

Keywords: extracorporeal irradiation, osteoscarcoma, limb salvage surgery

INTRODUCTION

Osteosarcoma is the most common primary malignant tumor in bone and accounts for 72.6% of all cases. Male predominance with a male to female ratio of 1.1:1 [1]. This cancer usually affects adolescents and adults at a productive age. The number of sufferers suffering from osteosarcoma is also increasing every year. Osteosarcoma is the most common non-hemopoietic primary bone malignant tumor. The incidence of osteosarcoma in all populations according to WHO is around 4-5 per 1,000,000 population. The estimated incidence of osteosarcoma increases to 8-11 per 1,000,000 population per year at the age of 15-19 years [2]. The life expectancy of people with bone cancer reaches 60% if it has not spread to the lungs. About 75% of sufferers survive up to 5 years after the disease is diagnosed. Unfortunately, people with bone cancer often come in an advanced state so that treatment becomes more difficult. If not treated immediately, the tumor can spread to other organs, while the healing is very painful because sometimes it requires radical surgery followed by chemotherapy [2].

The healing process for osteosarcoma is done surgically to remove the tumor as a whole. Amputation is a surgical procedure that is most often performed as the best choice for the healing process of osteosarcoma. Patients will experience permanent disabilities for life. Radiation irradiation procedures for osteosarcoma healing are generally carried out

after surgery or post-amputation with the aim of killing any remaining cancer cells. In addition, the radiation technique used also aims to prevent the spread of cancer cells to the lymph nodes around the tumor. Radiation techniques in osteosarcoma healing cases do not have standard guidelines. The existing guidelines on osteosarcoma healing only provide a reference to the radiation dose that will be given without referring to the radiation technique to be carried out [2].

Limb salvage surgery (LSS) is a surgical procedure performed to remove tumors in the extremities with the aim of saving the extremities [2]. Extracorporeal bone irradiation (ECI) is a method of healing osteosarcoma which consists of several processes, namely the removal of the tumor, cleaning the tumor from bone and soft tissue, irradiation or irradiation and then reimplantation into the body [3].

At the Dr. Kariadi Hospital, Semarang, osteosarcoma healing was done using extracorporeal bone irradiation (ECI) techniques with limb salvage surgery using a combination of surgery and radiation techniques at one time. This healing technique is being used for the first time in cases of osteosarcoma in the femur. The first step is surgery for the tumor in the distal femur area in the operating room. The segment of the femur affected by the tumor is removed, separated between the bone and soft tissue. After the femur is clean from the tumor, the bone is wrapped in sterile conditions. In addition to being sterile, the bone wrapping must meet several criteria, namely the bone segments are tightly wrapped with airtight wet sterile gauze, then wrapped in two plastic bags and the thickness of the bone covering material is 3 cm.

The next process, the bone that has been wrapped in sterile conditions is sent to radiotherapy for radiation, while the patient is still in the operating room with general anesthesia. Radiation was performed using antero-posterior and postero-anterior techniques with a single dose of 50 Gy. After the irradiation is complete, the wrapped sterile bone is returned to the operating room for re-implantation.

This extracorporeal bone irradiation (ECI) technique with limb salvage surgery is rarely performed, however, this technique provides better hope for patients to avoid lifelong disability due to amputation [3].

The author is interested in analyzing this case because the extracorporeal bone irradiation (ECI) technique with limb salvage surgery on osteosarcoma femur is the first procedure at Dr. Kariadi Hospital Semarang. Apart from being the first time and the cases are rare, the radiation technique performed is also different from the technique of radiation for osteosarcoma cases in general.

METHODS

This type of research in is a qualitative research with a case study approach that aims to examine and analyze information about the extracorporeal bone irradiation technique with limb salvage surgery on osteosarcoma femur at Dr. Kariadi Hospital Semarang. As research subjects in this paper are Orthopedic Surgeon, Radiation Oncology Specialist, Medical Physicist, and Radiographers at Dr Kariadi Hospital Semarang. This research was conducted in the Radiotherapy Unit of the Radiology Installation at the Dr. Kariadi Hospital, Semarang. The research method used by the author is the observation method by observing directly during the examination process, in-depth interview method to obtain oral information from the respondents and the method of documentation study to document relevant data.

RESULTS AND DISCUSSION

1. Examination technique for Extracorporeal Bone Irradiation with Limb Salvage Surgery
   Examination techniques for extracorporeal bone irradiation with limb salvage surgery at Dr. Kariadi Hospital, Semarang, are:

a. Extracorporeal Bone Irradiation Plan with Limb Salvage Surgery
   After the examination, based on existing supporting data such as x-photos of the femur, MRI and bone scan and blood test results, a coordination meeting was held with all disciplines involved, namely orthopedic surgeons, anesthetists, pathologists. Anatomy, oncologists, medical physicists and radiographers, this is in accordance with the theory of DN Sharma, et. al.[3]. The initial examination of patient care consists of a detailed clinical examination in the clinic by a team consisting of orthopedic surgeons, medical oncologists and radiation oncologists. . Each patient is subjected to various kinds of examinations. Routine hematology tests such as hemograms, liver and kidney function tests were performed for each patient and MRI photos or CT-scans and bone

marrow examinations were performed for Ewing's sarcoma patients.

Patient preparation

Preparation of patients with extracorporeal bone irradiation examination techniques with limb salvage surgery that is needed is a solid multi-disciplinary action, the patient is in good condition for the bone removal, then also monitored by an anesthetist and approved by the surgeon and there are no problems with the results. his blood.

Simulator

According to Bentel [4] the simulator is mainly used to localize the target volume and normal tissue with respect to the radiant field markings on the skin and to reveal the planned radiant field with tumors and normal tissue. Meanwhile, according to DN Sharma, et. al. [3], it is explained that the boundaries of the radiation field are selected which sufficiently cover the bone segments with Anteroposterior and Posteroanterior projections.

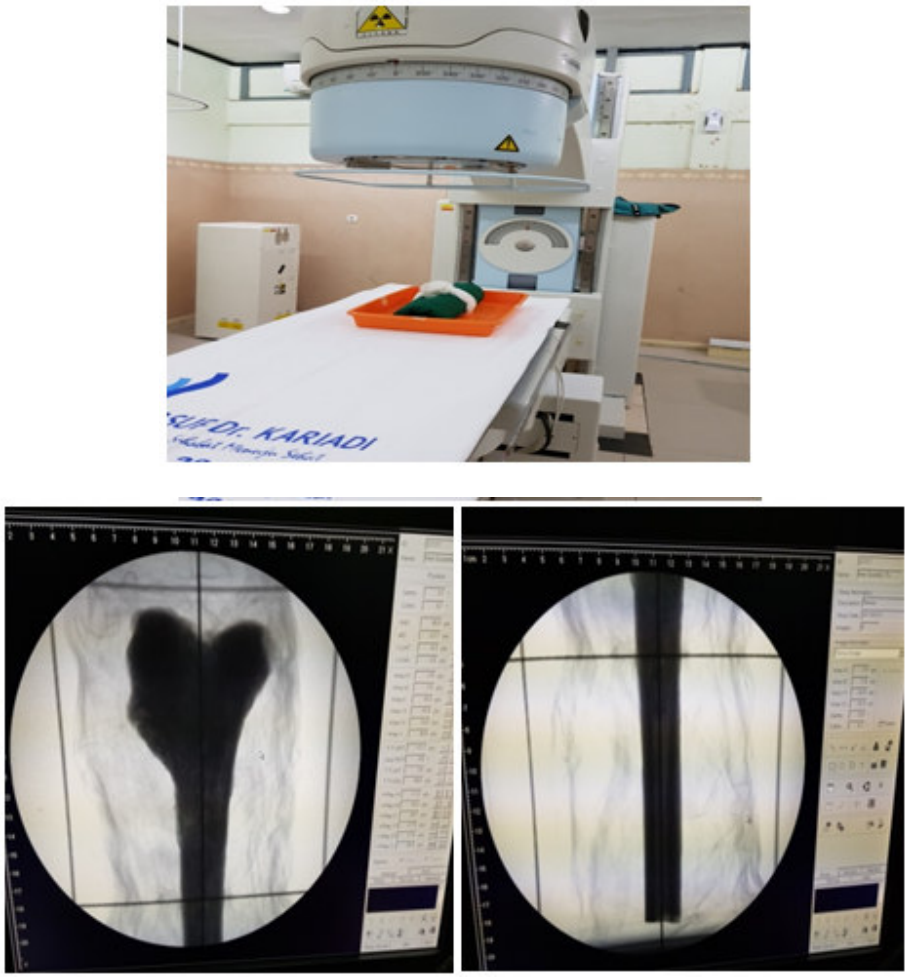

Fig 1. Simulation of femur for preparation ECI

Treatment Planing System (TPS)

According to R Susworo and H. Kodrat [5], to obtain a homogeneous radiation dose on the tumor mass or to avoid critical organs, radiation planning is required based on the curve of each radiation energy in a certain field area. Computer processing in radiation planning is very useful for obtaining good

planning, which is then implemented in patients. The process of the treatment planing system at the Dr. Kariadi Hospital, Semarang, can be made distribution of doses based on contours that have been previously carried out in the simulator room, data from the simulator room which consists of the target or object of radiation, separation / thickness of the patient's organs, total dose and fractionation and is equipped with a name. Patients, names / field projections (Anteroposterior and Posteroanterior) are entered and processed in the Treatment Planning System computer program to obtain treatment time. In the Extracorporeal Bone Irradiation radiation, 2D techniques are used with Anteroposterior and Posteroanterior projections, from the results of data processing in TPS it can be seen that the dose distribution is homogeneous and the histogramspun dose volume curve shows good results, the target tumor gets the optimal dose and does not exceed hot spot.

Treatment Extracorporeal Bone Irradiation

According to D.N. Sharma, et. al. [3] an external examination technique of radiation on the sealed bone segment is sent to a Linear Accelerator for Extracorporeal Bone Irradiation (ECI). The bone segments are placed on the examination table and immobility is ensured. The bone segment was placed in the middle of the irradiated area and irradiated with a single dose of 50 Gy using 6 MV X-rays. The direction of irradiation uses two fields of radiation, namely anteroposterior and posteroanterior which are opposite in parallel. The size of the radiation field is chosen that is sufficient to cover the bone segment. After the completion of the Extracorporeal Bone Irradiation (ECI), the bone segments are sent back to the operating room without any delay for bone implantation back into the body External radiation examination at the Dr. Kariadi Semarang Hospital is by using cobalt teletherapy. Patient data are recorded in the visit book and radiation parameter data is recorded in the patient's medical record book which includes the area of the field, the technique used, the dose, the exposure and the time of exposure. The bone organs are arranged in such a way, on an examination table covered with webs, positioned the same as the position in the simulator, when positioning the radiographer using a handscoon to keep the bone organs sterile. The collimator light and distance scale light are turned on. Field area x = 15 cm, y = 30 cm, gantry position at point 0^0 for AP field, point 180^0 for PA field. The collimator angle in this case is 0. The laser intersection is right at the center point (cross sign, the center point of the intersection of the diagonal line of the field), then the irradiation distance of the SSD = 80 cm is set right on the CP. The door to the lighting room was tightly closed. The treatment time is adjusted according to the print out from the TPS and the dose given is 50 Gy. The bone organs are monitored through a monitor. After the irradiation, the bone organs are handed over to a radiation oncologist and then submitted to a surgeon for reimplantation in the operating room.

According to the author's opinion, the Extracorporeal Bone Irradiation treatment with limb salvage surgery at Dr Kariadi Hospital Semarang is good, but the use of a different treatment tool is using Cobalt. This is done because the single dose technique requires a long exposure time. When using a linac aircraft, with a long irradiation time, a stable electric voltage is needed, an unstable electric voltage will result in a higher risk of irradiation failure, because it is different in choosing modalities for treatment in irradiation, the SSD used is also different, according to DN Sharma's theory, et.al. [3] used the Linac modality with a 100 cm SSD while in the implementation at Dr Kariadi Hospital the ECI technique used cobalt 60 with an 80 cm SSD.



Fig 2. Extracorporeal bone irradiation by using cobalt teletherapy

Reasons for choosing extracorporeal bone irradiation technique with limb salvage surgery on osteosarcoma femur at Dr. Kariadi Hospital Semarang

According to DN Sharma, et. al. [3], Extracorporeal Bone Irradiation Technique with Limb Salvage Surgery on osteosarcoma of the femur has the advantage that the cancerous bone segments are removed from the body and irradiated therefore avoiding injury to bones, muscles, joints and healthy tissues that are not irradiated. The administration of a very high dose of radiation to the bone tumor pads by Extracorporeal Bone Irradiation (ECI), this higher dose in the 50-300 Gy range, kills the remaining tumor cells thereby reducing the risk of recurrence. ECI provides a suitable anatomical branch for biological reconstruction at a relatively low cost compared to prosthetic devices and has the psychological advantage that patients feel that their own bone is used as a prosthesis. The Extracorporeal Bone Irradiation technique with Limb Salvage Surgery on femur osteosarcoma at Dr. Kariadi Hospital Semarang is used for bone cancer therapy or osteosarcoma with the aim of saving the limbs, hopefully the tumors in the bone organs are dead and no longer growing. so that the bone can grow back like a normal broken bone, namely by taking the bone that is affected by cancer, then doing the radiation so that it is hoped that the cancer in the bone will die and after the external action is done, radiation the bone is returned and put together with the previous bone.

2. Evaluation Results of Extracorporeal

Bone Irradiation Technique with Limb Salvage Surgery on osteosarcoma femur at Dr Kariadi Hospital Semarang According to DN Sharma, et.al. [3], patients are followed up every month until 6 months after the treatment. Subsequent surveillance measures are carried out every 3 months up to 2 years. Plain radiographs of the surgical area were performed every 3 months and MRI of the local area was performed every 6 months. To detect pulmonary metastases, a plain chest x-ray is performed every month and a chest CT examination is performed whenever necessary.

The extracorporeal bone irradiation technique with limb salvage surgery on osteosarcoma of the femur can be evaluated by an orthopedic doctor to determine its progress, because organs that have been affected by tumors usually have a longer regeneration process than the fracture process. Fractures that are not due to pathological factors, muscle structure and periostenic structure are good, whereas in the case of tumors the organ structure is different, so it is as if considered a bone graph. Further evaluation can use radiograpic of the femur or CT scan of the area after the patient has undergone ECI procedures. This action can be done a month after the ECI, this is aimed at organ evaluation, both in surgical wounds and on the organs that are clinically abnormal.

At the Dr. Kariadi Hospital, Semarang, extracorporeal bone irradiation with limb salvage surgery is evaluated in the initial week to one month for surgical wound

monitoring while for clinical evaluation it is carried out for one to 6 months, if necessary, supporting examinations can be done to determine the clinical progress. which exists. In this case, the investigations carried out were evaluation of the x-photo of the femur 4 months and 6 months after the ECI was done, this is in accordance with the theory of DN Sharma, et. al. [3], that the post-ECI evaluation was carried out one to 6 months after the procedure.



Fig 3. Radiographic evaluation of the AnteroPosterior and Lateral femur 4 months post ECI

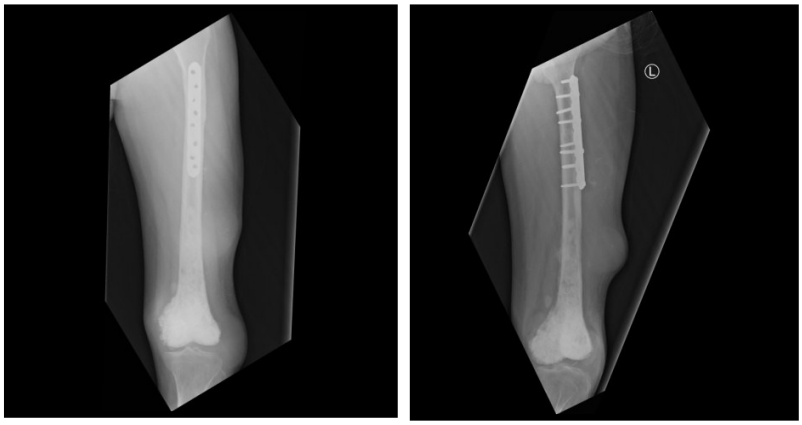

Fig 4. Radiographic evaluation of the AnteroPosterior and Lateral femur 6 months post ECI

CONCLUSION

Extracorporeal Bone Irradiation Technique with Limb Salvage Surgery on femoral osteosarcoma at Dr. Kariadi Hospital Semarang consists of several stages, namely the surgical removal of the bone, the process of handing over bone organs from the surgeon to the radiation oncologist in a sterile state, determining the radiation parameters in a simulator with an irradiation field boundary as large as the bone segment to be radiated, irradiation using a single dose of 50 Gy. After the irradiation, the bone organs are handed over to a radiation oncologist and then submitted to a surgeon for reimplantation in the operating room. The reason for choosing the Extracorporeal Bone Irradiation Technique with Limb Salvage Surgery on osteosarcoma of the femur at Dr. Kariadi Hospital Semarang is to save the limbs in the hope that the tumors in the bone organs die and don't grow again. Evaluation of the Extracorporeal Bone Irradiation Technique examination with limb salvage surgery at the Dr. Kariadi Hospital Semarang was carried out in the initial week to one month after ECI for surgical wound monitoring, while for clinical evaluation it

was carried out with x-photos of the femur 4 months and 6 months post. Performed ECI action.

REFERENCES

1. Y. Pillay, N. Ferreira, and L.C. Marais, "Primary malignant bone tumours: Epidemiological data from an orthopaedic oncology unit in South Africa", South Africa Orthopaedic Journal Summer, 2016.
2. Komite Penanggulangan Kanker Nasional, "Panduan Nasional Pelayanan Kedokteran Kanker Osteosarkoma", Jakarta, 2015.
3. S. Rastogi, S. Bakhshi, G.K. Rath, P.K. Julka, M.A. Laviraj, S.A. Khan, A. Kumar, "Role of extracorporeal irradiation in malignant bone tumors", Indian Journal of Cancer, Vol. 50, Issue 4, pp. 306-309, 2013.
4. G.C. Bentel, "Radiation therapy planning", McGraw-Hill Education, 1996.
5. R Susworo dan H. Kodrat, "Dasar-dasar Radioterapi dan Tata Laksana Radioterapi Penyakit Kanker", 2 ed, Jakarta, Universitas Indonesia, 2017.

How to cite this article: Endah Kurniati. Extracorporeal Irradiation with Limb Salvage Surgery on Femur Osteosarcoma at Dr Kariadi Hospital Semarang . Int J of Allied Med Sci and Clin Res 2021; 9(2): 113-119.

Source of Support: Nil. **Conflict of Interest:** None declared.