International Journal of Allied Medical Sciences and Clinical Research (IJAMSCR)

ISSN:2347-6567

IJAMSCR |Volume 6 | Issue 4 | Oct - Dec - 2018
www.ijamscr.com

Research article *Medical research*

Optimization of abdominal MRI images with the application of PROPELLER

Study on the Application of PROPELLER on Abdominal MRI towards Anatomical Information, Motion Artifact and Image Quality

Fadli Felayani[1], Suryono Suryono[2] and Suhartono[3]

[1]*Department of Epidemiology, School of Postgraduate Study, Diponegoro University,Semarang, Indonesia*
[2]*Department of Physics, Faculty of Science and Mathematic, Diponegoro University,Semarang, Indonesia*
[3]*Department of Environmental Health, Public Health Faculty, Diponegoro University,Semarang, Indonesia*

***Corresponding Author**: **Fadli Felayani**
Email id: fadli.tro.zone@gmail.com

ABSTRACT

Background

Movement of abdominal organs due to breathing on MRI examination on the abdomen causes motion artifacts that may reduce image quality. Abdominal MRI protocol to reduce respiratory motion artifacts is by using respiratory gating, howeverit results in longer time scan. PROPELLER is a technique for filling data matrices radially with a blade coverage value that is able to reduce artifacts.

Objective

To study the application of PROPELLER on abdominal MRI to reduce motion artifacts, get optimal anatomical and image quality information with faster time scan.

Methods

This was an experimental study with one group post test design. The samples in the study were 8 respondents, each of which received 8 treatments. One treatment used respiratory gating as a standard protocol and 7 treatmentsapplied PROPELLER using coverage blade variations of 50%, 75%, 100%, 125%, 150%, 175% and 200%. Assessment included time scan, anatomical information, artifacts, SNR, and CNR. Statistical data analysis usedKruskal Wallis test, Wilcoxon test and Spearman test.

Results

There were differences in anatomical information, CNR, SNR, artifacts and time scan between the use of abdominal MRI image and respiratory gating compared to PROPELLER on 100% blade coverage.

Conclusion

The application of PROPELLER with a 100% blade coverage value was able to reduce motion artifact so as to produce optimal anatomical information and image quality with faster time scan.

Keywords: Abdominal MRI, Motion Artifact, PROPELLER, Respiratory Gating.

INTRODUCTION

The selection of MRI examination parameters can be related to the emergence of artifacts that affect image quality and diagnostic information (Ruan, 2001) [28]. In addition, an MRI operator must pay attention to three basic principles in producing an MRI image, namely good image quality, pathological information that is capable to be displayed and comprehensive anatomical information on the area being evaluated (Brown and Samelka, 2003) [7]. Optimal image quality helps accuracy in diagnosing, so it can avoid errors in diagnosis (Bourne, 2010). On abdominal MRI examination the organs always move due to the patient's breathing and it becomes a problem since it causes motion artifacts that can significantly reduce image quality (Low et al., 1997).

There are two techniques commonly used in the abdominal MRI examination protocol to eliminate artifacts due to breath movements, namely breath-hold and respiratory gating techniques (Moeller et al., 2003). The breath-hold technique is performed by the patient holds his breath during the scanning process. Good breath holding performed by patients will result in good image quality (Grand et al., 2012) [13]. Patients who are not cooperative so that they are unable to hold their breath will produce signals that become motion artifacts in the MRI images (Brown and Samelka, 2003) [7]. Meanwhilem the respiratory gating technique is a procedure for taking an image of an organ at a certain time during the patient's breath cycle. The position and duration of image capture at each breath cycle is determined by monitoring the patient's breath movements (AAPM, 2006). Respiratory gating causes the image capture could not to be carried out continuously so that the use of this technique takes longer, but results in better image quality than breath-hold technique (Kandpal et al., 2009 and AAPM 2006) [16].

In 1990 a new technique was developed in the process of filling the data matrix on MRI imaging. The data filling technique is known as PROPELLER (Periodically Rotated Overlapping Parallel Lines with Enhanced Reconstruction) (Elster, 2015) [11]. PROPELLER is a technique of filling the data matrix (k-space) radially by a number of parallel lines (blade coverage) of data obtained from the scanning process. PROPELLER produces excess data at the center of k-space. The same data on each coverage blade is used to correct other data so that data as a result of movement can be known. The differencesof data from each blade coverage are identified as inconsistencies within data which is interpreted as motion artifacts, so that the data can be reduced. The scaning time needed by using PROPELLER is influenced by blade coverage and Echo Train Length (ETL) values (McRobbie et al., 2006). According tothose problems a study on the optimization of abdominal MRI images will be carried out with the application of PROPELLER.

METHODS

The objective of this study was to examine the use of PROPELLER on abdominal MRI to reduce motion artifact, obtain optimal anatomical information and image quality with faster time scan. This study was conducted by applying PROPELLER on abdominal MRI examination with variations in blade coverage values of 50%, 75%, 100%, 125%, 150%, 175% and 200%. The images obtained were compared to the results of the examination by using the respiratory gating technique which is the standard protocol of abdominal MRI examination. Analysis was carried out on several parameters including anatomical information, Signal to Noise Ratio (SNR), Contrast to Noise Ratio (CNR), artifact and time scan. This was an experimental study with one group post test design. The sampling procedure was conducted by purposive sampling technique which means that the sampling is done based on the decision of the researcher, which in his opinion appears to represent the population (Budijanto, 2010). This study used eight types of treatments so that the researcherdetermined the number of samples to be used as many as 8 samples.

The stages of this studywere as follows

a. The samples were prepared for Abdimonal MRI examination
b. Abdominal MRI examination was performed with the use of respiratory gating
c. Abdominal MRI examination was performed by applying PROPELLER with a coverage of blade values of 50%, 75%, 100%, 125%, 150%, 175% and 200%.
d. The images produced were compared to the use of respiratory gating with the application of PROPELLER

e. Assessment included time scan, anatomical information, artifacts, SNR, and CNR.
f. Anatomical information and artifact were assessed by 3 radiologists.
g. Time scan, SNR, and CNR were assessed on MRI images generated on MRI console computer.
h. Thea author determined the blade coverage values that were able to reduce motion artifact, produce better anatomical information and image quality compared to the use of respiratory gating with shorter time scans.

Data analysis was performed statistically by the stages

a. Kappa test to assess the suitability of assessments from 3 observers.
b. Data normality test to determine the statistical test that will be used further.
c. Kruskal Wallis test to determine the effect of changes in blade coverage values on anatomical information, artifact, SNR, CNR and time scan.
d. Wilcoxon Test to compare the assessment on the use of respiratory gating and the application of PROPELLER.
e. Spearman test to determine the correlation between variables of time scan, anatomical information, artifacts, SNR, and CNR. This test is to prove that each out put variable is interrelated so that the time scan correlate to the image quality produced in each blade coverage.

RESULTS AND DISCUSSION

This study obtained information that changes in blade coverage values provided a significant difference in time scan with $p< 0,001$, anatomical information with $p< 0,001$, motion artifacts with $p< 0,00$, SNR with $p = 0,007$ and CNR with $p = 0,004$. Furthermore, the assessment of the use of respiratory gating compared to the application of PROPELLER showed the following results:

Table 1 Comparison of Assessment on the Use of Respiratory Gating with PROPELLER application

Time Scan				
NO	**Mean Respiratory Gating**	**PROPELLER Blade Covrerage**	**Mean**	***p* value**
1	4,33	50 %	1,73	0,011
2		70%	2,39	0,011
3		100%	3,25	0,035
4		125%	4,23	1,000
5		150%	4,75	0,778
6		175%	5,93	0,091
7		200%	7,09	0,011
InformasiAnatomi				
NO	**Mean Respiratory Gating**	**PROPELLER Blade Covrerage**	**Mean**	***p* value**
1	47,88	50 %	40,12	0,017
2		70%	47,37	0,719
3		100%	52,13	0,068
4		125%	54,00	0,020
5		150%	53,37	0,011
6		175%	54,25	0,021
7		200%	54,50	0,011

Artefak				
NO	**Mean Respiratory Gating**	**PROPELLER Blade Covrerage**	**Mean**	***p* value**
1	5,00	50 %	5,36	0,414
2		70%	4,50	0,459
3		100%	3,25	0,037
4		125%	3,00	0,023
5		150%	3,00	0,023
6		175%	3,00	0,023
7		200%	3,00	0,023

Signal to Noise Ratio (SNR)				
NO	**Mean Respiratory Gating**	**PROPELLER Blade Covrerage**	**Mean**	***p* value**
1	198,28	50 %	529,16	0,011
2		70%	490,82	0,011
3		100%	492,22	0,011
4		125%	553,58	0,011
5		150%	618,28	0,012
6		175%	638,25	0,011
7		200%	663,50	0,011
Contrast to Noise Ratio (CNR)				
NO	**Mean Respiratory Gating**	**PROPELLER Blade Covrerage**	**Mean**	***p* value**
1	124,83	50 %	284,88	0,011
2		70%	271,69	0,011
3		100%	280,98	0,011
4		125%	323,72	0,011
5		150%	351,25	0,011
6		175%	366,88	0,011
7		200%	371,68	0,011

To prove that interrelated variables are then spearman test with the following results:

Table 2 Variable Correlation Test Results

No	**Variabel**	**Waktu Scanning**	**InformasiAnatomi**	**Artefak**	**SNR**	**CNR**
1	Waktu Scanning	X	< 0,001	0,001	0.027	0.003
2	InformasiAnatomi	< 0,001	X	< 0,001	< 0,001	< 0,001
3	Artefak	< 0,001	< 0,001	X	< 0,001	< 0,001
4	SNR	0,027	< 0,001	< 0,001	X	< 0,001
5	CNR	0,003	< 0,001	< 0,001	< 0,001	X

It can be seen in the table that in the anatomical information assessment of 50% blade coverage had a mean value of 40,12 lower than the mean value on the use of respiratory gating of 47,88. Thus, the 50% blade coverage should not be used on Abdominal MRI examinations since it produced lower anatomical information than the standard protocol. Meanwhile in the SNR and CNR assessments, all variations of blade coverage yielded a greater and significantly different value than the use of respiratory gating. Therefore the SNR and CNR assessments did not provide limits on the use of blade coverage. The assessment of the use of 100% blade coverage values artifacts

showed the artifact values of 3,25 and 200% blade coverage values artifacts showed the artifact values of 3,00. The use of 100% - 200% blade coverage values is recommended because it produces lower artifacts compared to the use of respiratory gating. The selection of blade coverage that is able to reduce motion artifacts, produce optimal anatomical information and image quality should selected from blade coverage that is able to produce better images than the use of respiratory gating with the shortest time scan.

In the table it can be seen that the 200% blade coverage produced the highest mean of anatomical information, artifacts and anatomical information but it also required significantly higher time scan than the use of respiratory gating with p = 0.011. Meanwhile, the implementation of 125% -175% blade coverage values showed that there was no difference in time scan compared to the use of respiratory gating with a p values of 1.00 (125% blade coverage), 0.910 (150% blade coverage) and 0.778 (blade coverage 175%), respectively. The 100% blade coverage resulted in better anatomical information, artifact and image quality compared to the use of respiratory gating. Besides, the time scan required on a blade coverage of 100% of 3.25 minutes was significantly faster (p=0.035) than the use of respiratory gating of 4.33 minutes. Therefore, the application of PROPELLER with 100% blade coverage was able to reduce motion artifacts, produce the most optimal anatomical information and image quality in abdominal MRI examination with the shortest time scan. The Spearman test results also showed a correlation between variables of time scan, anatomical information, artifacts, SNR and CNR so that the use of 100% blade coverage with scanning time of 3.25 is related to the resulting image with p <0.05 in all tests between variables.

.

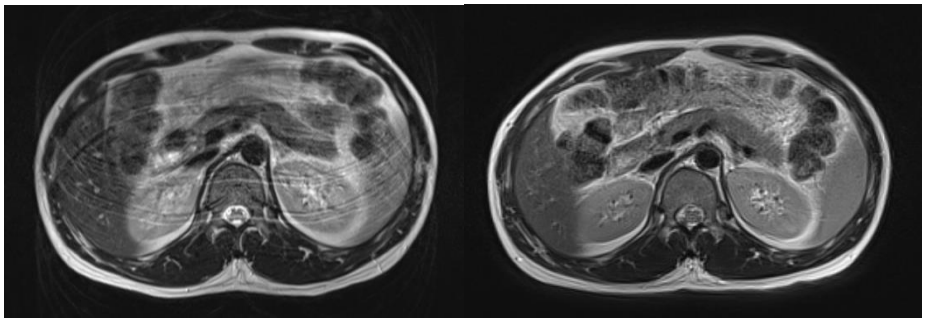

a. b.

Figure 1. a. Motion artifacts still presented in the use of respiratory gating b. Abdominal MRI image by using PROPELLER with 100% blade coverage

CONCLUSIONS

The application of PROPELLER with 100% blade coverage on Abdominal MRI was able to produce optimal images by reducing motion artifact so as to improve anatomical information and image quality with shorter time scan compared to the use of respiratory gating.

PROPELLER with 100% balde coverage could be used as an MRI abdominal examination protocol because it was able to produce an optimal image by reducing motion artifact so as to improve anatomical information and image quality.

Acknowledgments

The author would like to express special gratitude to Allah SWT for the completion of this study and publication. The author presents this study to all parties who have assisted and supported especially parents, wife and colleagues. Hopefully this study can benefit both the writer and the readers.

REFERENCES

[1]. Alkan O, Kızılkılıç O, Yıldırım T. Comparison of contrast-enhanced T1-weighted FLAIR with BLADE, and spin-echo T1-weighted sequences in intracranial MRI. Turkey Society of Radiology. 2009.

[2]. American Association of Physicists in Medicine. The Management of Respiratory Motion in Radiation Oncology. Report No. 91. 2006.

[3]. Bhuiya FA, Pitts SR, McCaig LF. Emergency Department Visits for Chest Pain and Abdominal Pain: United States at 1999–2008. U.S. Department Of Health And Human Services. 2010.
[4]. Bickley LS. Bate's Guide to Physical Examination and History Taking. Philadelphia: Lippincot Williams and Wilkin. 7, 2005, 318-19.
[5]. Boucher L, Rodrigue S, Lecomte R, at al. Respiratory Gating for 3-Dimensional PET of the Thorax: Feasibility and Initial Results. Sherbrooke: Research Center Universitaire de Sherbrooke. 2004.
[6]. Bourne R. Fundamentals of Digital Imaging in Medicine. New York: Springer.2010, 87-88.
[7]. Brown MA, Samelka RC. MRI Basic Principles and Applications. New Jersey: John Wiley and Sons.2003, 113-118.
[8]. Cartwright SL, Knudson MP. Evaluation of Acute Abdominal Pain in Adults. American Academy of Family Physicians. 7, 2008.
[9]. Dietrich Tobias J. Ulbrich Erika J, Zanetti Marco at al. PROPELLER Technique to Improve Image Quality of MRI of the Shoulder. AJR:197, 2011
[10]. Ehrnan RL, McNamara MT, Pallack M, at al. Magnetic Resonance Imaging with Respiratory Gating: Techniques and Advantages. American Journal of Rontgenology. 1984.
[11]. Elster AD. MRI and Parameters. London: Mosby. 2015, 210-11
[12]. Forbes Kirsten P.N., MD, Pipe James G, Bird C. Roger, at al. PROPELLER MRI: Clinical Testing of a Novel Technique for Quantification and Compensation of Head Motion. Journal of Magnetic Resonance Imaging 14, 2001, 215–222.
[13]. Grand DJ, Mayo-Smith WW, Woodfield CA. Practical Body MRI. Cambridge: Cambridge University Press.2012, 1-4.
[14]. Hirokawa Y, Isoda H, Maetani YS. MRI Artifact Reduction and Quality Improvement in the Upper Abdomen with PROPELLER and Prospective Acquisition Correction (PACE) Technique. American Journal of Rontgenology. 2008.
[15]. Kagan AR, Steckel RJ, Weiner M, et al. Radiologic Contributions to Cancer Management. American Journal of Rontgenology. 1987.
[16]. Kandpal H, Sharma R, Madhusudhan KS. Respiratory-Triggered Versus Breath-Hold Diffusion-Weighted MRI of Liver Lesions: Comparison of Image Quality and Apparent Diffusion Coefficient Values. American Journal of Rontgenology. 2008.
[17]. Lane BF, Vandermeer FQ, Rasim C. Comparison of Sagittal T2-Weighted BLADE and Fast Spin-Echo MRI of the Female Pelvis for Motion Artifact and Lesion Detection. American Journal of Rontgenology. 2011.
[18]. Low RN, Alzate GD, Shimakawa A. Motion Suppresion in MR Imaging of The Liver. American Journal of Rontgenology.1997.
[19]. McRobbie DW, Moore EA, Graves MJ. MRI from Picture to Proton. Cambridge: Cambridge University Press.2006, 167-191
[20]. Miller P, Parizel PM. Clinical MR Imaging A Practical Approach. Berlin. Springer.2011;1
[21]. Moeller TB, Reif E. MRI Paramaters and Positioning. New York: Thieme. 2003
[22]. Moeller TB, Reif E. Normal Findings in CT and MRI. New York: Thieme.2000, 131-132
[23]. Noone TC, Samelka RC, Chaney DM. Abdominal Imaging Studies: Comparion of Diagnostic Accuracies Resulting from Ultrasound, Computed Tomography and Magnetic Resonance Imaging in The Same Individual. Springer Science and Business Media. 2003
[24]. Nyberg E, Sandhu G.S, Jesberger .J, at al. Comparison of Brain MR Images at 1.5T Using BLADE and Rectilinear Techniques for Patients Who Move during Data Acquisition. American Journal of Neuroradiology. 2012
[25]. Patel K. Basic MRI: Physics. London. Evert J. Blink. 2007
[26]. Prasad PV. Magnetic Resonance Imaging: Methods and Biologic Application. Chicago: Humana Press.2006, 17
[27]. Reiser MF, Sammler W, Hricak D. Magnetic Resonance Tomography. Berlin. Springer.2008, 863
[28]. Ruan J, Victor DK. Marincek B. How Does MRI Work?An Introduction to the Physics and Function of Magnetic Resonance Imaging. Berlin. Springer.2001, 129
[29]. Tolba R, Shroll J, Kanu A, at al. The Epidemiology of Chronic Abdominal Pain. New York: Springer Science and Business Media. 2015

[30]. Westbrook C. MRI at Glance. Iowa: Blackweel Science. 2002, 64-72

How to cite this article: Fadli Felayani, Suryono Suryono and Suhartono. Optimization of abdominal MRI images with the application of PROPELLER. Study on the Application of PROPELLER on Abdominal MRI towards Anatomical Information, Motion Artifact and Image Quality. Int J of Allied Med Sci and Clin Res 2018; 6(4): 953-959.