ISSN: 2347-6567

International Journal of Allied Medical Sciences and Clinical Research (IJAMSCR)

IJAMSCR |Vol. 14 | Issue 4| Oct-Dec-2026

www.ijamscr.com

DOI : https://doi.org/10.61096/ijamscr.v14.iss4.2026.1600-1607

An Updated Review of Zollinger–Ellison Syndrome: Integrating Biochemical Diagnosis, Tumor Biology, and Contemporary Management

Senthil Kumar Chelladurai[1], Prema Rathinam[2], Aruna Moorthy[3], Ketrin Jenowa Baskar[4], Mohan Kaliyaperumal[5]

[(1,2,4,5)]Department of Pharmaceutics Sir Issac Newton College of Pharmacy, Nagapattinam, Tamil Nadu

[(3)]Department of Pharmacy Practice Sir Issac Newton College of Pharmacy, Nagapattinam, Tamil Nadu

Corresponding Author: **Dr. C. Senthil Kumar**
E-mail; nanosenthilkumar@gmail.com

Published on:

08.10.2026

Published by:

Futuristic Publications

2026| All rights reserved.

Creative Commons Attribution 4.0 International License.

Abstract: Zollinger–Ellison syndrome (ZES) is a rare endocrine disorder caused by gastrin-secreting neuro endocrine tumors (gastrinomas) that result in excessive gastric acid production, leading to severe peptic ulcer disease, gastroesophageal reflux, chronic diarrhea, and malabsorption, which often delay diagnosis and complicate management. ZES occurs either sporadically or in association with multiple endocrine neoplasia type 1 (MEN1), further increasing diagnostic and therapeutic challenges due to overlapping clinical, biochemical, and pathological features. This literature review compiles and analyzes current evidence on the diagnostic criteria, patho morphological characteristics, biochemical markers, and treatment strategies for ZES, highlighting the roles of fasting serum gastrin levels, gastric acid secretion assessment, advanced imaging techniques, and histo pathological evaluation in achieving accurate diagnosis. Contemporary management approaches, including long-term proton pump inhibitor therapy, surgical intervention, and emerging targeted therapies, are discussed in relation to disease control and patient outcomes. This review uniquely integrates recent advances in diagnostic algorithms and molecular insights into gastrinoma biology with evolving therapeutic strategies, offering a concise yet comprehensive framework for early diagnosis and individualized management of *ZES*. By synthesizing updated multidisciplinary knowledge into a single narrative, this review aims to enhance clinical awareness, minimize diagnostic delays, and improve prognostic outcomes for patients with this rare but clinically significant syndrome.

Keywords: Zollinger–Ellison syndrome; gastrinoma; hypergastrinemia; neuro endocrine tumors; multiple endocrine neoplasia type 1; diagnosis; management.

ZOLLINGER–ELLISON SYNDROME: WHEN GASTRIN GOES ROGUE

Zollinger–Ellison syndrome (ZES) is a rare endocrinopathy caused by gastrin-producing neuroendocrine tumors (gastrinomas) that typically occur in the pancreas or duodenum, leading to excessive gastrin release and profound gastric acid hypersecretion. The resulting hyperchlorhydria drives refractory and recurrent peptic ulcer disease, severe gastroesophageal reflux, and often chronic secretory diarrhea, with some patients presenting initially with diarrhea rather than ulcer symptoms[1,2]. Diagnosis should be suspected in patients with refractory acid-related symptoms, unusual ulcer locations, or ulcers that recur despite standard therapy and is confirmed by markedly elevated fasting gastrin levels (often >1000 pg/mL) with low gastric pH. Localization of gastrinomas is commonly accomplished using endoscopic ultrasound and

somatostatin receptor imaging. Treatment focuses on controlling gastric acid hypersecretion—primarily with high-dose proton pump inhibitors—and on surgical resection of localized tumors when feasible. Despite improved understanding and advances in diagnostic modalities, ZES remains frequently under-recognized due to its rarity and symptom overlap with more common gastrointestinal disorders. [3,4]

AN UNCOMMON CULPRIT BEHIND COMMON SYMPTOMS

Zollinger–Ellison syndrome (ZES) is a rare disorder with an estimated incidence of 0.5 to 2 cases per million individuals annually. The condition results from gastrin-secreting neuroendocrine tumors, known as gastrinomas, which are most frequently located in the duodenum or pancreas, particularly within the gastrinoma triangle[5,6]. Recent studies suggest that duodenal gastrinomas are more common than pancreatic gastrinomas, although they are often small and difficult to detect using conventional imaging modalities. Approximately 60% to 80% of gastrinomas demonstrate malignant potential, with liver metastases being the most common site of spread. Additionally, 20% to 25% of ZES cases are associated with multiple endocrine neoplasia type 1 (MEN1), an inherited disorder characterized by endocrine tumors involving the parathyroid glands, pituitary gland, and pancreas[7]. The presence of MEN1 is associated with multifocal tumors, earlier onset of disease, and distinct management considerations. Despite its low prevalence, ZES carries significant morbidity if unrecognized, highlighting the importance of awareness among clinicians managing refractory gastrointestinal disease. [8,9]

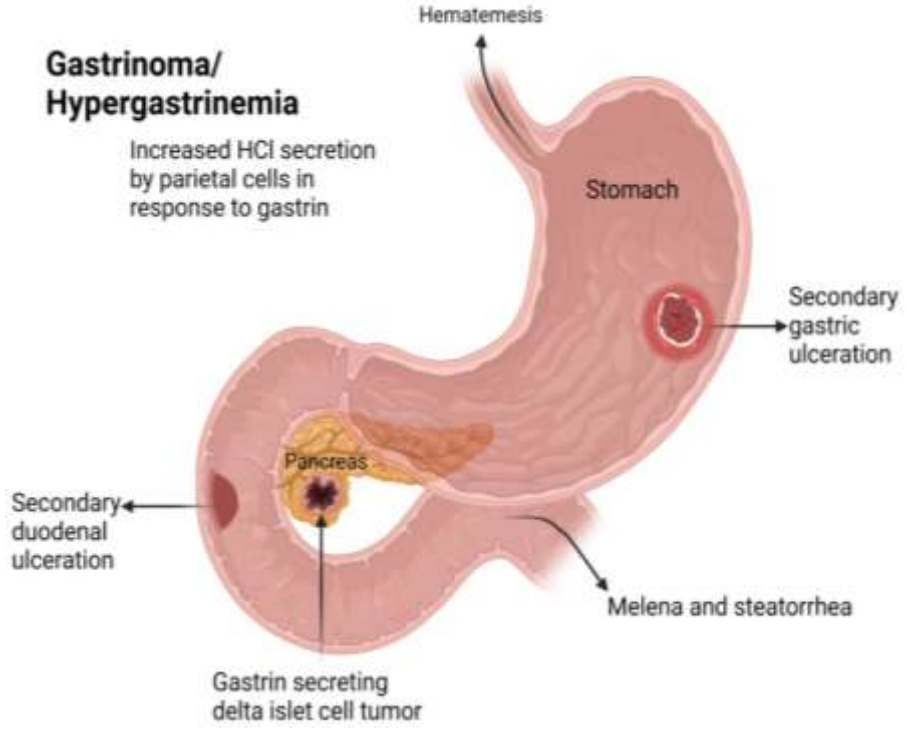

Fig 1: Gastrointestinal Neuroendocrine Tumors
(https://www.ncbi.nlm.nih.gov/books/NBK279162)

MOLECULAR BASIS OF GASTRINOMA

Gastrinomas are well-differentiated neuro endocrine tumors characterized by autonomous gastrin secretion. Their molecular development differs from that of conventional gastrointestinal carcinomas, as frequent mutations in classical oncogenes such as KRAS and tumor suppressors such as TP53 are uncommon in well-differentiated tumors.

A major molecular association is inactivation of the MEN1 gene, which encodes the tumor-suppressor protein menin. In MEN1-associated disease, loss of the remaining functional MEN1 allele can promote clonal expansion of gastrin-producing cells. These tumors are commonly multiple, small, and located in the duodenal submucosa. [10]

At the signaling level, excessive gastrin activates the cholecystokinin-2 (CCK2) receptor, promoting intracellular pathways involved in cell proliferation and survival. Gastrin-related signaling can

interact with MAPK, PI3K/AKT, and EGFR-associated pathways, creating a biological environment that supports tumor growth. [11]

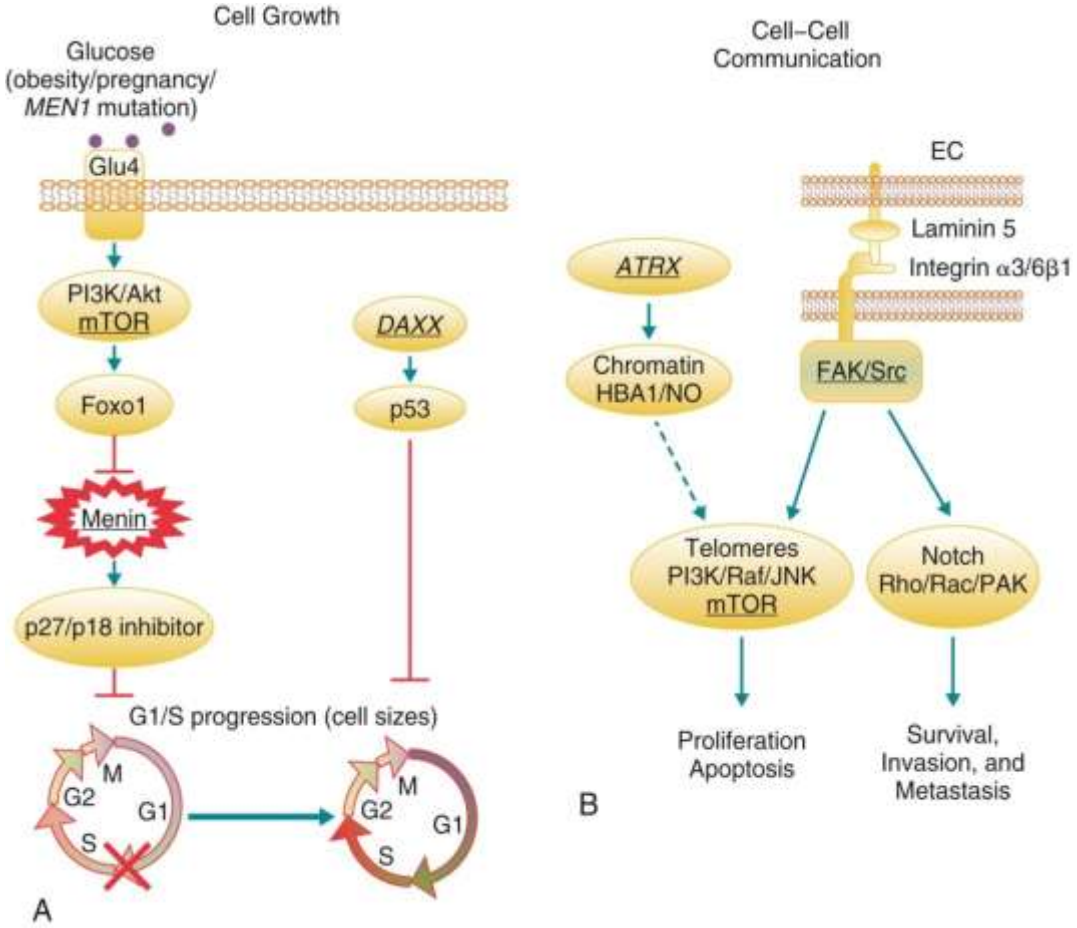

Fig 2: Pancreatic Neuroendocrine Tumors:Molecular Mechanisms And Therapeutic Strategies (https://clinicalpub.com/endocrine-pancreas)

Recent molecular studies also indicate involvement of the mTOR pathway, DNA-repair mechanisms, chromatin remodeling, and telomere-maintenance pathways, including alterations involving DAXX and ATRX. These changes may contribute to tumor progression and metastatic behavior.

Overall, gastrinoma development can be viewed as a multistep process in which tumor-suppressor dysfunction, particularly MEN1/menin loss, combines with dysregulated growth-signaling pathways and persistent gastrin stimulation. This molecular framework helps explain the distinct biology of sporadic and MEN1-associated gastrinomas and may provide opportunities for future targeted therapies.[11]

THE ACID STORM: PATHOPHYSIOLOGIC PATHWAYS OF HYPERSECRETION

The fundamental patho physiological mechanism of Zollinger–Ellison syndrome is autonomous gastrin secretion from gastrinomas, leading to persistent stimulation of gastric parietal cells and excessive gastric acid production. Sustained hypergastrinemia markedly increases basal and stimulated acid output, overwhelming the protective mechanisms of the gastric and intestinal mucosa. [2,3,6]

The resulting hyperchlorhydria causes recurrent and refractory peptic ulcer disease, often involving atypical or distal sites such as the jejunum. Excess acid entering the small intestine also inactivates pancreatic digestive enzymes and damages the intestinal mucosa, impairing fat digestion and nutrient absorption. These effects contribute to chronic secretory diarrhea, steatorrhea, and weight loss, which may occur independently of ulcer disease.

Furthermore, prolonged exposure of the esophageal mucosa to gastric acid predisposes patients to severe gastroesophageal reflux disease, erosive esophagitis, and complications such as strictures or Barrett esophagus. Together, these mechanisms account for the severity and persistence of

gastrointestinal symptoms in ZES and underscore the need for aggressive acid suppression and early intervention. [12]

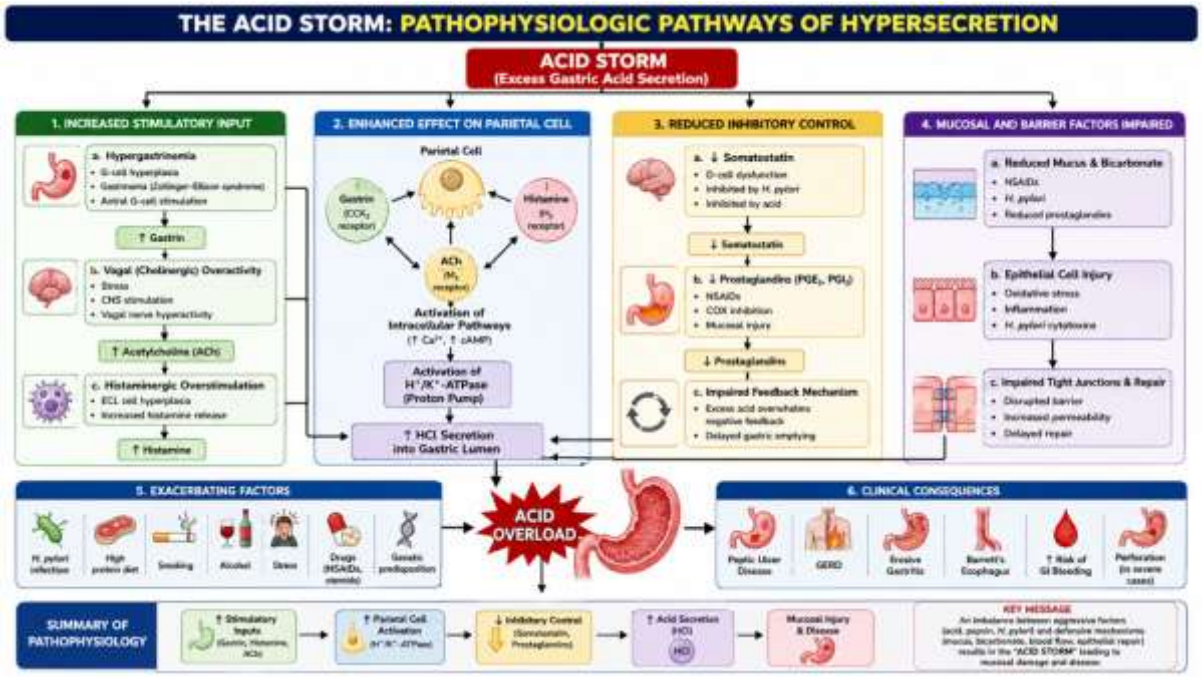

Fig 3: Pathophysiologic Pathways of Gastric Acid Hypersecretion ("The Acid Storm") (https://pubmed.ncbi.nlm.nih.gov/18474247)

SPORADIC VS MEN1-ASSOCIATED ZES

Zollinger–Ellison syndrome (ZES) occurs either as sporadic disease or in association with multiple endocrine neoplasia type 1 (MEN1). Most gastrinomas are sporadic, while approximately 20–25% occur in patients with MEN1.Sporadic ZES generally presents with a single gastrinoma, most commonly arising in the duodenum. These tumors are often larger and more likely to require definitive tumor-directed treatment. After appropriate localization and staging, surgical resection is generally considered when feasible. In contrast, MEN1-associated ZES results from an inherited MEN1 gene defect involving loss of the tumor-suppressor protein menin. Patients frequently develop multiple small duodenal gastrinomas, together with other MEN1 manifestations, particularly primary hyperparathyroidism and pituitary tumors. Because of tumor multiplicity, complete surgical cure is more difficult and the role of surgery is therefore more selective.

FEATURE	SPORADIC ZES	MEN1-ASSOCIATED ZES
Genetic background	Usually no inherited MEN1 syndrome	Germ line*MEN1* mutation
Tumor pattern	Usually solitary	Often multiple and small
Common site	Duodenum	Predominantly duodenum
Other endocrine tumors	Usually absent	Common
Surgical approach	Resection often considered	More selective because of multiplicity
Family screening	Generally not required unless indicated	Genetic counseling and family evaluation important

Table 1: Sporadic ZES Vs Men1-Associated ZES

Recent comparative evidence suggests that MEN1-associated patients tend to be younger and have smaller primary gastrinomas, with generally more favorable survival outcomes than sporadic ZES, although individual prognosis is stronglyinfluenced by tumor grade and metastatic disease. In summary, distinguishing sporadic from MEN1-associated ZES is clinically important because the underlying biology, tumor distribution, associated endocrine abnormalities, surgical strategy, and long-term surveillance differ between the two forms. [13,14]

BEYOND PEPTIC ULCERS: THE DIVERSE CLINICAL FACE OF ZES

The clinical manifestations of Zollinger–Ellison syndrome are heterogeneous and often mimic more common gastrointestinal disorders, contributing to delayed diagnosis. Refractory or recurrent peptic ulcer disease is the most frequent presentation, particularly ulcers that are multiple, large, distal, or resistant to standard proton pump inhibitor therapy. Severe gastroesophageal reflux disease is also common and may present with persistent heartburn, regurgitation, or esophagitis despite treatment. Chronic diarrhea is a hallmark feature and may be the initial presenting symptom in up to one-third of patients. This diarrhea is typically secretory and may be accompanied by electrolyte abnormalities, dehydration, and weight loss. Gastrointestinal bleeding, abdominal pain, nausea, and vomiting are also reported, particularly in advanced disease. Complications such as perforation, obstruction, and strictures may occur if the condition remains untreated. Because these symptoms overlap with Helicobacter pylori infection, non-steroidal anti-inflammatory drug–induced ulcers, and functional gastrointestinal disorders, a high index of suspicion is required to identify ZES in patients with atypical or treatment-resistant disease. [15]

BIOCHEMICAL CLUES AND IMAGING BREAKTHROUGHS

The diagnosis of Zollinger–Ellison syndrome relies on identifying inappropriate hypergastrinemia in the presence of gastric acid hypersecretion. Measurement of fasting serum gastrin remains the cornerstone of diagnosis, with levels exceeding 1000 pg/mL in conjunction with a gastric pH $\leq$2 considered diagnostic. In patients with intermediate gastrin elevations, particularly those receiving proton pump inhibitors, additional testing is required. The secretin stimulation test is the most widely used confirmatory test, exploiting the paradoxical rise in gastrin secretion seen in gastrinomas. Once biochemical confirmation is achieved, accurate tumor localization is critical for staging and management. Imaging modalities have evolved significantly, with endoscopic ultrasound offering high sensitivity for detecting small pancreatic and duodenal lesions. Cross-sectional imaging using contrast-enhanced computed tomography and magnetic resonance imaging assists in identifying metastatic disease. More recently, somatostatin receptor–based imaging, particularly gallium-68 DOTATATE positron emission tomography, has emerged as a highly sensitive and specific modality for detecting both primary gastrinomas and distant metastases, representing a major advance in ZES evaluation. [16]

FROM SUSPICION TO CERTAINTY: NAVIGATING DIAGNOSTIC CHALLENGES

Diagnosing Zollinger–Ellison syndrome is often complicated by conditions that cause secondary hypergastrinemia, leading to potential diagnostic pitfalls. Chronic proton pump inhibitor therapy is the most common confounder, as it induces hypergastrinemia through acid suppression. Other conditions such as atrophic gastritis, pernicious anemia, Helicobacter pylori infection, renal insufficiency, and gastric outlet obstruction may also elevate serum gastrin levels. Failure to assess gastric pH alongside gastrin levels can result in misdiagnosis. Additionally, small duodenal gastrinomas may evade detection on conventional imaging, further complicating diagnosis. MEN1-associated ZES presents additional challenges due to multifocal tumors and coexisting endocrine abnormalities that may obscure clinical interpretation. Misattribution of symptoms to more common disorders such as refractory gastroesophageal reflux disease or irritable bowel syndrome frequently delays diagnosis. These challenges underscore the importance of systematic biochemical evaluation, careful medication review, and use of advanced imaging techniques to achieve diagnostic certainty. [16]

THERAPEUTIC STRATEGIES, OUTCOMES, AND ONGOING CHALLENGES IN ZOLLINGER–ELLISON SYNDROME

The management of Zollinger–Ellison syndrome (ZES) requires a multifaceted approach aimed at controlling gastric acid hypersecretion, addressing tumor burden, and minimizing long-term complications. The cornerstone of medical therapy is aggressive acid suppression using high-dose proton pump inhibitors (PPIs), which have dramatically improved symptom control and reduced ulcer-related morbidity. Agents such as omeprazole, pantoprazole, and esomeprazole effectively suppress both basal and stimulated acid

secretion and are generally well tolerated, although long-term therapy necessitates monitoring for potential adverse effects, including micronutrient deficiencies and bone disease. Somatostatin analogs, including octreotide and lanreotide, provide additional benefit by reducing gastrin secretion and controlling tumor-related symptoms, particularly in patients with metastatic disease or those who are not surgical candidates. Surgical resection remains the only potentially curative option and is recommended for patients with localized sporadic gastrinomas; however, its role in MEN1-associated ZES is more controversial due to tumor multiplicity and high recurrence rates, often favoring selective surgery or active surveillance. In advanced disease, particularly in the presence of liver metastases, management focuses on symptom control, tumor growth suppression, and quality-of-life preservation using somatostatin analogs, targeted therapies, peptide receptor radionuclide therapy, and liver-directed interventions. Prognosis has improved significantly with modern therapy, with excellent long-term survival in localized disease, while outcomes remain less favorable in patients with metastatic or MEN1-associated disease, necessitating lifelong biochemical and radiologic surveillance. Despite these advances, ZES continues to pose diagnostic challenges due to its rarity, nonspecific clinical features, and masking effects of widespread PPI use, often resulting in delayed recognition and preventable complications. [17,18,19]

CURRENT KNOWLEDGE GAPS AND RESEARCH PRIORITIES

Despite major advances in the diagnosis and treatment of Zollinger–Ellison syndrome (ZES), several important uncertainties remain. The rarity of gastrinoma has resulted in limited prospective studies, and many treatment recommendations are based on retrospective studies, expert consensus, or evidence from broader neuro endocrine tumor populations.

Key research priorities include improving biochemical diagnosis, particularly the development of reliable gastrin-based biomarkers and safer diagnostic strategies that reduce dependence on withdrawal of proton-pump inhibitors. Better methods are also needed to distinguish true gastrinoma-associated hypergastrinemia from common secondary causes.

Another major gap is the molecular understanding of gastrinoma progression. Further studies are required to clarify how MEN1 alterations, signaling pathways, and other molecular changes influence tumor growth, metastasis, and treatment response. Molecular markers that can predict aggressive behavior could improve individualized management.

Tumor localization and surveillance also require refinement. Small duodenal gastrinomas, particularly in MEN1-associated ZES, may remain difficult to detect with conventional imaging. Research should determine the optimal combination and timing of cross-sectional imaging, endoscopic ultrasound, and somatostatin-receptor-based imaging.

Finally, there is a need for gastrinoma-specific clinical trials evaluating surgery, somatostatin analogues, targeted therapies, peptide receptor radionuclide therapy (PRRT), and treatments for metastatic disease. Evidence specifically generated in gastrinoma populations remains limited, making personalized treatment selection an important future research direction. [20,21]

FUTURE PERSPECTIVES

In summary, future research should focus on earlier and more accurate diagnosis, molecular risk stratification, improved tumor localization, standardized surveillance, and prospective evaluation of personalized therapies. These advances could help move ZES management from predominantly consensus-based practice toward evidence-driven precision medicine.

Advances in somatostatin-receptor imaging and molecular profiling may allow more accurate localization of small gastrinomas and better identification of tumors with aggressive behavior. Further research into MEN1/menin abnormalities and other molecular pathways could provide biomarkers for prognosis and treatment selection.

For advanced disease, prospective studies specifically involving gastrinoma are needed to determine the optimal sequence and combination of somatostatin analogues, targeted therapies, peptide receptor radionuclide therapy (PRRT), chemotherapy, and liver-directed approaches. Current evidence for several of these strategies remains limited because gastrinoma-specific trials are uncommon.

Ultimately, the future management of ZES is likely to move toward precision medicine, integrating biochemical markers, functional imaging, tumor genetics, and clinical characteristics to select individualized therapies. Greater collaboration through specialized multidisciplinary neuro endocrine tumor centers and prospective international studies will be essential to generate stronger evidence for this rare disorder.[22,23]

CONCLUSION

Zollinger–Ellison syndrome remains a complex and often under recognized disorder despite major advances in diagnostic and therapeutic strategies. Effective acid suppression with proton pump inhibitors has transformed disease outcomes, while surgical and targeted oncologic interventions offer meaningful benefit in selected patients. Nonetheless, challenges persist in early diagnosis, management of MEN1-associated disease, and treatment of metastatic gastrinomas. Improved clinician awareness, judicious use of diagnostic algorithms, and a multidisciplinary approach are essential to optimize long-term outcomes and quality of life in patients with ZES. [24]

REFERENCES

1. Zollinger RM, Ellison EH. Primary peptic ulcerations of the jejunum associated with islet cell tumors of the pancreas. Ann Surg. 1955;142:709-723.
2. Wolfe MM, Jensen RT. Zollinger-Ellison syndrome—current concepts in diagnosis and management. N Engl J Med. 1987;317:1200-1209. doi:10.1056/NEJM198711053171907.
3. Ito T, Igarashi H, Jensen RT. Zollinger-Ellison syndrome: recent advances and controversies. Curr Opin Gastroenterol. 2013;29(6):650-661. doi:10.1097/MOG.0b013e328365efb1.
4. Metz DC, Cadiot G, Poitras P, Ito T, Jensen RT. Diagnosis of Zollinger-Ellison syndrome in the era of PPIs, faulty gastrin assays, sensitive imaging and limited access to acid secretory testing. Int J Endocr Oncol. 2017;4(4):167-185. doi:10.2217/ije-2017-0018.
5. Rossi RE, Elvevi A, Citterio D, et al. Gastrinoma and Zollinger-Ellison syndrome: a roadmap for the management between new and old therapies. World J Gastroenterol. 2021;27(35):5890-5907. doi:10.3748/wjg.v27.i35.5890.
6. Jensen RT, Niederle B, Mitry E, Ramage JK, Steinmüller T, Lewington V, et al. Gastrinoma (duodenal and pancreatic). Neuroendocrinology. 2006;84(3):173-182. doi:10.1159/000098009.
7. Thom AK, Norton JA, Axiotis CA, Jensen RT. Location, incidence, and malignant potential of duodenal gastrinomas. Surgery. 1991;110(6):1086-1091.
8. Pipeleers-Marichal M, Somers G, Willems G, Fiasse R, Vereerstraeten P, Gepts W, et al. Gastrinomas in the duodenums of patients with multiple endocrine neoplasia type 1 and the Zollinger-Ellison syndrome. N Engl J Med. 1990;322(11):723-727. doi:10.1056/NEJM199003153221103.
9. Thakker RV, Newey PJ, Walls GV, Bilezikian J, Dralle H, Ebeling PR, et al. Clinical practice guidelines for multiple endocrine neoplasia type 1 (MEN1). J Clin Endocrinol Metab. 2012;97(9):2990-3011. doi:10.1210/jc.2012-1230.
10. Jiao Y, Shi C, Edil BH, de Wilde RF, Klimstra DS, Maitra A, et al. DAXX/ATRX, MEN1 and mTOR pathway genes are frequently altered in pancreatic neuroendocrine tumors. Science. 2011;331(6021):1199-1203. doi:10.1126/science.1200609.
11. Scarpa A, Chang DK, Nones K, Corbo V, Patch AM, Bailey P, et al. Whole-genome landscape of pancreatic neuroendocrine tumours. Nature. 2017;543:65-71. doi:10.1038/nature21063.
12. Heaphy CM, de Wilde RF, Jiao Y, Klein AP, Edil BH, Shi C, et al. Altered telomeres in tumors with ATRX and DAXX mutations. Science. 2011;333(6041):425. doi:10.1126/science.1207313.
13. Yu F, Venzon DJ, Serrano J, Goebel SU, Doppman JL, Gibril F, et al. Prospective study of the clinical course, prognostic factors, causes of death, and survival in patients with long-standing Zollinger-Ellison syndrome. J Clin Oncol. 1999;17(2):615-630. doi:10.1200/JCO.1999.17.2.615.
14. Norton JA, Alexander HR, Fraker DL, Venzon DJ, Gibril F, Jensen RT. Comparison of surgical results in patients with advanced and limited disease with multiple endocrine neoplasia type 1 and Zollinger-Ellison syndrome. Ann Surg. 2001;234(4):495-505. doi:10.1097/00000658-200110000-00009.
15. Mendelson AH, Donowitz M. Catching the zebra: clinical pearls and pitfalls for the successful diagnosis of Zollinger-Ellison syndrome. Dig Dis Sci. 2017;62:2258-2265. doi:10.1007/s10620-017-4695-7.
16. Ito T, Cadiot G, Jensen RT. Diagnosis of Zollinger-Ellison syndrome: increasingly difficult. World J Gastroenterol. 2012;18(39):5495-5503. doi:10.3748/wjg.v18.i39.5495.

17. Epelboym I, Mazeh H. Zollinger-Ellison syndrome: classical considerations and current controversies. Oncologist. 2014;19(1):44-50. doi:10.1634/theoncologist.2013-0369.
18. Fraker DL, Norton JA, Alexander HR, Venzon DJ, Jensen RT. Surgery in Zollinger-Ellison syndrome alters the natural history of gastrinoma. Ann Surg. 1994;220(3):320-330. doi:10.1097/00000658-199409000-00008.
19. Shao QQ, Zhao BB, Dong LB, Cao HT, Wang WB. Surgical management of Zollinger-Ellison syndrome: classical considerations and current controversies. World J Gastroenterol. 2019;25(32):4673-4681. doi:10.3748/wjg.v25.i32.4673.
20. Rinke A, Müller HH, Schade-Brittinger C, Klose KJ, Barth P, Wied M, et al. Placebo-controlled, double-blind, prospective randomized study on the effect of octreotide LAR in the control of tumor growth in patients with metastatic neuroendocrine midgut tumors: a report from the PROMID Study Group. J Clin Oncol. 2009;27(28):4656-4663. doi:10.1200/JCO.2009.22.8510.
21. Caplin ME, Pavel M, Ćwikła JB, Phan AT, Raderer M, Sedláčková E, et al. Lanreotide in metastatic enteropancreatic neuroendocrine tumors. N Engl J Med. 2014;371(3):224-233. doi:10.1056/NEJMoa1316158.
22. Strosberg J, El-Haddad G, Wolin E, Hendifar A, Yao J, Chasen B, et al. Phase 3 trial of 177Lu-Dotatate for midgut neuroendocrine tumors. N Engl J Med. 2017;376(2):125-135. doi:10.1056/NEJMoa1607427.
23. Yao JC, Shah MH, Ito T, Lombard-Bohas C, Wolin EM, Van Cutsem E, et al. Everolimus for advanced pancreatic neuroendocrine tumors. N Engl J Med. 2011;364(6):514-523. doi:10.1056/NEJMoa1009290.
24. Raymond E, Dahan L, Raoul JL, Bang YJ, Borbath I, Lombard-Bohas C, et al. Sunitinib malate for the treatment of pancreatic neuroendocrine tumors. N Engl J Med. 2011;364(6):501-513. doi:10.1056/NEJMoa1003825.