International Journal of Allied Medical Sciences and Clinical Research (IJAMSCR)

IJAMSCR |Vol.14 | Issue 4 | Oct - Dec -2025

www.ijamscr.com

ISSN: 2347-6567

DOI : https://doi.org/10.61096/ijpar.v14.iss4.2025.706-710

Research

CASE STUDY: CERVICAL FIBROID

Chandana Dayaka,[1*] Mekla Anusha[2], Mohemediya Afreen Sultana[1], Nusi Abhinaya[1],

[1]Pharm D, 5th year, [2]Assistant Professor

Department of pharmacy practice, Malla Reddy College of Pharmacy.

[*]Author for Correspondence: Chandana Dayaka
Email: chandudayaka@gmail.com

Published on:29 Oct 2025

Published by:
Futuristic Publications

2025| All rights reserved.

Creative Commons Attribution 4.0 International License.

Abstract

A 45-year-old woman presented with heavy menstrual bleeding, lower abdominal pain, and urinary frequency for six months. Examination and ultrasound revealed a 6 × 5 cm cervical fibroid. Laboratory tests showed mild anemia with normal thyroid and urine findings. The patient was treated with iron, folic acid, NSAIDs, and a GnRH agonist for preoperative stabilization, followed by total abdominal hysterectomy. Histopathology confirmed benign leiomyoma. Cervical fibroids are rare but can cause significant pressure and bleeding symptoms. Early diagnosis and individualized management ensure good outcomes.

Keywords: Menstrual Bleeding, Abdominal Hysterectomy, Benign Leiomyoma, Cervical Fibroids.

INTRODUCTION

Uterine fibroids, also known as leiomyomas or myomas, are benign (non-cancerous) tumors that develop from the smooth muscle tissue of the uterus. They are one of the most common gynecological conditions affecting women, particularly those between the ages of 30 and 50 years. The exact cause of fibroid development is not fully understood, but hormonal factors, especially estrogen and progesterone, play a significant role in their growth.

TYPES OF UTERINE FIBROIDS

Causes severe pain due to torsion or degeneration	**Location**	**Clinical features**
Causes severe pain due to torsion or degeneration	Within the muscular wall (myometrium) of the uterus	Causes heavy menstrual bleeding, pelvic pain, and pressure symptoms
Causes severe pain due to torsion or degeneration	Beneath the inner lining (endometrium) of the uterus	Causes heavy menstrual bleeding, infertility, and miscarriage
Causes severe pain due to torsion or degeneration	Beneath the outer layer (serosa) of the uterus	Causes pelvic pressure, urinary frequency, and back pain
Causes severe pain due to torsion or degeneration	Attached to the uterine wall by a stalk (either submucosal or subserosal)	Causes severe pain due to torsion or degeneration
Causes severe pain due to torsion or degeneration	In the cervix (lower part of uterus)	May cause difficulty in labor, urinary retention, or discharge

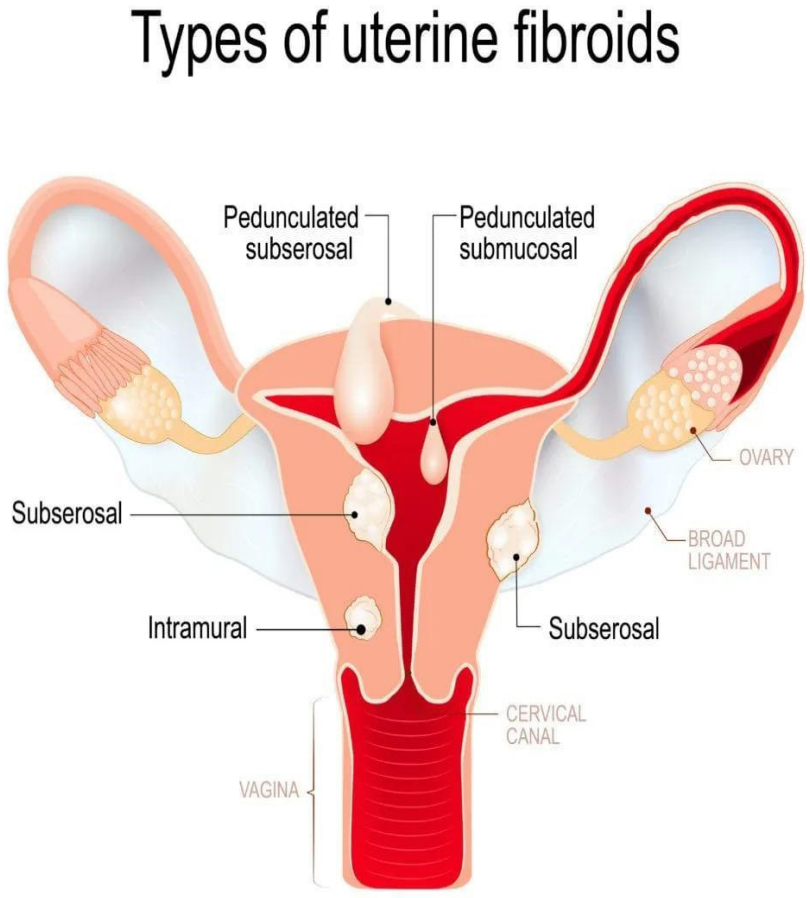

CASE PRESENTATION

A 45-year-old female (G3P2) presented with lower abdominal pain, heavy menstrual bleeding, and urinary frequency for six months. Menstrual flow has gradually increased, lasting 8–10 days with clots. She also reports pelvic heaviness and dull aching pain.

History:

Menstrual: Menarche at 13 years; previously regular, now heavy and prolonged.

Obstetric: Two full-term normal deliveries, one spontaneous abortion.

General Examination:

Moderately built and nourished; mild pallor present; vitals stable.

Investigation Findings

- CBP (Complete Blood Picture) Hemoglobin – 9.8 g/dL (mild anemia), WBC – normal, Platelets – normal
- Ultrasound Pelvis Well-defined hypoechoic mass arising from cervical region (6 × 5 cm), consistent with cervical fibroid

Abdominal Examination:

A firm, non-tender mass palpable in the lower abdomen, corresponding to about a 12-week-size uterus.

Per Speculum Examination:

Cervix enlarged and firm; no erosion or abnormal discharge.

Per Vaginal Examination:

A firm, globular, non-tender mass felt arising from the cervix, pushing the uterus upwards; uterus normal in size and mobile.

TREATMENT PLAN

Drug Name	Dose	Route	Frequency	Action
Ferrous sulfate	325 mg (equivalent to 65 mg elemental iron)	Oral	Once daily after meals	Corrects iron deficiency anemia caused by chronic blood loss.
Folic acid	5mg	Oral	Once daily	Helps in red blood cell formation and enhances the effect of iron therapy.

NSAID (Mefenamic acid)	500mg	Oral	3 times daily during menses	Reduces pain, inflammation, and menstrual blood loss by inhibiting prostaglandin synthesis.
Tranexamic acid	500mg	Oral	3 times daily during heavy bleeding	Antifibrinolytic – reduces heavy menstrual bleeding by stabilizing blood clots.
GnRH agonist (Leuprolide acetate)	3.75mg	Intramuscular (IM) injection	Once every 4 weeks for 3 months (preoperative)	Suppresses ovarian hormone production → reduces estrogen and progesterone, leading to shrinkage of fibroid size.
Analgesic (Paracetamol)	650mg	Oral	Every 6 hours as needed	Provides pain relief postoperatively.
Multivitamin supplement	1 tablet	Oral	Once daily	Supports recovery and general health post-surgery.

Surgical Management

After optimization and counseling, Total Abdominal Hysterectomy was performed since the patient had completed childbearing and experienced pressure symptoms.

Postoperative recovery was smooth.

Histopathology: Confirmed benign leiomyoma of cervical origin.

DISCUSSION

Cervical fibroids are rare (≈5% of all uterine fibroids) and may produce pressure-related symptoms such as urinary frequency, retention, or constipation due to their anatomical location.

Diagnosis relies on clinical examination and imaging (USG or MRI).

Treatment depends on age, fertility desire, and severity of symptoms. Hysterectomy remains the definitive treatment for perimenopausal women with symptomatic fibroids.

CONCLUSION

This case emphasizes the importance of a thorough clinical and laboratory evaluation in women with abnormal uterine bleeding and pelvic masses. In this 45-year-old woman, surgical management led to complete relief of symptoms and improvement in quality of life.

REFERENCES

1. Buttram VC Jr, Reiter RC. Uterine leiomyomata: etiology, symptomatology, and management. Fertil Steril. 1981;36(4):433–445.
2. Bulun SE. Uterine fibroids. N Engl J Med. 2013;369:1344–1355.
3. Stewart EA. Uterine fibroids. Lancet. 2001;357:293–298.

4. Munro MG, Critchley HO, Broder MS, Fraser IS. FIGO classification system (PALM-COEIN) for causes of abnormal uterine bleeding in non-pregnant women of reproductive age. Int J Gynaecol Obstet. 2011;113(1):1–7.
5. Marret H, Chapron C, Mignot TM, et al. Cervical leiomyomas: clinical characteristics and surgical management. J Gynecol Obstet Biol Reprod (Paris). 2003;32(7):628–634.
6. Parker WH. Uterine myomas: management. Obstet Gynecol. 2007;110(2 Pt 1):396–406.
7. American College of Obstetricians and Gynecologists (ACOG). Practice Bulletin No. 228: Management of Uterine Leiomyomas. Obstet Gynecol. 2021;137:e100–e115.