International Journal of Allied Medical Sciences and Clinical Research (IJAMSCR)

IJPAR |Vol.14 | Issue 4 | Oct - Dec -2025

www.ijamscr.com

DOI : https://doi.org/10.61096/ijpar.v14.iss4.2025.711-713

ISSN: 2347-6567

Research

OVARIAN FIBROMA/THECOMA

B. Mahima[1*], Mekala Anusha[2], Ch. Niharika[2], P. Pravalika[2], Billa Abhinav[2]

[1,2]Malla Reddy College of Pharmacy, Hyderabad, Telangana.

[*]Author for Correspondence: B. Mahima
Email:mahimavaiduryaboini@gmail.com

Published on:

Published by:
Futuristic Publications

2025| All rights reserved.

Creative Commons Attribution 4.0 International License.

Abstract

Ovarian fibroma/thecoma represents a group of benign sex cord-stromal tumors of the ovary. These tumors are often asymptomatic but can present with abdominal pain, distension, or a palpable mass. A [age]-year-old female presented with complaints of abdominal discomfort and distension at [hospital name]. Following clinical and radiological evaluation, she was diagnosed with ovarian fibroma/thecoma. The patient underwent surgical management with a favorable postoperative outcome.

Keywords: Ovarian Fibroma, Thecoma, Benign Ovarian Tumor, Surgery, Case Report.

INTRODUCTION

Ovarian fibroma and thecoma are benign stromal tumors derived from the sex cord-stromal tissues of the ovary. Ovarian fibromas account for approximately 4% of all ovarian tumors, and thecomas are less common, constituting about 1% of all ovarian neoplasms. These tumors are usually unilateral and solid, and they often occur in perimenopausal and postmenopausal women. Thecoma may produce estrogen, leading to endometrial hyperplasia or abnormal uterine bleeding, whereas fibromas are typically hormonally inactive.

Clinically, patients may present with abdominal pain, distension, or an adnexal mass. In some cases, Meigs' syndrome (ascites and pleural effusion) may be associated. Diagnosis is made through imaging and confirmed by histopathological examination.

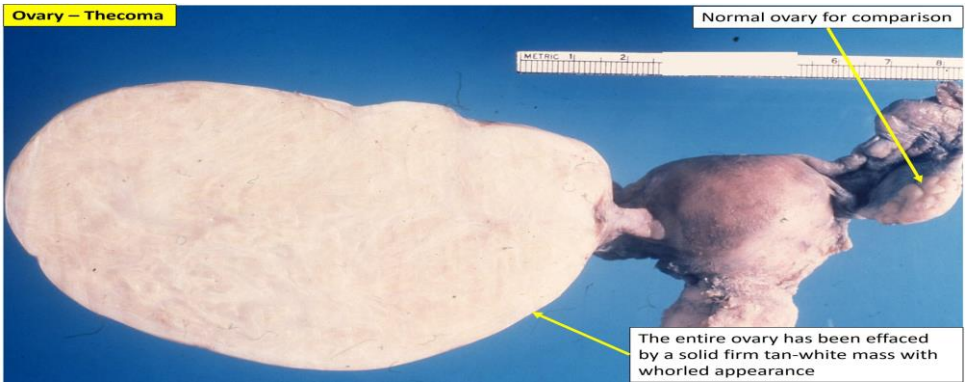

CASE PRESENTATION

A 45-year-old female presented to hospital with complaints of heavy menstrual bleeding clots 5days/28, 4-5 pads/day and had history of irregular cycle since 4 months ; once in 15 days
- The patient had a known case of Diabetes Mellitus since 10years, Hypertension since 3 years and was on

- T. Voglian GM2 – 0.2mg+2mg+500mg
- T. Metoprolol succinate – 50mg
- T. Tritelsar – 6.25mg+5mg+40mg

OTHER INVESTIGATIONS :

- U/S- Abdomen & Pelvis
  - Mild hepatomegaly with grade-II fatty changes
  - Well defined solid hypoecholic lesions in right adnex , right ovary not separately visualized
  - P/O- Ovarian Fibroma / Thecoma

From the investigations the patient was diagnosed with **Nulligravida with AUB with Right Ovarian Fibroma / Thecoma.**

TREATMENT CHART:

TRADE NAME	Generic Name	Dose	Route	Frequency	Therapeutic Action/Use
T. VOGLIAN GM	Voglibose + Glimepiride + Metformin	0.2 mg + 2 mg + 500 mg	Oral (PO)	BD	Antidiabetic – helps control blood glucose levels in Type 2 Diabetes Mellitus
T. METOPROLOL	Metoprolol Succinate	50 mg	Oral (PO)	OD	Beta-blocker – reduces blood pressure and heart rate
T. TRITELSAR	Telmisartan + Amlodipine + Chlorthalidone	40 mg + 5 mg + 6.25 mg	Oral (PO)	OD	Antihypertensive – controls blood pressure
INJ. MIXTARD	Insulin Human (Mixtard)	30/70 (as prescribed)	Subcutaneous (SC)	BD	Insulin therapy – maintains blood glucose level
T. ISTAMET	Sitagliptin + Metformin	50 mg + 500 mg	Oral (PO)	OD	Antidiabetic – improves glycemic control

INJ. BASALOG	Insulin Glargine	100 IU/ml	Subcutaneous (SC)	OD	Long-acting insulin – maintains basal glucose control
T. ROSUVAS	Rosuvastatin	20 mg	Oral (PO)	HS	Lipid-lowering agent – reduces cholesterol and cardiovascular risk
T. NIFFTAS	Nitrofurantoin	100 mg	Oral (PO)	BD	Antibiotic – used for urinary tract infections
T. PAN	Pantoprazole	40 mg	Oral (PO)	OD	Proton pump inhibitor – reduces gastric acid secretion

CONCLUSION

Ovarian fibroma/thecoma is a rare benign ovarian tumor with a favorable prognosis following surgical excision. Accurate diagnosis through imaging and histopathology is essential to distinguish it from malignant ovarian lesions and to ensure appropriate management.

REFERENCES

1. Outwater EK, Wagner BJ, Mannion C, McLarney JK, Kim B. Sex cord-stromal and steroid cell tumors of the ovary. Radiographics. 1998;18(6):1523–46.

2. Scully RE, Young RH, Clement PB. Tumors of the ovary, maldeveloped gonads, fallopian tube, and broad ligament. Washington DC: Armed Forces Institute of Pathology; 1998.

3. Tavassoli FA, Devilee P, editors. World Health Organization Classification of Tumours: Pathology and Genetics of Tumours of the Breast and Female Genital Organs. Lyon: IARC Press; 2003.

4. Gupta N, Bisht D, Agarwal AK, Sharma VK. Ovarian fibroma/thecoma: Clinicopathological correlation with review of literature. J Clin Diagn Res. 2015;9(9):EC08–EC11.

5. Akhter N, Rani R, Arif S. Ovarian fibroma with Meigs' syndrome: A case report. J Clin Diagn Res. 2014;8(9):OD03–OD04.

6. Duhan N, Sirohiwal D, Gulati A, Dahiya P. Ovarian thecoma presenting as postmenopausal bleeding: A case report. Case Rep Obstet Gynecol. 2012;2012:1–3.

7. aur R, Kaur A, Kaur R, Sood N. Ovarian fibroma: A clinicopathologic study of 25 cases. Ann Pathol Lab Med. 2019;6(10):626–30.

8. Usubutun A, Ozyalvacli ME, Kucukali T. Thecomas and fibrothecomas of the ovary: A clinicopathologic study of 55 cases. Turk J Pathol. 2010;26(2):99–104.