International Journal of Allied Medical Sciences and Clinical Research (IJAMSCR)

ISSN: 2347-6567

IJAMSCR |Volume 3 | Issue 2 | April-June- 2015
www.ijamscr.com

Review article *Medical research*

Osteoarthritis of knee joint

[1]Mrudula Chandrupatla, [2]Naveena Swargam
***Corresponding author: Mrudula Chandrupatla**

ABSTRACT
Osteoarthritis of knee joint is also called as osteoarthrosis or degenerative joint disease. It is a progressive disorder of joint caused by gradual loss of cartilage and resulting in the bony spurs and cysts at the margin of the joint. It is the common disease causing morbidity in old age. The etiology, pathology, clinical features, treatment by various methods including physiotherapy is discussed.
Key words: Osteoarthritis, knee joint, osteoarthrosis, degenerative joint disease.

INTRODUCTION
Osteoarthritis (OA), which is also known as osteoarthrosis or degenerative joint disease (DJD), is a progressive disorder of the joints caused by gradual loss of cartilage and resulting in the development of bony spurs and cysts at the margins of the joints. The name osteoarthritis comes from three Greek words which mean bone, joint and inflammation. Because of the inflammation the bones of the joints rub against one another resulting in pain, swelling and stiffness.

ETIOLOGY & INCIDENCE
Obesity is strongly associated with osteoarthritis in the knee and to a lesser degree in the arthritis of hip. Trauma to a joint with injury to the cartilage is associated with a high incidence of osteoarthritis later. Ligament laxity, slight degrees of acetabular dysphasia, excessive and repeated loading of a joint predisposes to osteoarthritis. It is more common above 40yrs of age more common in females than males.

CLASSIFICATION ACCORDING TO THE ETIOLOGY
♦ Primary or idiopathic cause: - Where no known cause can be found, although genetic factors are important. The distribution of joint involvement may be localized or generalized.
♦ Secondary cause: - Where a definite cause can be found. E.g. an old fracture through the joint or a disease damaging the cartilage

ANATOMY OF KNEE JOINT
Knee joint is compound synovial joint, incorporating two condylar joints between the condyles of the femur and tibia and one saddle joint between the femur and the patella. It is supported by the ligaments like fibrous Capsule Coronary Ligament attached to the periphery of the menisci, Short Lateral Ligament, Ligamentum Patellae, Tibial and Fibular Collateral Ligament, Oblique Popliteal, Arcuate Ligament, Cruciate Ligament (Anterior and posterior), Menisci fibro-cartilaginous discs. It is surrounded by many bursae. Articular cartilage (a specialized hyaline cartilage) covers the ends of the long bones providing the smooth gliding surface of the joint. It is lubricated by synovial fluid. Cartilage is made up of cells (chondrocytes) that produce the extra cellular material (the matrix). The matrix consists of sheets of

collagen fibres with large proteoglycan molecules lying between these fibres. The collagen fibres run vertically from the bone upwards towards the surface of the joint, where they change direction and then run parallel with the surface of the cartilage. The proteoglycans of cartilage are large molecules composed of a very long central chain of hyaluronic acid with numerous side chains attached along its length. These side chains consist of a central protein core with chondroitin sulphate and keratan sulphate molecules linked to it. Proteoglycan molecules are negatively charged and as such are highly hygroscopic (attract water). These long molecules lie between the collagen fibres. As they attract water they swell, putting the collagen fibres under tension. It is this tension that gives cartilage its characteristic tensile properties.

MACROSCOPIC CHANGES IN CARTILAGE AND BONE

The first visible damage to cartilage is softening and swelling. This is caused by rupture of collagen fibres, with the proteoglycans absorbing more water and the cartilage swelling up. At this stage the cartilage is considerably weakened. The second stage is fibrillation. Fine flakes of superficial cartilage become loosened and flake off. Cracks appear in the cartilage and eventually run through the full thickness of the cartilage. The third stage is continued erosion of the cartilage with the ultimate loss of the full thickness of the cartilage. When the cartilage has been lost, the exposed bone becomes very hard with a polished appearance and eventually looks like ivory, hence the term eburnation of bone. Small effusions form in the joint. This fluid is forced through the clefts (cracks) and into the underlying bone to form sub- chondral cysts that can be seen on X-ray. The osteoblasts of bone underlying the damaged cartilage are stimulated to produce new bone, which clinically presents as sub-chondral sclerosis on X-ray. New bone growth is also stimulated around the edge of the joint, forming a lip of bone called an osteophyte.

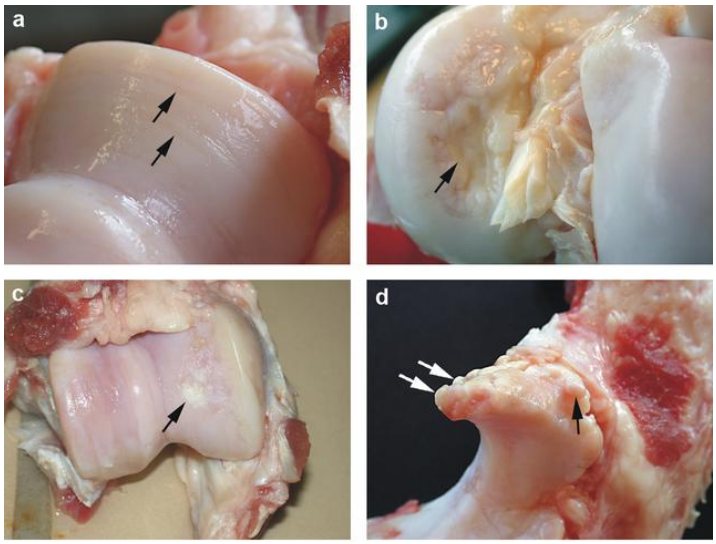

Fig No 1: Shows the normal cartilage and the changes seen in osteoarthritis

PATHOLOGY

When load is applied to cartilage some of the water is 'squeezed' out, which immediately increases the negative ionic charge in the proteoglycan molecules and results in a greater hygroscopic force to attract water back again once the load has been lifted. These biomechanical properties of cartilage are dependent upon an intact collagen and proteoglycan system. Any factor damaging the collagen, proteoglycans or the chondrocytes will result in cartilage breakdown and osteoarthritis. Abnormal loading of cartilage e.g. a varus deformity of a knee will, with time, lead to breakdown of the overloaded cartilage in the medial compartment of the knee. Disease processes e.g. infection or rheumatoid arthritis, can also irreparably damage cartilage with secondary osteoarthritis developing at a later stage.

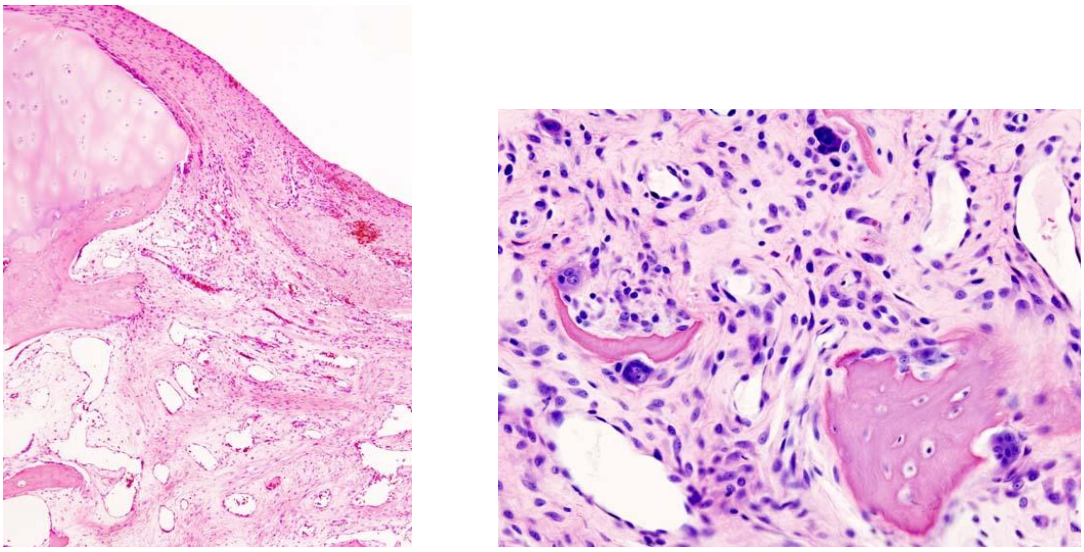

Fig No 2: Histological changes seen in the cartilage in osteoarthritis

ONSET

The onset is usually slow. The patient at first notices an ache in the involved joint, often immediately after use. Occasionally the onset is acute, usually after mild trauma. In these patients the disease has been present for some time but the clinical symptoms were precipitated by the mild trauma. There is a gradual and intermittent in some patients, even with considerable radiographic changes of osteoarthritis, there is little or no pain

CLINICAL FEATURES

1) Pain is the most important symptom of osteoarthritis. The pain may be diffuse or sharp and stabbing, but is associated with use of the joint. Later in the course of the disease 50% have pain at rest and 30% get pain at night. Pain in the soft tissues around the joint is also common. The muscles surrounding the joint may be painful and are often weak. Strengthening these muscles can relieve much of this pain.

2) Stiffness in the involved joints after periods of inactivity. This is also called 'gelling' and passes over within minutes of using the joint again. Coarse crepitations can be felt as the joint moves, due to the roughened surfaces moving over each other. In advanced osteoarthritis the crepitations may be heard as well as felt. With advanced disease the range of movement of the joint is reduced. This is due to thickening of the capsule together with bony changes within the joint.

3) Soft tissue swellings due to mild synovitis and effusions are seen, particularly in advanced disease. Osteophytes are deposits of bone around the rim of the involved joint. The cartilage loss leads to pseudolaxity of the joint, with the excessive forces on the periosteum at the joint margin stimulating new bone formation. In advanced disease the destroyed joints become deformed with various angulations. The degree of functional loss and disability depends on which joint is involved.

INVESTIGATIONS

RADIOLOGIC FEATURES

Cartilage is not visible on X-ray and leaves a space between the bone ends. Narrowing of this space indicates loss of cartilage. A white sclerotic area in the Sub-chondral bone is typical of osteoarthritis. Cysts may be seen in the bone underneath the cartilage. These are due to synovial fluid penetrating through cracks in the cartilage. Osteophytes appear as bony ridges around the rim of the joint.



Fig No 3: X ray of knee

TREATMENT

There is no 'specific' therapy but a wide variety of treatments are available for osteoarthritis sufferers. Treatment covers a number of goals like prevention, therapy for established disease, education and exercise program. Conservative treatment includes Simple analgesics (paracetamol / low dose ibuprofen), NSAID's in full doses, Intra-articular corticosteroids, Topical treatment e.g. anti-inflammatory creams. Surgical Treatment includes Osteotomy (knee), Joint replacement, Debridement, Tidal lavage (knee). Knee arthroscopic surgery is a procedure performed through small incisions in the skin to repair injuries to tissues such as ligaments, cartilage, or bone within the knee joint area. The surgery is conducted with the aid of an arthroscopy, which a very small instrument is guided by a lighted scope attached to a television monitor. Arthroscopic surgeries range from minor procedures such as flushing or smoothing out bone surfaces or tissue fragments (lavage and debridement) associated with osteoarthritis, to the realignment of a dislocated knee and ligament grafting surgeries. The range of surgeries represents very different procedures, risks, and aftercare requirements.

PHYSIOTHERAPY MANAGEMENT

Provides psychological support and enhance confidence in patient to relieve pain, inflammation, muscle spasm and wasting. It improves functional capacity of patient and prevents contractures and deformities. In acute conditions superficial heat therapy in the form of paraffin wax bath, I.R. therapy is given. In Chronic conditions pain and inflammation can be treated by SWD, MWD which are meant for deep tissue heating. Splintage of the joints in proper position by means of thermoplastic splints. Traction relieves inflammation and muscular spasm. Periodic, Frequent Isometric Exercises. Massage with Aloe-Vera pulp has shown excellent relief of pain and inflammation. Alternation in the foot wear. Advice supports (walking aid) for ambulation. PNF, Aerobics for improving joint proprioception. Advice the patient about diet and precautionary measures to prevent obesity.

PHYSIOTHERAPY MANAGEMENT FOR POST-OPERATIVE PATIENT

POST-OPERATIVE DAY 1-5

Allow the patient to assume semi recumbent position. Active and active assisted exercises by slowly progressing the range daily. After 48 hours, if patient medical status is stable, encourage weight bearing exercises. Practice weight transference and balance exercises. Few steps can be taken with help of walking aid.

POST –OPERATIVE DAY 5-7

Active and active assisted exercises. Sliding board, weight bearing, active ankle, toe exercises. Few steps can be taken with help of walking aid.

DAY 7-12 POST-OPERATIVELY

tair climbing with walking aid. Isometric, Mobilizing and strengthening Exercises, Progress from crutches to sticks, continue the mode of treatment mainly concentrating of the joint, Mobility and functional rehabilitation of patient.

CONCLUSION

Although osteoarthritis is a chronic disease that is currently incurable, it is not untreatable. An optimistic outlook and a rational individualized treatment plan should be adopted for every patient.

REFERENCES

[1]. Brandt KD, Dieppe P, Radin E (January 2009). "Etiopathogenesis of osteoarthritis". Med. Clin. North Am. 93 (1): 1–24

[2]. Van der Kraan, PM; van den Berg, WB (April 2008). "Osteoarthritis in the context of ageing and evolution. Loss of chondrocyte differentiation block during ageing." Ageing Research Reviews 7 (2): 106–13.

[3]. Maroudas AI (April 1976). "Balance between swelling pressure and collagen tension in normal and degenerate cartilage". Nature 260 (5554): 808–9.

[4]. Zhang W, Moskowitz RW, Nuki G et al. (February 2008). "OARSI recommendations for the management of hip and knee osteoarthritis, Part II: OARSI evidence-based, expert consensus guidelines". Osteoarthr. Cartil. 16 (2): 137–62.

[5]. Page CJ, Hinman RS, Bennell KL (2011). "Physiotherapy management of knee osteoarthritis". Int J Rheum Dis 14 (2): 145–152.