ISSN: 2347-6567

International Journal of Allied Medical Sciences and Clinical Research (IJAMSCR)

IJAMSCR |Vol.13 | Issue 4| Oct - Dec -2025

www.ijamscr.com

DOI : https://doi.org/10.61096/ijamscr.v13.iss4.2025.628-632

Case Study

A Case Report on Addisons Disease: Clinical Presentation and Management

HP. Sahana[1], Jahnavi G[*2], Sumangala V[3], EP. Akshitha[4], B Sneha[5], Dr. Syed Mohammed Hussaini[6]

[1,2] *Interns, Pharm D, TVM College of Pharmacy, Ballari*
[3,4,5] *Vth Pharm D students, TVM College of Pharmacy, Ballari*
[6] *Assistant Professor, TVM College of Pharmacy, Ballari*

*Author for Correspondence: Jahnavi G
Email: jahnavi.gorava@gmail.com

Published on: 25 Oct 2025

Published by:
Futuristic Publications

2025| All rights reserved.

Creative Commons Attribution 4.0 International License.

Abstract

Background: Addison's disease, also known as primary adrenal insufficiency, is a rare endocrine disorder characterized by inadequate production of glucocorticoids and mineralocorticoids from the adrenal cortex. It can present with nonspecific symptoms and is often associated with autoimmune or infectious etiologies, such as tuberculosis.

Case Presentation: A 45-year-old male was admitted with complaints of nausea, vomiting, generalized weakness, hyperpigmentation of the buccal mucosa, and darkening of skin and nails. Laboratory investigations revealed hyponatremia, hypotension, and low serum cortisol levels. Imaging studies, including chest X-ray and CT scan, showed miliary tuberculosis and bilateral adrenal enlargement. The patient was diagnosed with Addison's disease secondary to adrenal tuberculosis. Management included intravenous hydrocortisone, correction of electrolyte imbalance, antitubercular therapy, and supportive care. On discharge, oral hydrocortisone and fludrocortisone were prescribed, with counseling on medication adherence and lifestyle modification.

Conclusion: Addison's disease remains a potentially life-threatening but treatable condition. Early recognition of characteristic features such as hyperpigmentation and persistent hyponatremia can facilitate timely diagnosis. Integrated management involving corticosteroid replacement, treatment of underlying causes, and patient education is essential to prevent adrenal crises and improve quality of life.

Keywords: Addison's disease; Primary adrenal insufficiency (PAI); Adrenal tuberculosis; Hydrocortisone therapy; Hyperpigmentation; Electrolyte imbalance; Case report

INTRODUCTION

Addison's disease (AD) – it is also known as primary adrenal insufficiency(PAI) or hypocortisolism[1]. It is a rare endocranial disorder as it defines – the clinical manifestation of chronic glucocorticoid and/or mineralocorticoid deficiency due to failure of the adrenal cortex to produce these hormones from adrenal gland. Which may result in adrenal crisis with potentially life threatening conditions[2,3].

It affects 1 in 100,000 people which is seen in all age groups affecting both male and female equally[2]. In addition the main causes of this disease are autoimmune, infectious, neoplastic and genetic disorders, other iatrogenic conditions – mostly due to pharmacological side effects all these are contributing factors to this phenomenon[3]. Autoimmune adrenalitis is the leading cause of addisons disease in adults, it can occur as an isolated condition or as a part of autoimmune polyglandular syndromes (APS) with over 50% of cases being linked to additional autoimmune disorders[4]. In addition to autoimmune adrenalitis, the other conditions also can directly impact the adrenal glands such as tuberculosis, advanced HIV infections, systemic fungal infections, secondary(Metastatic) cancer's, adrenal haemorrhage, over 50% of case's were caused by tuberculosis, 30% by neoplastic or metastatic disease and about 10% by haemorrhage[1,4].

In Addison's disease patients may occasionally present with life-threatening complications as the first manifestation of conditions and the impact of this condition develops the nature of stressful triggers and the patient's background medical conditions[5].

The final diagnosis Is often made when patients present with symptoms of acute adrenal insufficiency known as "adrenal crisis" diagnosed with a variety of blood and imaging tests used to confirm adrenal insufficiency such as serum cortisol test, ACTH stimulation test, autoantibody studies, insulin – induced hypoglycemia test[1,6]. A diagnosis is typically initiated based on signs and symptoms such as general fatigue or severe weakness and unexplained dehydration, hypotension, weight loss, salt craving, fever, vomiting/nausea, abdominal pain, hyperpigmentation[3]. Hyponatremia and hyperkalemia are commonly associated with Addison's disease while hypoglycaemia is uncommon[2].

It is primarily treated and managed with life – long hormone replacement therapy, typically includes glucocorticoid (hydrocortisone) and mineralocorticoid (fludrocortisone). In most cases this would involve oral steroid medication (eg : prednisone, Dexamethasone)[7].

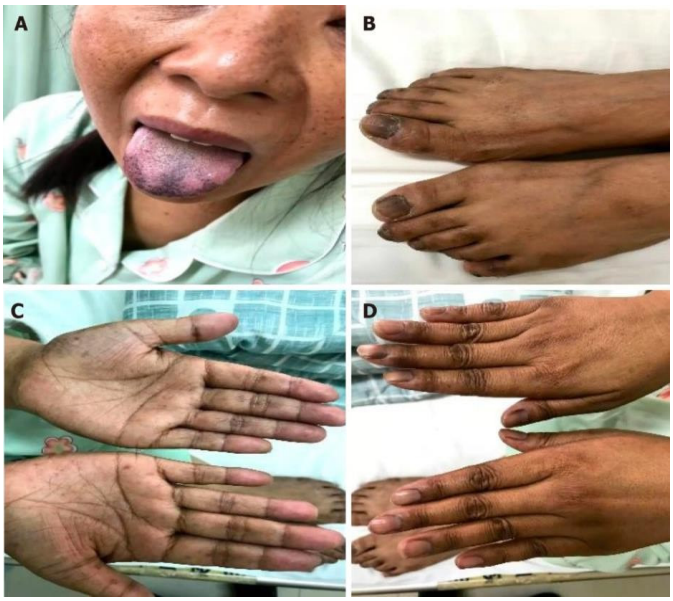

Fig 1: (A) Hyperpigmentation on the skin of face, mouth, tongue and mucous membrane of the lips (B-D) Hyperpigmentation on nails, hands and feet (8).

CASE REPORT

A 45 years men admitted to the male medical ward of general medicine in tertiary care hospital, with the chief complaints of nausea since 4 days, c/o of weakness, headache, abdominal pain, high cough. Since 1 month, vomiting since morning 3 episodes, patient also present with a complaints of generalized blackish hyperpigmentation of the skin, oral mucous membrane and nails. His history of present complaints reveals that he was A/H/O self fall bader influence of alcohol a week ago on road detected and sustained injury to left lower

limb referred from TECC I/V/O HYPONATREMIA. His past history revealed that he was known case of seizure and since 1 year. He was known alcoholic since 15 years last drink was 3 days back of admission. On examination his BP was 90\70mm of Hg, Pulse rate was 114 bpm and Spo_2 was 97%@RA. External examination physician advised for tests like Complete blood count, Liver function tests, Kidney function tests, Biochemistry, USG abdomen and pelvis, Serum electrolytes, ECG (Electrocardiogram), Hormonal assay (Thyroid function test, serum cortisol) test for further diagnosis. In view of his darker complexion compared with other family members, hyponatremia and hypotension evaluations for Addison's disease were also performed

Table 1: Laboratory Parameters

S. No	Tests	Parameters	Results on Admission	Results During Inwards	Reference Range
1	COMPLETE BLOOD COUNT	Haemoglobin	10.5	11.1	12.5-16 gm%
		Total WBC Count	8340	8330	4000-11000 cells/cumm
		Neutrophils	78	86	40-70%
		Lymphocytes	12	10	20-50%
		Platelets	2.73	2.42	1.5- 4.5 lacs/cumm
		Eosinophils	03	02	3-6 %
		RBC Count		3.71	5.5- 6.5 million/cumm
		PCV		32.0	45-55 %
		ESR		43	0-10 mm/hr
2	RENAL FUNCTION TESTS	Serum urea	58	50	15-45 mg/dl
		Serum creatinine	3.2	2.5	0.7-1.4 mg/dl
3	SERUM ELECTROLYTES	Sodium	101	129	136-146mEq/l
		Potassium	4.0	3.8	3.48-5mEq/l
		Chloride	68	100	96-106mEq/l
4	BIOCHEMISTRY	Random blood sugar	88	67	70-140 /dl

ECG (ELECTROCARDIOGRAPH): NORMAL SINUS RHYTHM
HORMONAL ASSAY: serum cortisol - (4.30 - 22.40 [morning])
1.5 ug/dl
After 5 days, cortisol level was 3.01 ug/dl
THYROID FUNCTION TEST:
FT3 (FREE T3): 3.29 pg/ml
FT4 (FREE T4) :- 1.8 ng/dl
CHEST X RAY: miliary pattern in addition to mild bilateral pleural effusion.
CT SCAN: Enlarged adrenal gland.
USG ABDOMEN AND PELVIS: Nephropathy grade 1

Table 2: Treatment Chart

Sl.No	Name of The Medication	Dose	Route	Frequency	Duration
1.	Inj. Sodium chloride	100mlover 4hours	IV	1-1-1	D1-D4
2.	Inj. Levetiracetam	500mg	IV	1-0-1	D1-D4
3.	Inj. Sodium bicarbonate	10ml	IV	1-1-1	D1-D4
4.	Inj. Hydrocortisone	100mg	IV	1-0-1	D1-D4
5.	T. Tolvaptan	15mg	PO	1-0-0	D5
6.	Tab ATT		PO	1-0-0	

The patient was treated with above medications.

Table 3: Discharge Medication

Sl.No	Name of The Medications	Dose	Route	Frequency
1.	Tab. Levetiracetam	500mg	PO	1-0-1~15days
2.	Tab. Iron folic acid	333mg	PO	1-0-1~15days
3.	Tab. Folic acid	5mg	PO	1-0-0~15days
4.	Tab. Pantoprazole	40mg	PO	1-0-0~3days
5.	Tab. Tolvaptan	15mg	PO	1-0-~3days
6.	Tab. Sodium bicarbonate	500mg	PO	1-1-1~15days
7.	Tab Hydrocortisone	10mg	PO	1-0-1~15days
8.	Tab. Fludrocortisone	50mg	PO	1-0-0
9.	Tab ATT		PO	1-0-1

Suggested to review after 2 weeks.

DISCUSSIONS

Addison disease maybe caused by various pathological process, the common cause of addisons disease are autoimmune and tuberculosis. Primarily TB bacilli enters the body(lungs) and disseminated to other organs such as adrenal glands via blood stream. There it triggers granulomatous inflammatory responses forming caseating granulomatous and fibrosis and calcification. Both the adrenals are involved in this process, cortical tissue is progressively destroyed leading to decreased production of cortisol and aldosterone resulting in permanent adrenal insufficiency.

Hormonal deficiencies like cortisol deficiency, aldosterone deficiency, androgen deficiency and increased adrenocortico tropical hormone (ACTH) and melanocyte stimulating hormone (MSH) can also lead to addisons disease[9,10].

The aim Is to treat the cause (tuberculosis or autoimmune). Hydrocortisone therapy is primary treatment for addisons disease, Antitubercular therapy and Crisis management therapy is used as well for the treatment.

Here Is case of 45 years male with the complaints of nausea, weakness, headache, abdominal pain, high cough, vomiting, also present with a complaints of generalized blackish hyperpigmentation of the skin, oral mucous membrane and nails. He has been advised for laboratory examination which reved that abnormality of Complete blood count, Renal function test, serum electrolytes and biochemistry. Serum cortisol levels decreased, chest x ray showing miliary pattern in addition to mild bilateral pleural effusion, CT scan showing enlarged adrenal gland and USG abdomen resulting in nephropathy. The treatment given is Inj Hydrocortisone 100mg Iv to treat addisons disease, levetiracetam to treat seizures (past history) , tolvapton and sodium chloride used to treat hyponatremia, and sodium bicarbonate used to treat nephropathy by prevent metabolic acidosis, ATT to treat tuberculosis.

In discharge medication, fludrocortisone was given to treat addisons disease and Iron folic acid was added to treat iron folic acid deficiency due to nephropathy condition. Patient was counselled about disease like awareness, prevention, symptoms and complications, about drugs like compliance and life style modification like management of disease and intercurrent illness.

CONCLUSION

Addison disease is a potentially rare life threating condition, it is related to autoimmunity or associated with tuberculosis. It is a longterm disease which as challenge for patients to manage with the condition. Symptoms such as fatigue, weight loss, skin hyperpigmentation, hypotension and abdominal pain can be observed. Hyperpigmentation of tongue, buccal cavity (mouth) than skin pigmentation is primarily observed clinical presentation hence dentist would be the first person who are likely to observe the disease and diagnosis. Ensuring early diagnosis. Identifying patients who may be at risk of adrenal insufficiency on the basis of their medication history, taking into account any recently discontinued medicines, it would be useful in patients in tuberculosis for early diagnosis. Adequate medication with compliance would be likely to prevent the disease more efficiently. Patient and patient attenders should to counselled about the disease, drug and life style modification. Complications such as psychotic symptoms are present due to hydrocortisone treatment so anti psychotic treatment temporarily started to reduce the symptoms and prevention of long term effects but should not be used for long period of time. Aware about managing the inter current illness along with Addison's disease will help to cure the disease effectively.

REFERENCES

1. Myhre J, Sifris D. Addison's disease: an overview. Verywell Health. Updated 2024 Mar 20. Medically reviewed by Opole IO. Available from: https://www.verywellhealth.com/addisonsdisease-4172782
2. Sarkar SB, Sarkar S, Ghosh S, Bandyopadhyay S. Addison's disease. Contemp Clin Dent. 2012;3(4):484-6. Doi:10.4103/0976-237X.107450
3. Barthel A, Benker G, Berens K, Diederich S, Manfras B, Gruber M, et al. An update on Addison's disease. Exp Clin Endocrinol Diabetes. 2019;127(3):165-70. Doi:10.1055/a-0804-2715
4. Alharbi SA, Fardan RH, Almahasnah MS, Alsaeed NA, Kashif HH, AlGhamdi NA, et al. Recent developments in the diagnosis and treatment of Addison's disease. Int J Community Med Public Health. 2024 Dec;11(12):4990-5. Doi:10.18203
5. Kumar R, Wassif WS. Adrenal insufficiency. J Clin Pathol. 2022;75(6):435-42. Doi:10.1136/jclinpath-2021-207895 /2394-6040.ijcmph20243414
6. Mosca AM, Barbosa M, Araújo R, Santos MJ. Addison's disease: a diagnosis easy to overlook. Cureus. 2021 Feb 15;13(2):e13364. Doi:10.7759/cureus.13364
7. Burton C, Cottrell E, Edwards J. Addison's disease: identification and management in primary care. Br J Gen Pract. 2015;65(638):488-90. Doi:10.3399/bjgp15X686713
8. Zhang TX, Xu HY, Ma W, Zheng JB. Addison's disease caused by adrenal tuberculosis may lead to misdiagnosis of major depressive disorder: A case report. World J Clin Cases 2024; 12(1): 217223 [PMID: 38292640 DOI: 10.12998/wjcc.v12.i1.217]
9. Vinnard C.Blumberg EA.2017.Endocrine and Metabolic Aspects of Tuberculosis. Microbiol Spectr5:10.1128/microbiolspec.tnmi7-0035-
10. 2016.https://doi.org/10.1128/microbiolspec.tnmi70035-2016 Jacob, Jubbin & Paul, Preethi. (2021). Infections in Endocrinology: Tuberculosis.