ISSN: 2347-6567

International Journal of Allied Medical Sciences and Clinical Research (IJAMSCR)

IJAMSCR |Vol.13 | Issue 3| Jul - Sept -2025

www.ijamscr.com

DOI: https://doi.org/10.61096/ijamscr.v13.iss3.2025.539-545

Review

Gallbladder Cholecystitis: Current Concepts, Global Trends, and Traditional Herbal Interventions

S. Ramesh Kumar[1], B. Yuvankarthik*[2], G. Subitcha Jabakani[2], N.B. Maduvarshan[2], M. Navaneetha Krishnan[3], S. Nandhini[3], P.V. Agalya Gayathri[3]

[1]Assistant Professor, Department of Pharmaceutical Chemistry, College of Pharmacy, Madurai Medical College, Madurai, Tamil Nadu, India.
[2]Research Scholar, Department of Pharmaceutical Chemistry, College of Pharmacy, Madurai Medical College, Madurai, Tamil Nadu, India.
[3]Research Scholar, Department of Pharmacognosy, College of Pharmacy, Madurai Medical College, Madurai, Tamil Nadu, India.

*Author for Correspondence: B. Yuvankarthik
Email: yuvankarthikbabu63@gmail.com

Published on: 15 Sep 2025

Published by:
Futuristic Publications

2025| All rights reserved.

Creative Commons Attribution 4.0 International License.

Abstract

Acute inflammatory gallbladder cholecystitis is typically brought on by gallstone blockage of the cystic duct, which results in gallbladder wall inflammation, secondary infection, and bile stasis. Often leading to emergency surgical intervention, it is a major worldwide health burden. An extensive examination of the disease's history, origin, worldwide epidemiology, pathophysiology, clinical characteristics, diagnostic methodology, research, and therapeutic approaches is given in this article. The classification and management guidelines of the Tokyo Guidelines 2018 are specifically discussed, along with the function of minimally invasive procedures such percutaneous drainage and laparoscopic cholecystectomy. The review also emphasizes the potential application of traditional medicinal herbs and their bioactive phytoconstituents in the prevention and treatment of cholecystitis, particularly in environments with limited resources. Precision diagnostics, non-operative options including endoscopic gallbladder drainage, and biomarker discovery are the main focuses of current research developments. In light of the increasing prevalence and healthcare burden, the best possible patient outcomes require a thorough and customized approach to diagnosis, treatment, and prevention.

Keywords: Gallbladder cholecystitis; Cholelithiasis; Laparoscopic cholecystectomy; Acute inflammation; Herbal medicine.

INTRODUCTION

Acute cholecystitis is a common and potentially dangerous gallbladder inflammation that is most often caused by gallstones (cholelithiasis) blocking the cystic duct. This condition causes bile stasis, secondary infection, and gallbladder wall inflammation. Leukocytosis, fever, and abdominal pain in the right upper quadrant are some of the symptoms that might accompany this illness, which accounts for a sizable percentage of emergency general surgery admissions globally. About 5–10% of instances are acalculous, which are frequently observed in severely unwell or hospitalized patients, but the majority are calculous. Perforation, abscess formation, and gallbladder gangrene are among the complications that emphasize the significance of prompt diagnosis and effective treatment.

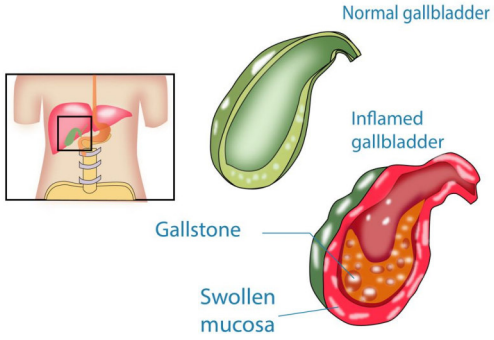

Fig 1: Gallbladder Cholecystitis

Imaging techniques such as ultrasonography and hepatobiliary iminodiacetic acid (HIDA) scans play a vital role in diagnosis. Treatment often comprises supportive care, antibiotics, and prompt cholecystectomy. The importance of continuous improvements in the knowledge and treatment of cholecystitis in clinical practice is highlighted by the rising incidence of gallstone disease and developments in minimally invasive surgical procedures. [1]

HISTORICAL BACKGROUND

Over the ages, the historical understanding of gallbladder cholecystitis has changed dramatically, reflecting improvements in surgical procedures, diagnostic methods, and anatomical knowledge. Gallstones were found in Egyptian mummies as early as 1500 BCE, and gallstone-related illnesses were first clinically described in ancient civilizations. Nevertheless, more distinct pathological associations were not discovered until the 18th and 19th centuries. The 19th century saw the introduction of the word "**cholecystitis**" as pathologists realized that the illness was inflammatory. [2] The first successful open cholecystectomy was carried out in Berlin by Carl Langenbuch in 1882, which was a turning point in the surgical management of gallbladder illness.

The capacity to effectively diagnose cholecystitis was improved over the 20th century by advancements in imaging techniques, including oral cholecystography and ultrasonography. By drastically lowering postoperative morbidity and hospital stays, laparoscopic cholecystectomy, which was introduced in the late 1980s, transformed management. From empirical management to evidence-based, minimally invasive care, historical changes in the diagnosis and treatment of cholecystitis reflect larger trends in medical innovation.

ETIOLOGY

Gallbladder cholecystitis, also known as calculous cholecystitis, is most frequently caused by gallstone blockage of the cystic duct, which accounts for 90–95% of cases. The mechanical blockage causes bile stasis, elevated intraluminal pressure, and gallbladder wall inflammation. Enteric pathogens such as *Escherichia coli*, *Klebsiella*, and *Enterococcus* species may then secondary infect the gallbladder wall. While acalculous cholecystitis accounts for 5–10% of occurrences, it usually affects critically sick patients and is associated with sepsis, systemic hypoperfusion, trauma, major surgery, prolonged fasting, and complete parenteral feeding. Acalculous cholecystitis is caused by ischemia injury and biliary sludge accumulation, which leads to inflammation even when gallstones are not present. Neoplastic blockage, biliary strictures, and parasite infections are additional, less frequent causes. The importance of gallbladder dysmotility, bile supersaturation, and dysregulated lipid metabolism in predisposing people to cholecystitis has also been emphasized by recent research. Comprehending the fundamental cause is essential for directing suitable treatment measures and averting consequences. [3]

GLOBAL DISEASE PROFILE

Gallstone disease, which affects 10–15% of adults in wealthy countries, is directly associated with the occurrence of gallbladder cholecystitis, which constitutes a substantial worldwide health burden. A significant number of hospitalizations for abdominal discomfort are due to acute cholecystitis, one of the most frequent side effects of cholelithiasis. According to epidemiological data, there is significant regional and demographic variance, with higher rates seen in Western nations, especially among those who are obese, older, and female. Parts of Asia and Africa, on the other hand, have lower incidence rates, while rising trends have been observed as a result of sedentary lifestyles, dietary changes, and increased urbanization.

Cholecystitis and other gallstone-related problems account for the majority of the more than 200,000 cholecystectomies performed each year in the United States. Laparoscopic cholecystectomy has become the standard of care worldwide, resulting in better results and shorter hospital stays.[4]Limited access to prompt surgical intervention and diagnostic imaging, however, remains a major problem in low- and middle-income nations. To effectively allocate resources, create preventative measures, and develop health policies in a variety of healthcare settings, it is imperative to comprehend the worldwide disease profile of cholecystitis.

PATHOGENESIS

Gallbladder wall inflammation is an outcome of a complex interaction between mechanical, chemical, and viral elements in the pathophysiology of gallbladder cholecystitis. The most common cause of calculous cholecystitis is gallstone blockage of the cystic duct, which results in bile stasis, elevated intraluminal pressure, and distension of the gallbladder wall. Pro-inflammatory mediators, including prostaglandins and cytokines, are released when this blockage causes ischemia of the gallbladder mucosa.[5] Bile stagnation also promotes bacterial growth, which can result in secondary infection. Common pathogens include *Escherichia coli*, *Klebsiella*, and *Enterococcus* species. The inflammation in acalculous cholecystitis, which usually affects severely ill or immune compromised people, is believed to be caused by gallbladder ischemia, biliary sludge build up, and direct mucosal damage from systemic hypo perfusion, even in the absence of gallstones. The inflammatory cascade also advances as a result of oxidative damage, neutrophil activation, and epithelial barrier breakdown. The illness may worsen into complications, including gangrene, empyema, or gallbladder perforation if treatment is not received, highlighting the significance of early detection and intervention.[6]

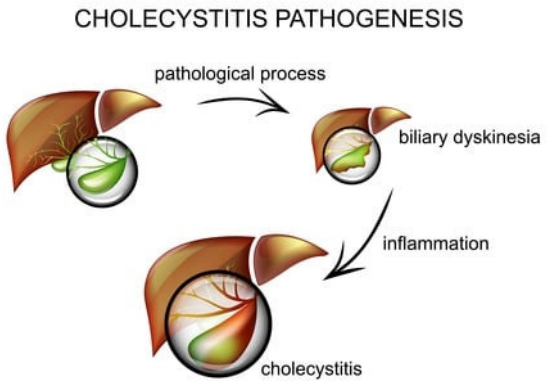

Fig 2: Pathogenesis of Gallbladder Cholecystitis

CLINICAL FEATURES

Gallbladder cholecystitis usually manifests as acute right upper quadrant (RUQ) abdominal discomfort, usually after a fatty meal. Diaphragmatic irritation can cause the pain to spread to the right shoulder or back. The pain is typically intense, ongoing, and gets worse over a few hours. Associated symptoms include anorexia, low-grade fever, nausea, and vomiting. When examining the RUQ during deep inspiration, a positive Murphy's sign marked discomfort and inspiratory arrest is a crucial diagnostic indicator that indicates gallbladder inflammation. In addition to the usual laboratory findings of fever and moderate leukocytosis, biliary obstruction or related cholangitis may be accompanied by increased liver enzymes or bilirubin levels. [7]

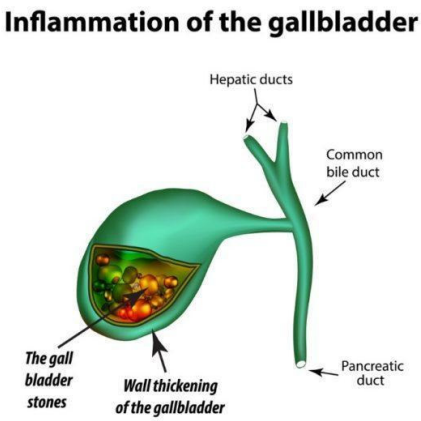

Fig 3: Gallbladder inflammation

Patients with diabetes, immune-compromised conditions, or the elderly may present with atypical or less pronounced symptoms, which could delay diagnosis and raise the risk of consequences. In more severe situations, jaundice, sepsis, or peritonitis symptoms could be signals of gangrene, perforation, or the formation of an abscess. For early diagnosis and treatment to reduce the morbidity and mortality linked to this illness, prompt identification of clinical characteristics is crucial. [6]

DIAGNOSIS

Gallbladder cholecystitis is diagnosed by a combination of imaging techniques, laboratory tests, and clinical evaluation. Clinically, the classic triad of acute cholecystitis is always present: fever, leukocytosis, and right upper quadrant discomfort. Laboratory tests frequently show a high white blood cell count and may also show moderate elevations in bilirubin, alkaline phosphatase, and liver enzymes, especially if cholangitis or biliary blockage are present. Confirming the diagnosis requires imaging. The first-line imaging modality is abdominal ultrasonography because it is widely available, non-invasive, and has a high sensitivity (81–94%) and specificity (83–100%) for identifying gallstones and cholecystitis symptoms, including thickening of the gallbladder wall (>3 mm), pericholecystic fluid, and a positive sonographic Murphy's sign. [8]

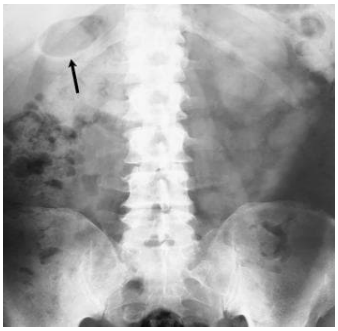

Fig 4: X-ray diagnosis

With a sensitivity of 97% and specificity of 90–95% in identifying acute cholecystitis, a hepatobiliary iminodiacetic acid (HIDA) scan is regarded as the gold standard for functional assessment when ultrasonography results are unclear. In complex or unusual instances, computed tomography (CT) and magnetic resonance imaging (MRI) might be helpful, particularly for identifying gangrene, perforation, or emphysematous alterations. Accurate diagnosis and prompt treatment depend on the integration of clinical data with diagnostic imaging. [1]

INVESTIGATION

A combination of laboratory tests and imaging modalities are used in the investigation of gallbladder cholecystitis in order to confirm the diagnosis, evaluate its severity, and spot any possible consequences. Leukocytosis with a neutrophilic preponderance, indicative of an acute inflammatory reaction, is usually found in first blood tests. When biliary blockage or cholangitis is present, liver function tests (LFTs) may reveal moderate

increases in alanine aminotransferase (ALT), aspartate aminotransferase (AST), alkaline phosphatase (ALP), and bilirubin. A high C-reactive protein (CRP) can help determine the severity of a disease. Because of its great sensitivity for gallstones and related symptoms like thickening of the gallbladder wall, pericholecystic fluid, and a positive sonographic Murphy's sign, abdominal ultrasonography is still the first-line imaging test.

A hepatobiliary iminodiacetic acid (HIDA) scan can be performed to evaluate gallbladder function and cystic duct patency in situations that are unclear; the diagnosis is strongly supported if the gallbladder cannot be seen following radiotracer administration. In older or immunocompromised individuals with unusual presentations, computed tomography (CT) is especially helpful in identifying complications such gangrenous or emphysematous cholecystitis, perforation, or abscess formation. In cases where common bile duct stones are suspected, magnetic resonance cholangiopancreatography (MRCP) may be used. When combined, these studies inform clinician judgment and enable timely, effective treatment. [1,9]

TREATMENT

Early surgical intervention is typically the cornerstone of treatments for gallbladder cholecystitis, with treatment mostly based on the severity of the condition and the patient's general clinical status. Since it lowers hospital stays, surgical complications, and recurrence rates, early laparoscopic cholecystectomy ideally within 72 hours of symptom onset is the gold standard for acute calculous cholecystitis. Initial cautious therapy with intravenous fluids, analgesics, and broad-spectrum antibiotics that target gram-negative and anaerobic organisms (e.g., *E. coli*, *Klebsiella*, *Enterococcus*) is frequently started in high-risk surgical candidates, such as elderly or severely ill patients.

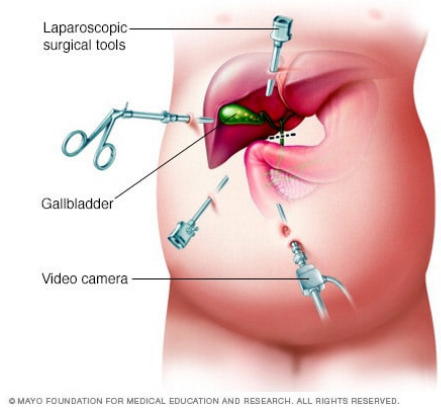

Fig 5. Gallbladder cholecystitis treatment

Percutaneous cholecystostomy performed under imaging guidance may be a temporary or permanent solution if surgery is not appropriate or cannot be performed right away, particularly in patients with organ dysfunction or sepsis. Because of the increased risk of complications like gangrene and perforation, early detection and drainage are essential in cases of acalculous cholecystitis, which usually affects the seriously unwell. Based on patient risk factors and patterns of local resistance, antibiotic regimens should be modified. By classifying patients into mild (Grade I), moderate (Grade II), and severe (Grade III) condition, the Tokyo Guidelines 2018 offer a severity-based framework to inform treatment decisions and maximize intervention time and method.[10]

PREVENTION AND MANAGEMENT

Gallbladder cholecystitis can be prevented and managed by addressing modifiable risk factors and putting urgent medicinal or surgical procedures into place. Reducing the probability of gallstone formation, the most frequent cause of cholecystitis, is the main goal of primary prevention. Maintaining a healthy weight, getting regular exercise, and eating a balanced diet devoid of processed carbs and saturated fats are all part of this. It has been demonstrated that ursodeoxycholic acid prevents gallstones in high-risk groups, such as those having bariatric surgery, fast weight loss, or long-term total parenteral care. Unless there is a substantial risk of complications (such as porcelain gallbladder or sickle cell disease), routine prophylactic cholecystectomy is generally not advised for patients with known asymptomatic gallstones.

Secondary prevention is identifying and treating biliary colic or early cholecystitis as soon as possible in order to stop the illness from getting worse. The definitive treatment, an early laparoscopic cholecystectomy, is part of management, as are antibiotics and suitable supportive care. Percutaneous cholecystostomy or endoscopic gallbladder drainage may be used in patients who are not surgical candidates. In non-surgical candidates, long-term recurrence prevention involves dietary changes and, in certain situations, long-term low-dose antibiotics,

however this strategy is debatable. A systematic, evidence-based strategy, like that described in the 2018 Tokyo Guidelines, aids in directing management and preventative tactics in accordance with the severity of the disease and the state of the patient. [1,11]

CURRENT RESEARCH AND FUTURE DIRECTIONS

The goals of present and forthcoming studies on gallbladder cholecystitis are to increase the precision of diagnosis, optimize treatment plans, and reduce complications by using individualized and least intrusive techniques. The function of biomarkers like procalcitonin and interleukin-6 in distinguishing between simple and complex cholecystitis and directing antibiotic stewardship is being investigated in recent research. The goal of imaging technology advancements, such as contrast-enhanced ultrasonography and AI-assisted radiological interpretation, is to improve severity grading and early identification. Research on non-operative management protocols for high-risk patients is still underway in the therapeutics field. One such protocol is endoscopic ultrasound-guided gallbladder drainage (EUS-GBD), which has shown potential as a percutaneous drainage substitute in some situations.

As recent trials refine the ideal window for cholecystectomy in moderate-to-severe illness, surgical scheduling remains a focus. The pathophysiology of cholecystitis is also being studied using genetic and microbiome-based research, which may provide targets for pharmacologic or preventative treatments in the future. As precision medicine develops, tailored treatment plans based on genetic, biochemical, and clinical characteristics could alleviate gallbladder disease-related medical costs and enhance results. [12,13]

TRADITIONAL PLANTS AND THEIR PHYTOCONSTITUENTS USED FOR TREATMENT OF GALLBLADDER CHOLECYSTITIS

The potential therapeutic significance of traditional medicinal herbs and their phytoconstituents in the treatment and prevention of gallbladder cholecystitis has been investigated, especially in areas with limited access to contemporary pharmaceutical or surgical treatments. Plants having choleretic, anti-inflammatory, hepatoprotective, and antibacterial qualities that are helpful in gallbladder problems have been found in a number of ethnobotanical investigations. [14,15]

Table 1: Traditional Plants and its Phytoconstituents Used For Treatment Of Gallbladder Cholecystitis

Plant Name	Key Phytoconstituents	Pharmacological Actions	Relevance to Cholecystitis
***Curcuma longa* (Turmeric)**	Curcumin	Anti-inflammatory, antioxidant, choleretic	Enhances bile flow, reduces gallbladder inflammation
Phyllanthus niruri	Phyllanthin, Hypophyllanthin	Hepatoprotective, anti-lithogenic	Prevents gallstone formation, supports bile balance
***Cichorium intybus* (Chicory)**	Inulin, Esculetin	Choleretic, anti-inflammatory	Stimulates bile production, protects gallbladder mucosa
***Silybum marianum* (Milk thistle)**	Silymarin	Hepatoprotective, antioxidant	Improves liver and bile function, reduces oxidative stress
***Mentha piperita* (Peppermint)**	Menthol, Flavonoids	Spasmolytic, choleretic	Relieves biliary colic, enhances bile secretion
Picrorhiza kurroa	Kutkin (Picroside I & II)	Hepatoprotective, anti-inflammatory	Supports liver detox, prevents bile sludge accumulation

CONCLUSION

A common and clinically important illness, gallbladder cholecystitis is mostly caused by inflammation and blockage brought on by gallstones. For efficient treatment, a timely diagnosis made by clinical evaluation, laboratory testing, and imaging especially ultrasound and HIDA scans is essential. The gold standard for treatment is still an early laparoscopic cholecystectomy; however, non-surgical methods like endoscopic and percutaneous draining are useful substitutes for high-risk individuals. Dietary and lifestyle changes are examples of prevention techniques that are crucial for lowering the incidence of disease. Although further clinical studies are necessary to determine their efficiency and safety, traditional medicinal plants, which are abundant in choleretic and anti-inflammatory phytoconstituents, offer intriguing supplementary advantages. Future management paradigms could be altered by new research in biomarkers, AI-assisted diagnostics, and customized therapy approaches. For gallbladder cholecystitis, a multidisciplinary, patient-centered approach based on growing evidence is essential to improving results.

REFERENCES

1. Yokoe M, Hata J, Takada T, *et al*., Tokyo Guidelines 2018: diagnostic criteria and severity grading of acute cholecystitis (with videos). *J Hepatobiliary Pancreat Sci*. 2018 Jan;25(1):41–54.
2. Beltran MA. Historical review of gallbladder disease: from antiquity to the 21st century. *World J Surg*. 2021;45(7):1962–1971.
3. Indar AA, Beckingham IJ. Acute cholecystitis. *BMJ*. 2002;325(7365):639–643.
4. Shaffer EA. Gallstone disease: epidemiology of gallbladder stone disease. *Best Pract Res Clin Gastroenterol*. 2006;20(6):981–996.
5. Baron TH, Morgan DE. Acute cholecystitis. *N Engl J Med*. 1999 Jun 24;340(25):1976–1982.
6. Strasberg SM. Clinical practice. Acute calculous cholecystitis. *N Engl J Med*. 2008 May 22;358(24):2804–2811.
7. Singer AJ, McCracken G, *et al*., Correlation among clinical, laboratory, and hepatobiliary scanning findings in patients with suspected acute cholecystitis. *Ann Emerg Med*. 1996 Feb;27(2):182–188.
8. Shea JA, Berlin JA, Escarce JJ, *et al*., Revised estimates of diagnostic test sensitivity and specificity in suspected biliary tract disease. *Arch Intern Med*. 1994 Apr 11;154(22):2573–2581.
9. Ambe PC, Köhler L. Diagnostic approach for gallbladder diseases: a review of the literature. *Gastroenterol Res Pract*. 2014;2014:162514.
10. Gutt CN, Encke J, Köninger J, *et al*., Acute cholecystitis: early versus delayed cholecystectomy, a multicenter randomized trial (ACDC study, NCT00447304). *Ann Surg*. 2013 Sep;258(3):385–393.
11. Portincasa P, Moschetta A, Petruzzelli M, *et al*., Gallstone disease: symptoms and diagnosis of gallbladder stones. *Best Pract Res Clin Gastroenterol*. 2006;20(6):1017–1029.
12. Teoh AYB, Kitano S, Itoi T, *et al*., Endosonography-guided gallbladder drainage: a new era in the management of acute cholecystitis. *Gut Liver*. 2020 May;14(3):329–336.
13. Elsharawy MA, Reda IS, *et al*.,Role of biomarkers in assessing severity and guiding management in acute cholecystitis: a prospective study. *Ann Hepatobiliary Pancreat Surg*. 2022 Aug;26(3):270–277.
14. Sharma A, Chakraborti KK, Handa SS. Anti-hepatotoxic activity of some Indian herbal formulations as compared to silymarin. *Fitoterapia*. 1991;62(3):229–235.
15. Gilani AH, Janbaz KH, Zaman M. Effect of *Curcuma longa* on acetaminophen- and CCl_4-induced hepatotoxicity in mice. *Phytother Res*. 1998 Aug;12(5):392–395.