International Journal of Allied Medical Sciences and Clinical Research (IJAMSCR)

ISSN: 2347-6567

IJAMSCR |Volume 3 | Issue 2 | April-June- 2015
www.ijamscr.com

Case report *Medical research*

Case report and review of literature: Subdeltoid bursa tuberculosis with rice bodies formation

Ashwin Kasturi[1], Swetha Madas[2], Natesh K[3], Srinivasan N[4]

[1]*Associate professor, Dept. of Orthopedics, Malla Reddy Institute of Medical Sciences (MRIMS), Hyderabad, India.*

[2]*Assistant professor, Dept. of TB & Chest, MRIMS, Hyderabad, India.*

[3]*Assistant Professor, Dept of Orthopedics, MRIMS, Hyderabad, India.*

[4]*Professor & HOD, Dept of Orthopedics, MRIMS, Hyderabad, India.*

***Corresponding author: Ashwin Kasturi**

ABSTRACT

Introduction: We describe a rare case of a patient with unilateral musculoskeletal manifestation of tuberculosis presented as bursitis of the left shoulder with rice bodies, without coexisting active tuberculosis or tuberculosis in the previous history.

Case report: A 23 year old patient was examined, who complained of pain and swelling in the left shoulder for 2 years. MRI showed a large amount of rice bodies with joint effusion in the left shoulder with intact rotator cuff. The histological examination showed a tuberculosis-specific inflammatory response with giant cells and epithelioid granulomas. Arthroscopic debridement and removal of the loose bodies was done.

Conclusion: We report a unique case of tuberculosis sub deltoid bursitis with rice bodies formation in absence of any other concomitant focus of tuberculosis infection, managed with arthroscopic debridement and anti – tuberculosis treatment (ATT) regimen for twelve months, with a long follow up of nine months.

Key words: Sub deltoid Bursitis, Rice bodies, Arthroscopy

INTRODUCTION

Rice body formation is commonly observed in the joint and tendon sheaths among patients with rheumatoid arthritis[1,2], however only a few cases with rice bodies in sub-deltoid bursa of tubercular origin have been mentioned in the literature[3,4]. There are very few reports[5] about the arthroscopic management of cases with rice bodies in sub deltoid bursa with a long term follow up. The authors report the rare case of a patient with musculoskeletal manifestation of tuberculosis presented as bursitis of the left shoulder with rice bodies without coexisting active tuberculosis or tuberculosis in the previous history managed with arthroscopic debridement with follow up of one year.

CASE REPORT

A 23 years young male with 2 years history of diffuse swelling of left shoulder was examined (Non dominant side) .He was an athlete .Pain was gradual in onset. The pain was not aggravated by activities of daily living but terminal rotations were painful. . There was no history of constitutional symptoms.

There was no history of tuberculosis or any other major illness in the past. He was afebrile with vital parameter within normal limits. There were no signs of acute or chronic inflammation. There was diffuse swelling over the shoulder. No point tenderness was elicited. External and internal rotations of the shoulder were terminally restricted. The WBC count was 7,800/cmm. With lymphocytes being 39%, His ESR (Erythrocyte Sedimentation Rate) was raised (68mm). C-reactive protein study was positive. Rheumatoid factor and HIV studies were negative. Radiograph showed no abnormality of the humeral head. Chest x-ray did not show any evidence of healed primary lesion. Magnetic resonance imaging (MRI) scans (Fig 1&2) showed moderate joint effusion with multiple loose bodies on T2 weighted image & signal changes of humeral head near the synovial reflection along posterior aspect. The T1 weighted images showed homogenous images. The patient underwent arthroscopic debridement (Fig 3) for removal of loose bodies some of which were attached to the synovium. The loose bodies resembled rice bodies ranging from 3 to 10 mm length (Fig 4).

Histo-pathological analysis confirmed caseous necrosis and Ziehl-Neelson staining of the fluid from the bursa isolated mycobacterium tuberculosis. Microscopically they consisted of compact fibronous material. However the articular cartilage did not show evidence of tuberculosis.

The patient was treated with anti-tuberculosis treatment (ATT) medication for 12 months and he is disease free for the last 9 months after completion of ATT.

DISCUSSION

The formation of intra-articular rice bodies was first described in tuberculous arthritis. These nodules are a common finding in rheumatoid bursitis and arthritis; they are rare in other arthropathies[6]. The pathogenesis of these rice bodies remains obscure. The main theories depict the origin of the rice bodies from the synovial fluid due to aggregation of the fibronectin /fibrin[7]. A different theory proposes them to be of the synovial origin. The underlying disease condition leads to microinfraction of the synovium which progresses to sloughing, and then the fibrin covering the infracted tissue as described by Cheung[8]. The MRI findings in our patient revealed the rice bodies as intermediate intensity images on the T1 and T2 weighted images. They were better delineated on the T2 weighted images than T1 weighted images, on which they appeared homogenous. On arthroscopy they seemed attached to the synovial lining supporting the description of their origin by Cheung. Macroscopically they appeared similar to the rice bodies arising in rheumatoid arthritis. On microscopic analysis they were composed of fibrous tissue. Tuberculous bursitis is always descried secondary to some other primary focus of infection in the bone or the nearby joint[9]. Tuberculosis involvement has been described in the superficially situated bursa such as the olecranon and the pre-patellar bursa[10,12.] History of trauma and direct transmission has been thought as the underlying cause. Hematogenous spread is proposed as the cause of deep seated bursa involvement[13]. For the hematogenous spread to occur there should be a primary focus of infection or a healed primary lesion in the lungs. In our patient there was no history of trauma and the chest x ray did not show any focus of infection. So far very few studies have been published on sub-deltoid bursitis and its arthroscopic management with a long term follows up. Jaovisidha et al[4] has published a case series of 3 cases with sub deltoid bursitis. Alkalay et al[3] has reported a case of patient with 30 year history of tuberculous subdeltoid bursitis. Kim et al[5] reported a case with subdeltoid bursitis in a 41 year old woman.

CONCLUSION

We report a unique case of tuberculosis sub deltoid bursitis with rice body formation in absence of any other concomitant focus of tuberculous infection, managed with arthroscopic debridement and anti - tuberculosis regimen of twelve months, with a long follow up nine months after completion of ATT

CLINICAL MESSAGE

Possibility of tuberculosis of subdeltoid bursa in absence of a primary focus should be ruled out.

FIGURES

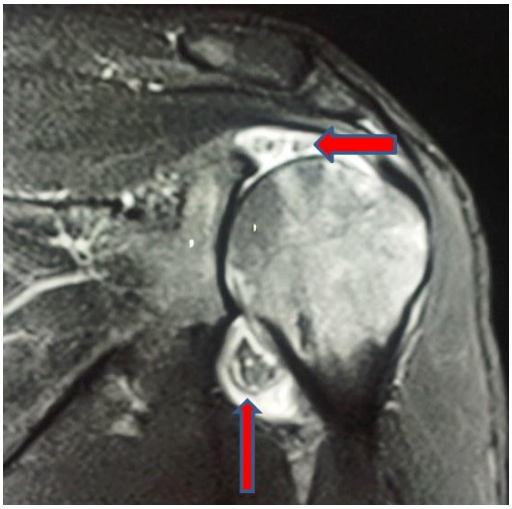

Figure 1:T2 fat suppressed coronal image showing intermediate intensity multiple rice bodies.

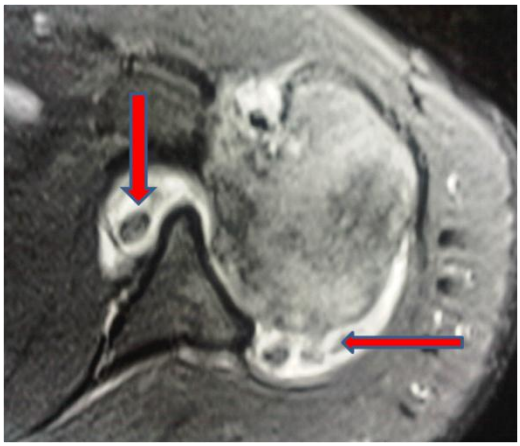

Figure 2:T2 fat suppressed axial image showing intermediate intensity multiple rice bodies.

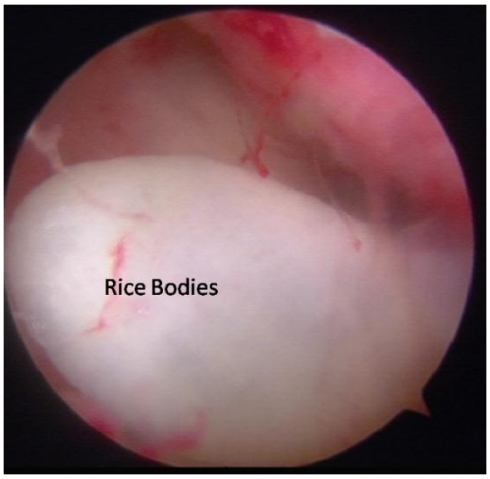

Figure 3: Arthroscopic Image of Subdeltoid Rice Bodies

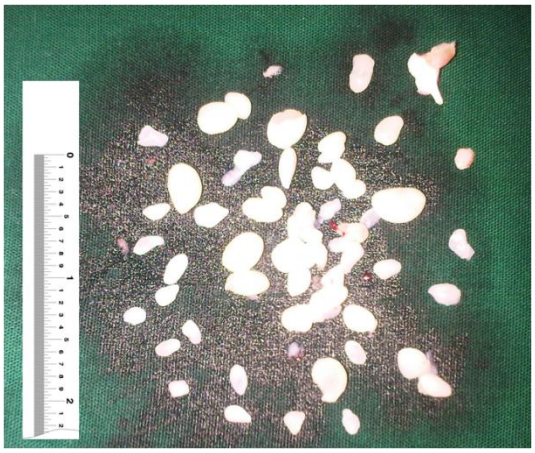

Figure 4: Rice Bodies gross anatomical presentation.

REFERENCES

[1] Hiroyuki Nagasawa, et al Tenosynovitis with rice body formation in a non-tuberculosis patient: A case report Ups J Med Sci. 2009 September; 114(3): 184–188.

[2] Karthikeyan Iyengar ,et al Bilateral recurrent wrist flexor tenosynovitis and rice body formation in a patient with sero-negative rheumatoid arthritis: A case report and review of literature Int J Surg Case Rep. 2011; 2(7): 208–211.

[3] Alkalay I, Kaufman T suprum H. Tuberculousis of the subdeltoid bursa Acase report Isr j Med Sci 1980;16:853-5

[4] Jaovisidha S, Chen C, Ryu KN, Siriwong- pairat P, Pekanan P, Sartoris DJ, et. al *Tuberculous tenosynovitis* and bursitis: imaging findings in 21 cases. Radiology 1996; 201:507-13
[5] Kim et al Tuberculous subdeltoid Bursitis with rice bodies. Yonsei Medical Journal 2002; 43; 539-42
[6] Poper J. Rice – Bodies, Synovial Debris, and joint Lavage. BR. J Rheumatol 1985; 24:1-2
[7] Poper AJ, Scott DL, Wainwright AC, Walton KW, Williamson N, Chapman JH. Frequency of occurrence mode of develop. And signi- ficance of rice bodies in rheumatoid jt. Ann Rheum Dis 1982;41:109-17
[8] Cheung HS, Ryan LM. Kozin F, McCarty DJ, Synovial origins of rice bodies in joint, fluid Arthritis Rheum 1980; 23:72-6
[9] WattsHG, Lifeso RM. Tuberculosis of bone and joints. J Bone Joint Surg Am 1996; 78:288-98
[10] Dawson DJ, Blacklock ZM, Ashdown LR. Bittger EC. *Mycobacterium Asiaticum* as the probale causative agent in a case of *Olecranon bursiti*s. J.lin Microbiol 1995; 33:1042-3
[11] Holder SF, Hopson CN,Vonkuster LC. tuberculous arthritis of the elbow presenting as chronic bursitis of the olecranon . A case report. J Bone Joint Surg AM 1985; 67:1127-9
[12] Schickendantz MS, Watson JT, *Mycobacterial prepatellar bursitis*. Clin Orthop 1990:258:209-12
[13] Ihara K, Toyada K, Ofuji A, Kawai S, Tuber- culous bursitis of the greater trochanter. J Orthop Sci, 1998; 3:120-4

How to cite this article: Ashwin K, Swetha M, Natesh K, Srinivasan N. Case report, and review of literature: Subdeltoid bursa tuberculosis with rice bodies formation. Int J of Allied Med Sci and Clin Res 2015;3(2):224-227.