International Journal of Allied Medical Sciences and Clinical Research (IJAMSCR)
IJAMSCR |Vol.13 | Issue 2| Apr - Jun -2025
www.ijamscr.com
ISSN: 2347-6567
DOI : https://doi.org/10.61096/ijamscr.v13.iss2.2025.280-296

Research

Evaluation of the safety and performance of the HeartTouch™ Electrophysiology Mapping Catheter and NaviBlaze™ Electrophysiology Ablation Catheter in a porcine model

Minocha Dr. Pramodkumar, Kothwala Dr. Deveshkumar, Pandya Kamna, *Shinde Divya, Dave Arpit, Patel Milan

Meril Medical Innovations Private Limited, Bilakhia House, Survey no.879, Muktanand marg, Chala, Vapi, Dist-Valsad, Gujarat, 396191, India.

*Author for Correspondence: Shinde Divya
Email: divya.shinde@merillife.com

Published on: 06 Jun 2025

Published by:
DrSriram Publications

2025| All rights reserved.
Creative Commons Attribution 4.0 International License.

Abstract

The objective of this study was to evaluate the safety and performance of the HeartTouch™ Electrophysiology Mapping Catheter and NaviBlaze™ Electrophysiology Ablation Catheter in various heart chambers (right atrium, right ventricle, left atrium, and pulmonary veins) in a porcine model. The study utilized two female pigs. The procedures were carried out under anesthesia with standard percutaneous access through the 7F sheath which was inserted into the internal jugular vein, two sheaths of 8F into the right femoral vein and one 5F sheath into the left femoral artery. The study involved multiple runs of mapping and ablation catheter tests to assess both mapping accuracy and lesion effectiveness. Mapping catheter testing demonstrated successful navigation and signal recording across various heart chambers, confirming the efficacy of device in identifying electrophysiological landmarks. Ablation catheter testing involved both non-irrigated and irrigated catheters, resulting in significant impedance reductions at target sites, confirming effective tissue interaction and lesion creation. Necropsy images revealed visible ablation lesions, further corroborating the catheter's effectiveness. No morbidity or mortality was observed in the animals, and clinical signs remained normal throughout the study. The findings suggest that both the HeartTouch™ Mapping Catheter and NaviBlaze™ Ablation Catheter are effective tools for precise mapping and targeted ablation, supporting their potential for clinical use in treating arrhythmias and advancing electrophysiological research.

Keywords: Cardiac electrophysiology, Impedance measurements, Porcine model, Transthoracic echocardiography (TTE), Cavo-tricuspid isthmus, Crista terminalis, Seldinger technique.

INTRODUCTION

The HeartTouch™ Electrophysiology Mapping Catheter and NaviBlaze™ Electrophysiology Ablation Catheter are advanced medical devices designed for the mapping and ablation of cardiac arrhythmias. This study

aimed to evaluate the safety and performance of these devices in different heart chambers [(right atrium (RA), right ventricle (RV), left atrium (LA) and pulmonary veins (PV)] using a porcine model.

The HeartTouch™ Electrophysiology Mapping Catheter, are fixed and flexible insulated catheters; constructed of thermoplastic elastomer material and noble metal electrodes. The catheters comprises of a high torque shaft along with fixed/deflectable tip section containing an array of platinum electrodes that can be used for stimulation and recording. The tip of the steerable catheters may be manipulated with the control mechanism located in the handle at the proximal end of the catheter. It can be used for recording intra-cardiac signals and for cardiac stimulation during electrophysiology studies or to map the atrial regions of heart and coronary sinus. These electrodes consist of different curves with different electrodes spacing and sizes.

The NaviBlaze™ Electrophysiology Ablation Catheter is a sterile, single use catheter and has a usable length of 110 cm. Electrophysiology Ablation Catheter is constructed of thermoplastic elastomer material and noble metal electrodes. This catheter has a novel flexible tip electrode. It has a lumen connected to open conduits at the tip electrode (for irrigated catheter) and the interlocking grooves on the flexible tip electrode for saline irrigation during the ablation procedure. The tip curvature may be manipulated by the steerable mechanism located on the handle at the proximal end of the catheter. The catheter connects to the RF Generator via a connecting cable and also connects to Irrigation Pup (for irrigated catheter). The catheter measures temperature at locations via Thermocouple/ Thermistor Sensor.

The goal of the study was to assess the effectiveness of these catheters in mapping and ablating various cardiac substrates by recording impedance changes and electrogram signals in multiple heart chambers. The evaluation involved a series of tests using a percutaneous approach, guided by fluoroscopy, and supplemented by Transthoracic Echocardiography (TTE) for visualization. The HeartTouch™ Mapping Catheter was used to map electrophysiological characteristics, while the NaviBlaze™ Ablation Catheter was employed to create lesions at targeted sites, with impedance measurements indicating the success of tissue interaction and lesion formation.
Overall, the findings provided valuable insights into the performance of both catheters, demonstrating their ability to effectively navigate the heart chambers, create targeted lesions, and generate consistent impedance changes, which are essential for the treatment of arrhythmias. These results offer promising implications for future clinical applications and advancements in electrophysiology.

MATERIALS AND METHODS

MEDICATION DETAILS

The drugs administered to the animal pre-operative and intra-operative were recorded in the raw data and described in Table no. 1 below,

Table 1: Details of medications used during the study

Sr. No.	Drug Name	Manufactured by	Batch/Slot No.	Expiry Date
1.	Ketamine	Themis Medicare Ltd	KME23011	Jun. 2026
2.	Xylazine	IIL India	FHK 1005	Oct. 2024
3.	Isoflurane	Neon Laboratory Ltd	KPNP700029	Sep. 2027
4.	Tramadol	Neon Lab	KP949131	Nov. 2024
5.	Atropine Sulphate	Pentagon Labs Ltd	23GAS002	Jun 2026

MATERIALS REQUIRED

For Ablation Catheter

- Ablation Tip
- Temperature Sensor
- Distal Tube (Multi-Lumen Braided)
- Proximal Tube (Single Lumen Braided)
- Electrode Bands
- Handle
- Signal Wire
- Pull Wire
- Spring Coil
- Di-electric Tube
- Extension Cable
- Connector

For Mapping Catheter

- Distal Tube (Multi-Lumen Braided)
- Proximal Tube (Single-Lumen Braided)
- Electrode Bands
- Electrode Tip
- Handle
- Signal Wire
- Pull Wire
- Spring Coil
- Di-Electric Tube
- Extension Cable
- Connector

Device design

HeartTouch™ Electrophysiology Mapping Catheter

The HeartTouch™ Electrophysiology Quadripolar Fixed Curve Mapping Catheter is designed for electrophysiological mapping of cardiac structures. It is used specifically for simulation and recording purposes, allowing for precise mapping of the heart's electrical pathways. The device should be stored at a temperature between 18-28°C. The contact duration of the catheter is limited (≤24 hours). The catheter configuration includes:

- Quadripolar Fixed Curve (N=1)
- Decapolar Mapping Catheter (N=1)
- Duo-Decapolar Mapping Catheter (N=1)
- PV Decapolar Mapping Catheter (N=1)
- PV Duo-Decapolar Mapping Catheter (N=1)

The HeartTouch™ Mapping Catheter features a slim, flexible design with an elongated shaft that ensures easy navigation through the heart's chambers. The distal end of the catheter is equipped with multiple electrodes arranged in a circular configuration to facilitate precise electrical mapping. The catheter is constructed from PEBAX material for enhanced flexibility and durability. The handle includes controls for steering and positioning, providing accurate maneuverability during procedures. Thickness of the catheter is more than 1mm (>1.0 mm). To ensure the safety of personnel, protective gloves, face masks, aprons/protective suits and goggles were used during the handling and testing of the device. The sponsor is responsible for the identity and stability of the test item. No specific stability analysis was conducted at the lab.

NaviBlaze™ Electrophysiology Ablation Catheter

The NaviBlaze™ Ablation Catheter is designed for catheter ablation therapy to treat irregular heartbeats (arrhythmias) such as atrial fibrillation (AFib), atrial flutter and supraventricular tachycardia (SVT). The catheter delivers targeted energy to destroy the tissue causing abnormal heart rhythms, thereby creating scar tissue that prevents further electrical disturbances and helps the heart maintain a regular rhythm. The device should be stored at a temperature between 18-28°C. The contact duration of the catheter is Limited (≤24 hours). The catheter configurations include:

- Irrigated Ablation Catheter (N=1)
- Non-Irrigated Unidirectional Ablation Catheter (N=1)

The NaviBlaze™ Ablation Catheter features a sleek, flexible shaft designed for precise navigation within the heart. It is equipped with a platinum-iridium tip that delivers targeted energy for tissue ablation. The catheter also includes a temperature sensor to monitor the tissue temperature during ablation, ensuring safe and effective treatment. Multiple electrodes are located at the distal end of the catheter for efficient tissue ablation. The catheter is typically made from PEBAX material, which provides a smooth surface that reduces tissue irritation during the procedure. The handle is designed for easy maneuverability and accurate positioning during use. To ensure the health and safety of personnel, protective gloves, face masks, aprons/protective suits and goggles were used during the handling and testing of the device. The sponsor is responsible for ensuring the identity and stability of both the test item and reference item. No analysis was performed to confirm the stability of the test item.

Size matrix

Table 2: Size Matrix of Mapping Catheter

Sr. No.	Product Name	French Size	Length	Spacing	No. of Electrodes
1.	Fixed Curve Mapping Catheter	6F	1200	5/10/2-5-2/ 2-8-2	2,4
2.	Steerable Decapolar Mapping Catheter	6F, 7F	1100	2-5-2/2-8-2	10
3.	Steerable PV Mapping Catheter	7F	1100	3-3-3/4-4-4/ 5-5-5	10/20
4.	Steerable Duo-decapolar Mapping Catheter	6F	1100	2-5-2/5/ 2-8-2	20
5.	4-3.3Fr Fixed Curve Mapping Catheter	4-3.3F	1200	2-2-2, 2-2-2, 2-8-2, 2-8-	10,20

Table 3: Size Matrix of Ablation Catheter

Sr. No.	Product Name	Size	Spacing	Tip electrode (mm)	Length
1.	Non-Irrigated Ablation Catheter	7F	2-5-2	4,8	850,1100
2.	Irrigated Ablation Catheter	7F	2-5-2	4	1100

Product image

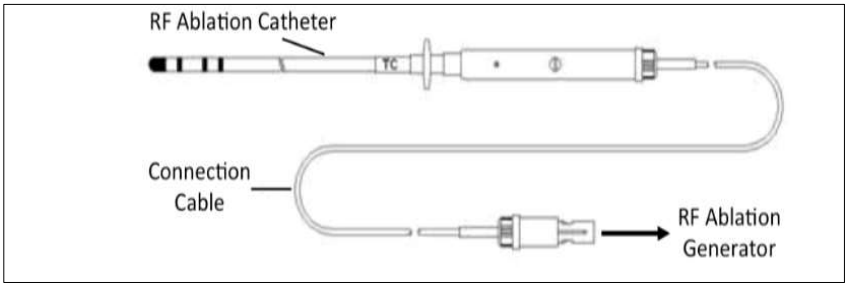

Fig 1: Schematic diagram of Ablation Catheter



Fig 2: Actual diagram of Ablation Catheter

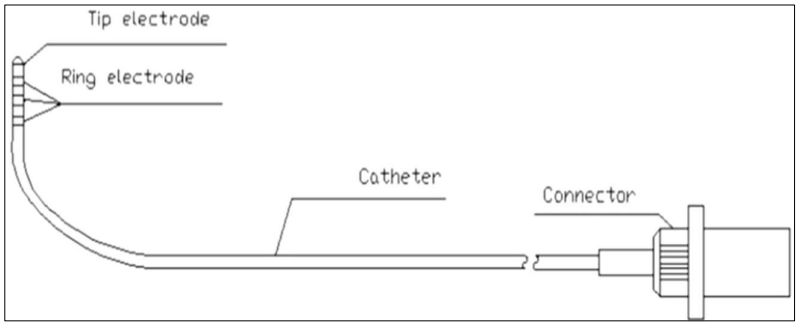

Fig 3: Schematic diagram of Mapping Catheter



Fig 4: Actual Diagram of Mapping Catheter

Device component description

Table 4: Device Component Description of Ablation and Mapping Catheter

Sr. No.	Component	Raw Materials	
		Ablation Catheter	Mapping Catheter
1.	Catheter Shaft Tube	PEBAX Braided	PEBAX Braided
2.	Electrode Bands	Pt90/Ir10	Pt90/Ir10
3.	Tip (Mapping and Ablation)	Pt90/Ir10	Pt90/Ir10
4.	Handle	ABS Moulding	ABS Moulding
5.	Pull Wire	Stainless Steel 304V	Stainless Steel 304V
6.	Spring Coil	Stainless Steel 316L	Stainless Steel 316L
7.	Connector	Sulfone PPSU Thermoplastic material	Sulfone PPSU Thermoplastic material

Experimental procedure

Fasting

The animals were fasted overnight prior to the procedure, with free access to water provided ad libitum.

Animal Preparation

The animal was weighed and anesthetized with a pre-anesthetic regimen consisting of Atropine (0.5 mg/kg, IM), Ketamine (15 mg/kg, IM), and Xylazine (2.5 mg/kg, IM). Following the intramuscular injections, inhalation anesthesia was administered at a concentration of 1-3% via a facemask. For analgesia, Tramadol (4 mg/kg, IM) was given once prior to the procedure. The animal's hair was clipped from the electrode placement sites, neck, chest and bilateral groin areas. After verifying the absence of glottis reflexes, the animal was intubated with an endotracheal tube for airway management. Refer the table no 5.

Table 5: Drugs given to Swine during the procedure

Sr. No.	Purpose	Drug name	Conc.	Dose	Route	Frequency
1.	Pre- anesthetic	Atropine	1 mg/mL	0.05 mg/kg	IM	Once before induction, anesthesia
2.	Induction of Anesthesia	Ketamine	50 mg/mL	15 mg/kg	IM	Once to sedate the animal
		Xylazine	23.32 mg/mL	2.5 mg/kg	IM	Once to sedate the animal
		Isoflurane	NA	1-4%	Face mask	Until intubation
3.	Maintenance of Anesthesia	Isoflurane	NA	1-3%	Inhalation via endotracheal tube	Throughout the study
4.	Analgesic	Tramadol	50 mg/mL	4 mg/kg	IM	Once before procedure

Experimental design or animal trial

The necessary preparations were completed as required for the procedure. ECG electrodes were connected to the animal's body for continuous monitoring. A percutaneous approach was performed using the Seldinger method, with the following sheaths inserted:

- A 7F sheath into the internal jugular vein
- Two 8F sheaths into the right femoral vein
- A 5F sheath into the left femoral artery

ACT Monitoring

Activated Clotting Time (ACT) was measured both pre and post-heparinization to monitor anticoagulation. Heparin was administered with the first bolus at 100 IU/kg IV and subsequent doses were titrated based on ACT readings. Heparin was maintained throughout the procedure as needed until the animal began to recover.

Animal P1: Mapping Catheter Testing

The Decapolar catheter was placed in the coronary sinus using fluoroscopy via the already-secured jugular access. Electrogram signals were recorded using the Cardiotek EP tracer.

Run1

A Quadripolar fixed curve mapping catheter was then advanced into the right atrium (RA) through one of the femoral venous accesses. Using fluoroscopy, electrogram signals were recorded from the RA, His bundle, and right ventricle (RV). Fluoroscopic images and cine recordings were captured at each landmark as the catheter moved through the heart, and the mapping catheter was parked in the inferior vena cava (IVC).

Run2

The setup was repeated with the Decapolar catheter placed again in the coronary sinus under fluoroscopic guidance, and signals were recorded on the Cardiotek EP tracer.

Run3

A transseptal puncture was performed to access the left atrium (LA). The PV-12 Mapping catheter was advanced through the Agilis sheath into the LA. Transthoracic echocardiography (TTE) was used to obtain the optimal view of the LA structures and recordings continued throughout catheter movement. Electrograms were recorded from the left pulmonary vein (PV) and LA appendage and fluoroscopic images and cine recordings were collected at each landmark.

Animal P1: Ablation Catheter Testing

- A non-irrigated unidirectional ablation catheter was placed in the right heart chamber through the femoral access. The ablation catheter was used to create lesions in the RA- crista terminalis, slow pathway region, and superior vena cava-right atrium (SVC-RA) junction.

Animal P2: Mapping Catheter Testing

The procedure mirrored Animal P1 for mapping. A Decapolar catheter was placed in the coronary sinus using fluoroscopy, and electrogram signals were recorded in the Cardiotek EP tracer.

Run1
The Quadripolar fixed curve mapping catheter was advanced into the RA via femoral venous access. Fluoroscopic images and cine recordings were captured as the mapping catheter was navigated through the RA, His bundle and right ventricle (RV). The mapping catheter was parked in the IVC.

Run2
A transseptal puncture was performed to access the LA, and the PV-12 Mapping catheter was advanced through the Agilis sheath into the LA. TTE was used for optimal LA visualization. Electrograms were recorded from the left pulmonary vein (PV) and LA appendage, and fluoroscopic images and cine recordings were collected at each landmark.

Run3
The setup was repeated with the Decapolar catheter placed in the coronary sinus under fluoroscopic guidance, and signals were recorded in the Cardiotek EP tracer.

Animal P2: Ablation Catheter Testing
An irrigated unidirectional ablation catheter was placed in the right heart chamber through the femoral access. The ablation catheter was used to create lesions in the RA crista terminalis, slow pathway region, and cavo-tricuspid isthmus.
This series of mapping and ablation tests on Animal P1 and Animal P2 provided valuable data regarding catheter performance and efficacy in creating precise lesions, which is critical for the clinical treatment of arrhythmias.

Observation and results

Body Weight: The body weights of the animals were recorded at the start of the acclimatization period and again on Day 0. On Day 0, the body weight of Animal P1 was 55.2 kg**,** while Animal P2 weighed 44.4 kg as shown in table no. 6

Table 6: Body weight of animal

Sr. No.	Animal Number	Acclimatization start day	Day 0
1.	P1	55.1 kg	55.2 kg
2.	P2	44.3 kg	44.4 kg

Morbidity and Mortality: No morbidity or mortality was observed in the animals during the acclimatization period or on Day 0 as given in table no. 7.

Table 7: Morbidity and Mortality Study

Sr. No.	Animal Number	Acclimatization Phase		Experiment Phase	
		01(07487)	02(07490)	P1	P2
1.	Sex	Female	Female	Female	Female
2.	Day of Observations	Mortality/ Incidences		Mortality/ Incidences	
3.	Acclimatization Phase (Day-3 to -1)	0/2		-	
4.	Experiment Phase (Day 0)	-		0/2	

Clinical Signs: The animals were closely monitored for any adverse clinical signs and cage-side observations for illness or health deviations during the acclimatization period and on Day 0. Throughout the study, the animals exhibited normal food and water intake, as well as regular urine and fecal output. They were observed to be bright, alert and responsive, showing no deviations from normal behavior, posture, movement, or skin condition; shown in table no. 8,

Table 8: Clinical Signs observed in animals

Sr. No	Animal Number	Acclimatization Phase		Experiment Phase	
		01(07487)	02(07490)	P1	P2
1.	Sex	Female	Female	Female	Female
2.	Day of Observations	Clinical Signs		Clinical Signs	
3.	Acclimatization Phase (Day-3 to -1)	Normal		Normal	

4.	Experiment Phase (Day 0)	Normal	Normal

Monitoring of animal during procedure: The animals were closely monitored during the procedure and throughout the recovery period for ECG, SpO_2, blood pressure and respiratory rate

Radiography and angiographic study

Radiofrequency generator's requirement: Ablation Catheter

- Frequency: 450-575 kHz
- Voltage: 0-220 V
- Current: 0-2.0 A
- Power: 100-150 W (max.)
- Rated accessory voltage: 250 Volt (60-100 Volts)
- Accessory Current: 0.2 – 0.6A
- Impedance cut-off limit: Upper limit:-300 Ohm;
- Lower Limit: 25 Ohm

Pathology

Blood samples were collected on Day 0 at baseline (prior to the procedure) and after the procedure (post-procedure) for analysis of hematology and biochemistry parameters. Hematology testing included a complete and differential blood count with reticulocyte measurement while clinical biochemistry assessments measured albumin, ALP, ALT, AST, LDH, calcium, chloride, cholesterol, creatinine, GGT, glucose, inorganic phosphorus, potassium, sodium, total bilirubin, total protein, triglycerides and BUN. Both the baseline and post-procedure hematology and clinical biochemistry values were within normal reference ranges, with no abnormalities observed.

Table 9: Individual animal data of clinical chemistry (Day 0)

Animal No.	P1		P2	
	Day 0		Day 0	
	Baseline	Terminal	Baseline	Terminal
ALB (g/L)	25.2	24.0	19.8	21.0
ALP (U/L)	219	199	131	138
ALT (U/L)	23	24	24	23
AST (U/L)	30	28	93	75
Ca (mmol/L)	2.62	2.44	2.26	2.46
CK (U/L)	517	653	673	965
Creatinine (µmol/L)	101	80	182	177
GGT (U/L)	81	42	54	32
Glucose (mmol/L)	2.93	3.37	3.20	2.66
Chol	0.72	0.70	0.80	0.86
Pi (mmol/L)	2.36	2.87	1.84	2.63
LDH (U/L)	484	328	436	392
T. Bil (µmol/L)	2.97	3.22	2.47	3.03
T. Pro (g/L)	61.7	60.2	59.3	63.9
Triglyceride (mmol/L)	0.39	0.28	0.63	0.31
BUN (mmol/L)	6.33	5.38	16.11	15.86
GLOB (g/l)	36.5	36.2	39.5	42.9
A/G	0.69	0.66	0.50	0.49
Sodium (mmol/L)	142.6	139.6	134.4	104.4
Potassium (mmol/L)	3.51	4.07	3.71	3.88
Chloride (mmol/L)	117.0	114.4	109.8	113.8

Table 10: Individual animal data of Hematology parameter

Animal No.	P1		P2	
	Day 0		Day 0	
	Baseline	Terminal	Baseline	Terminal
WBC (10^9/L)	14.38	15.61	19.8	21.0

RBC (10^{12}/L)	4.42	4.30	131	138
HGB (g/L)	79	77	24	23
HCT (L/L)	0.259	0.259	93	75
MCV (fL)	58.7	60.3	2.26	2.46
MCH (pg)	17.9	17.9	673	965
MCHC (g/L)	305	298	182	177
RDW (%)	16.6	16.3	54	32
HDW (g/L)	18.5	18.6	3.20	2.66
PLT (10^9/L)	295	53	0.80	0.86
MPV (FL)	10.1	13.4	1.84	2.63
NEUT (%)	39.4	70.7	436	392
LYM (%)	52.9	26.0	2.47	3.03
MONO (%)	5.3	1.8	59.3	63.9
EOS (%)	0.7	1.0	0.63	0.31
LUC (%)	1.3	0.3	16.11	15.86
BASO (%)	0.3	0.2	39.5	42.9
Retic (%)	1.76	1.93	0.50	0.49

Fluoroscopic images

Animal P1

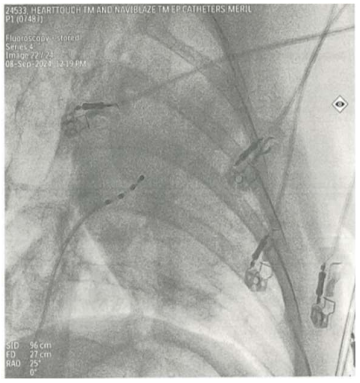	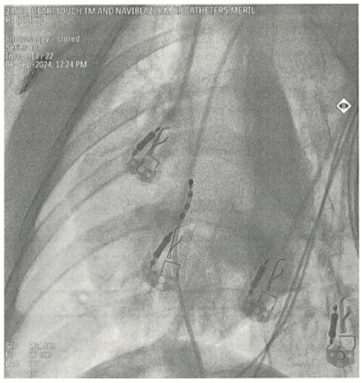	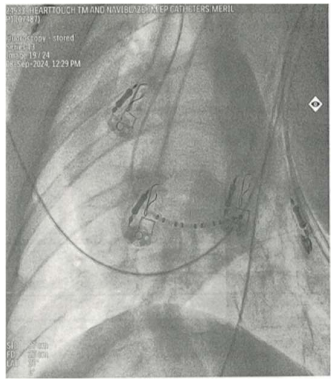
Mapping catheter at the crista terminal	Mapping catheter at the crista terminal	Mapping catheter in the coronary sinus
	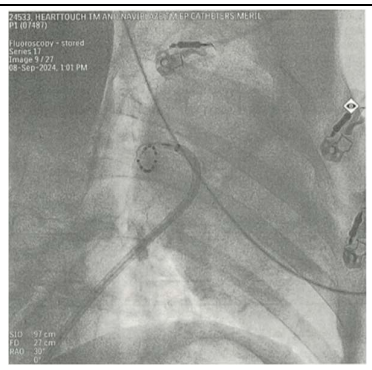	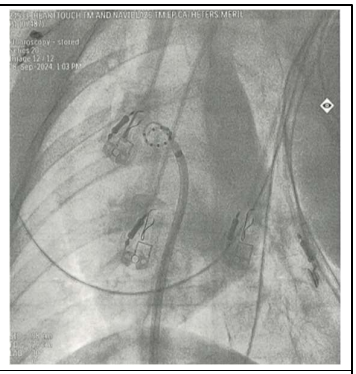
Mapping catheter in the left atrial appendage	Mapping catheter in the left atrial appendage	Mapping catheter in the left atrium

		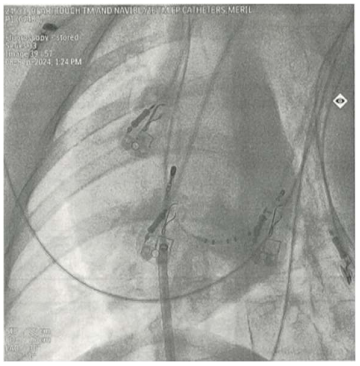
Mapping catheter in the left atrium	Mapping catheter at the slow pathway region	Mapping catheter at the slow pathway region

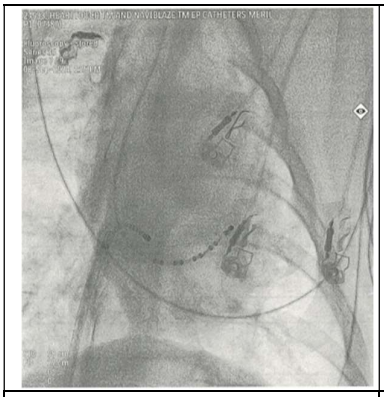	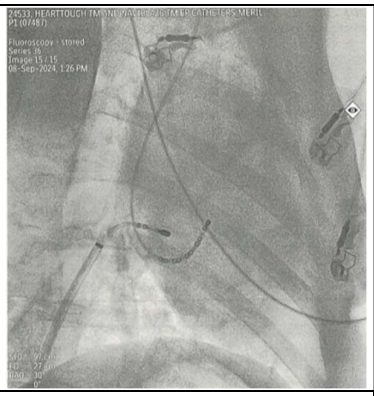	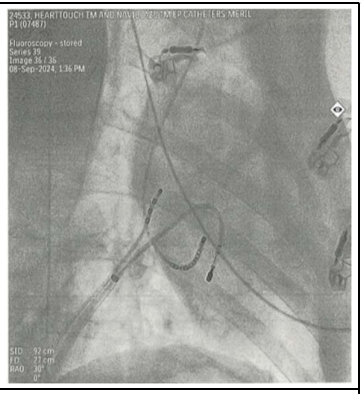
Mapping catheters at the cavo tricuspid isthmus and coronary sinus	Mapping catheters at the cavo tricuspid isthmus and coronary sinus	Mapping catheters at the cavo tricuspid isthmus, right atrium and right ventricle

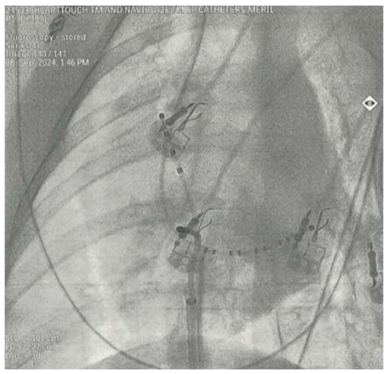	
Mapping catheters at the cavo tricuspid isthmus, coronary sinus and right atrium	Mapping catheters at the cavo tricuspid isthmus, inferior vena cava and superior vena cava junction

Animal P2

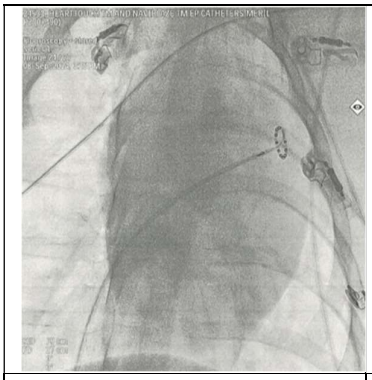	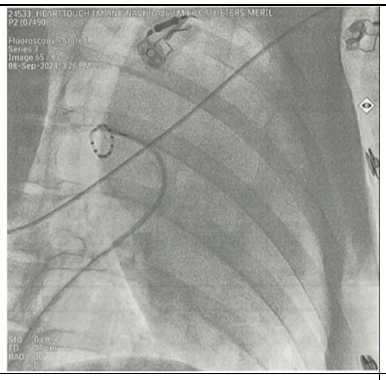	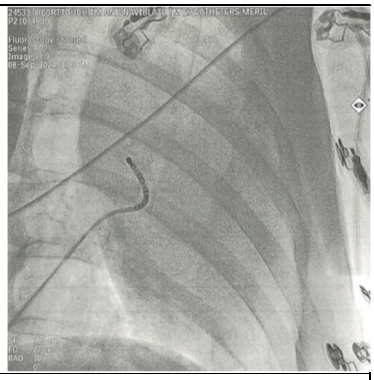
Mapping catheter in the left atrium appendage	Mapping catheter at the right supra pulmonary vein	Mapping catheter in the right atrium

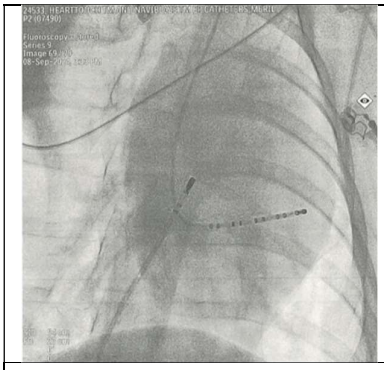	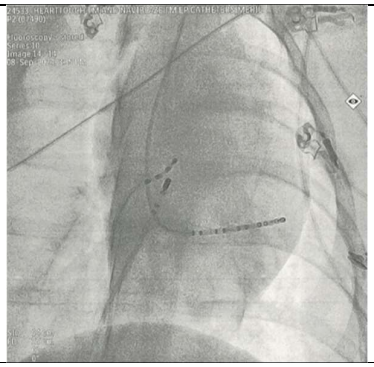	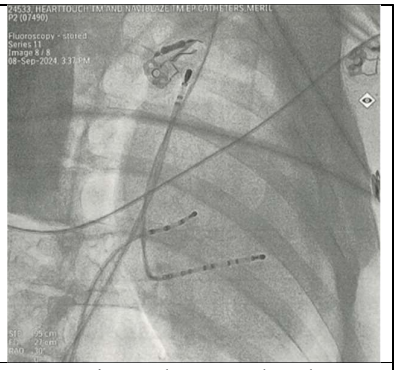
Mapping catheters at the crista and coronary sinus	Mapping catheters at the crista, slow pathway and coronary sinus	Mapping catheters at the slow pathway, coronary sinus and SVC and RA junction

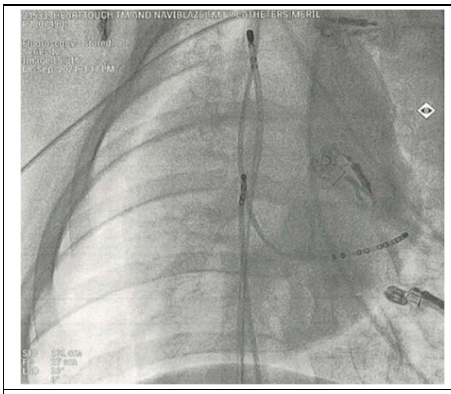	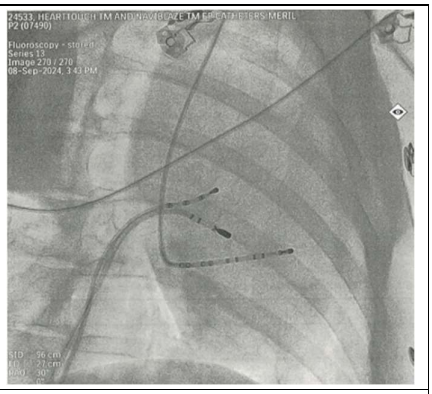
Mapping catheters at the slow pathway, coronary sinus and SVC and RA junction	Mapping catheters at the slow pathway, coronary sinus and cavo-tricuspid isthmus

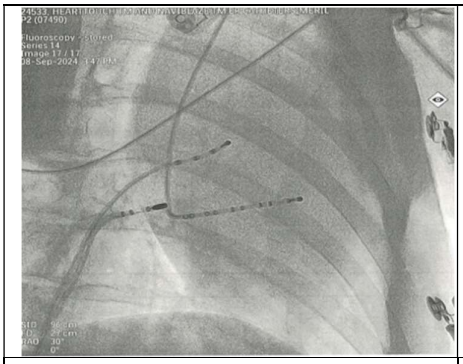	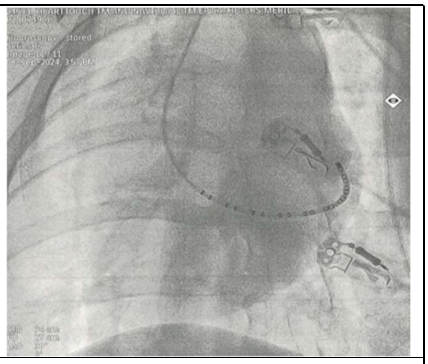
Mapping catheters at the slow pathway, coronary sinus and SVC junction	Mapping catheter in the coronary sinus

Fig 5: Fluoroscopic images of Animal P1 and P2

Echo Cardiography Images

Animal P1

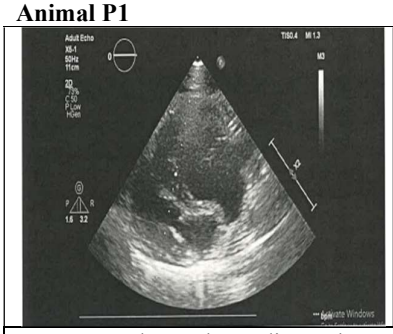	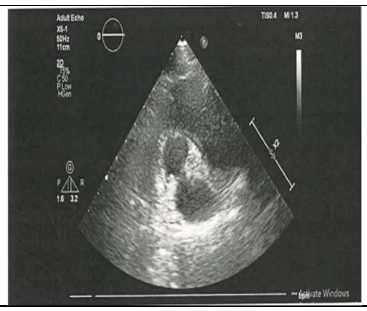	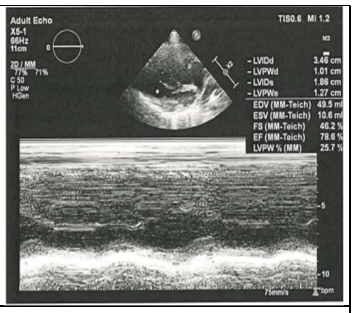
Pre-procedure echocardiography showed normal functioning of the four chambers, with no pericardial effusion observed	Pre-procedure echocardiography showed normal functioning of the four chambers, with no pericardial effusion observed	The Pre-procedure echocardiography showed that the ejection fraction was normal

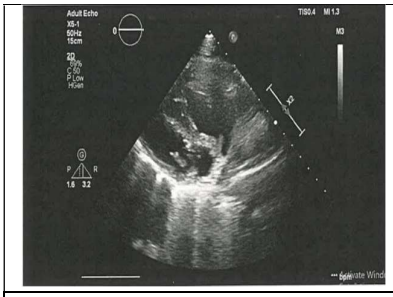	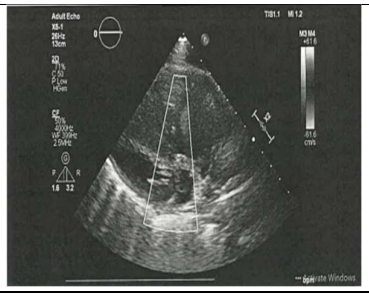	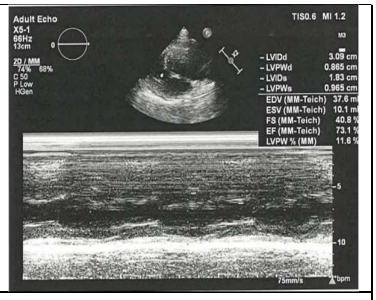
Post-procedure echocardiography showed normal functioning of the four chambers, with no pericardial effusion observed	Post-procedure echocardiography showed no regurgitation and no pericardial effusion	The Post-procedure echocardiography showed that the ejection fraction was normal

Animal P2

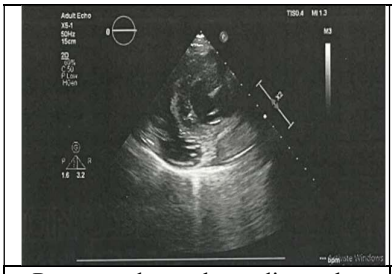

Pre-procedure echocardiography showed normal functioning of the four chambers, with no pericardial effusion observed

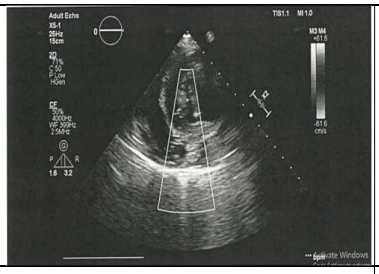

Pre-procedure echocardiography showed no regurgitation and no pericardial effusion

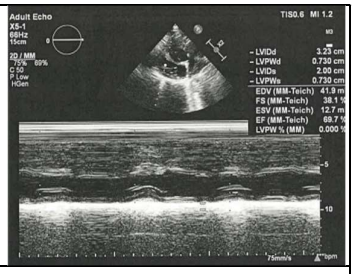

The Pre-procedure echocardiography showed that the ejection fraction was normal



Pre-procedure echocardiography showed normal functioning of the four chambers, with no pericardial effusion observed

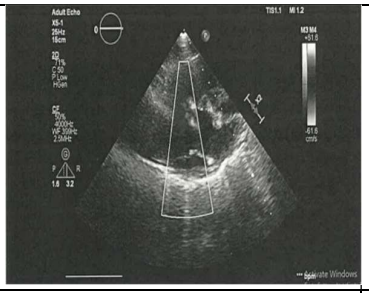

Post-procedure echocardiography showed no regurgitation and no pericardial effusion

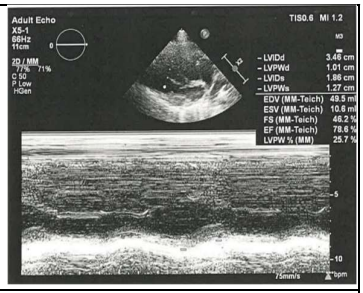

The Pre-procedure echocardiography showed that the ejection fraction was normal

Fig 6: Echo Cardiography images of animal P1 and P2

Mapping tracing images

Animal P1

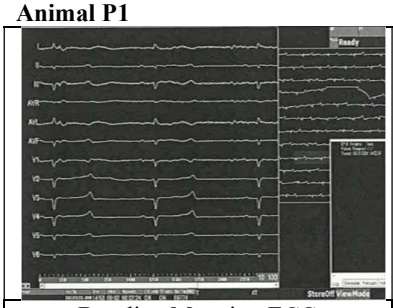

Baseline Mapping ECG

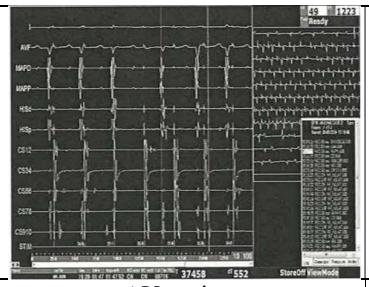

AV pacing

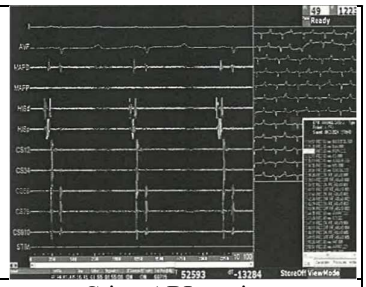

Crista ABL pacing

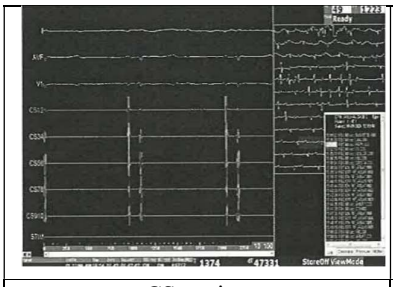

CS pacing



CTI ABL pacing

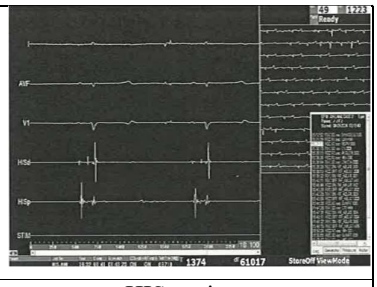

HIS pacing

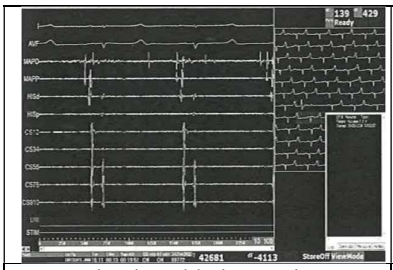

Irrigation ablation pacing

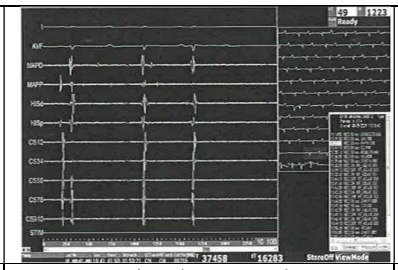

Junctional ABL pacing

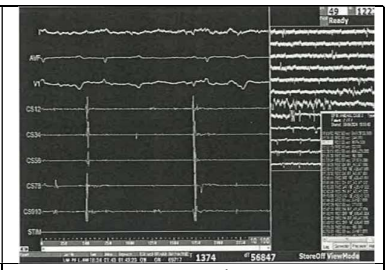

LAA pacing

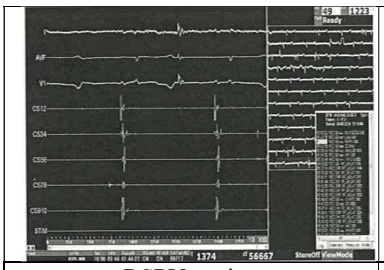

RSPV pacing

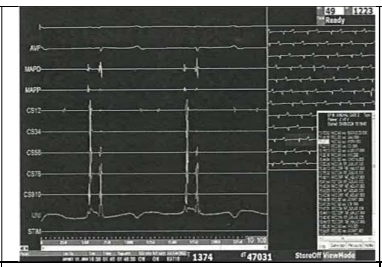

Slow pathway pacing

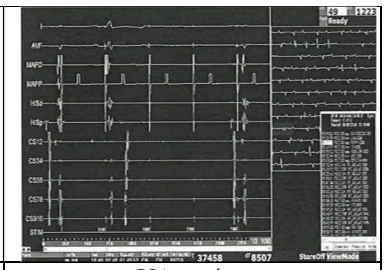

VA pacing

Animal P2

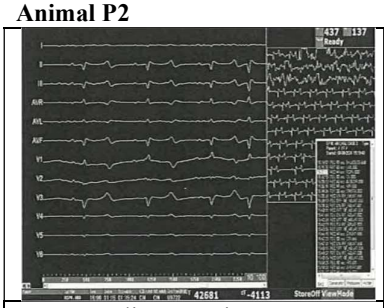

Baseline mapping ECG

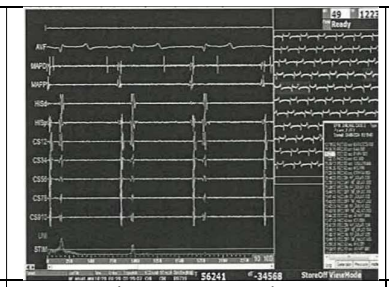

Crista ABL mapping



CS mapping

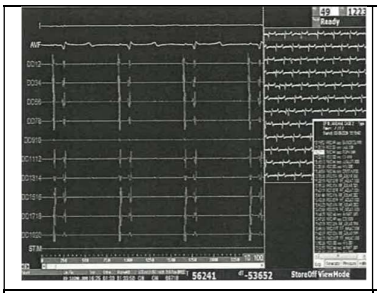

CTI ABL Irrigation mapping

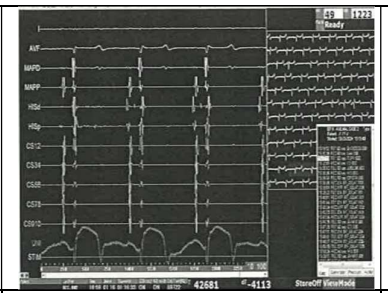

Dola deca mapping

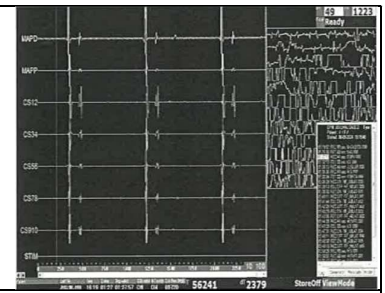

HIS mapping

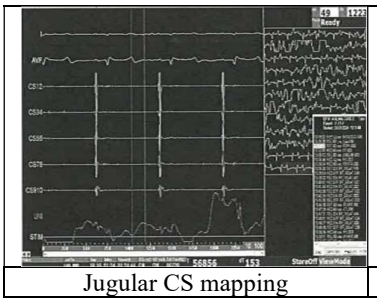

Jugular CS mapping

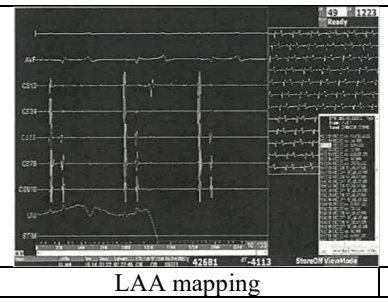

LAA mapping

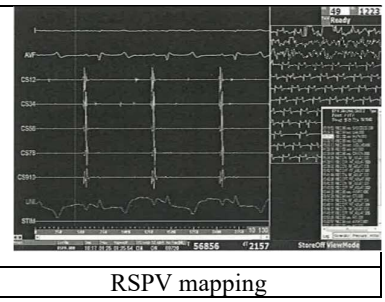

RSPV mapping

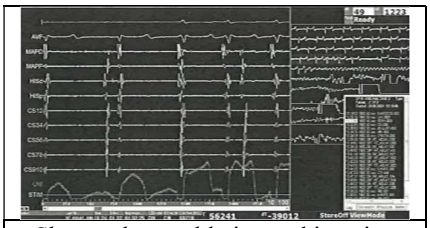

Slow pathway ablation and junction were observed, and ventricular fibrillation started

Fig 7: Mapping tracing images of animal P1 and P2

Necroscopy images

Animal P1



Harvested heart anterior position



Harvested heart posterior position



Ablation was observed at the SVC-RA junction in the harvested heart



Ablation was observed at the crista in the harvested heart

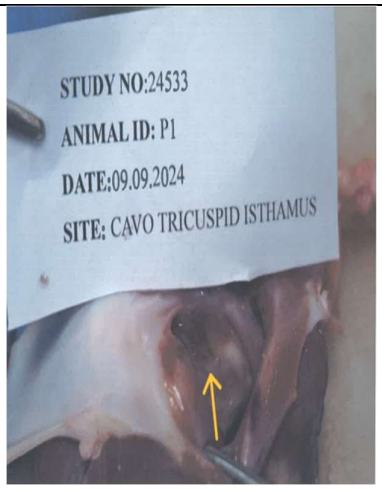

Ablation was observed at the cavo tricuspid isthmus in the harvested heart



Ablation was observed at the slow pathway region in the harvested heart

Animal P2



Harvested heart anterior position

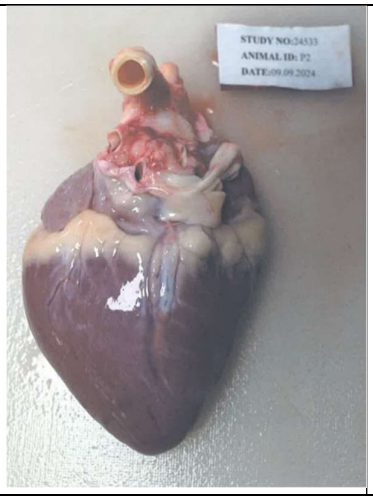

Harvested heart posterior position



Ablation was observed at the SVC-RA junction in the harvested heart

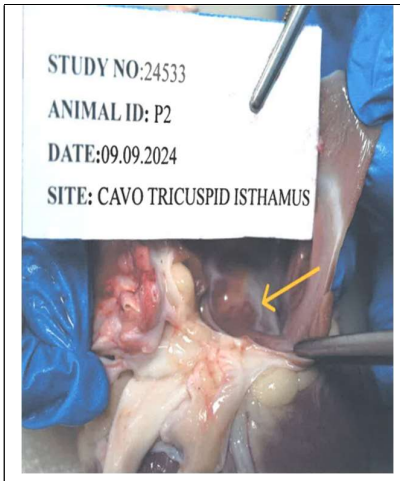

Ablation was observed at the cavo tricuspid isthmus in the harvested heart

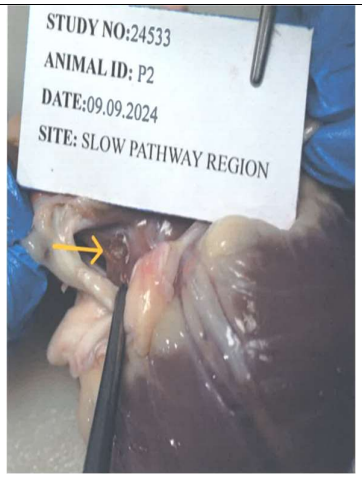

Ablation was observed at the slow pathway region in the harvested heart



Ablation was performed at the crista but no lesion was found at Crista site in the harvested heart

Fig 8: Necroscopy images of animal P1 and P2

DISCUSSIONS

The aim of this study was to assess the safety and performance of the HeartTouch™ Electrophysiology Mapping Catheter and the NaviBlaze™ Electrophysiology Ablation catheter in various heart chambers [right atrium (RA), right ventricle (RV), left atrium (LA), and pulmonary veins (PV)] under different impedance field configurations in a porcine model.

Two female pigs were selected for the study, fasted overnight with access to water ad libitum. On the day of the procedure (Day 0), the animals were prepped under anesthesia and analgesia. The right and left groins were shaved, and a percutaneous approach using the Seldinger technique was employed for catheter insertion. A 7F sheath was placed in the internal jugular vein, two 8F sheaths in the right femoral vein, and one 7F sheath in the left femoral artery. The animals underwent catheter testing to evaluate the electrophysiological mapping and ablation performance.

Mapping Catheter Testing
Animal P1 and P2
First Run
A decapolar catheter was positioned in the coronary sinus, and a quadripolar mapping catheter was advanced into the RA via femoral access. Electrogram signals were recorded from the RA, His bundle, and RV, with fluoroscopic imaging confirming the landmarks at each site. The mapping catheter successfully navigated and recorded signals from all cardiac substrates, demonstrating its efficacy.

Second Run
The setup was repeated to ensure consistency, with a decapolar catheter in the coronary sinus. For Animal P2, this was the third run of the mapping procedure.

Third Run
A transseptal puncture provided access to the LA, where a PV-12 mapping catheter was introduced. Transthoracic echocardiography (TTE) was used for visualization, and electrograms were recorded from the left pulmonary vein and LA appendage. Continuous fluoroscopic imaging and cine recordings were maintained throughout to capture detailed data. For Animal P2, this was the second run of mapping.

Ablation Catheter Testing
Animal P1
A non-irrigated ablation catheter was positioned in the right heart chambers to create lesions in the RA crista terminalis, slow pathway region, and the superior vena cava-right atrium (SVC-RA) junction. Impedance measurements showed a consistent decline from baseline to end values, indicating effective tissue interaction at targeted sites. For instance, at the crista terminalis, impedance decreased from 140 to 132 ohms in the first run and from 145 to 136 ohms in the third run. Necropsy images confirmed the presence of visible ablation lesions in P1.

Animal P2
An irrigated unidirectional ablation catheter was used in the right heart chambers to create lesions in the RA crista terminalis, cavo-tricuspid isthmus, and slow pathway region. Impedance values decreased significantly, with the crista terminalis showing a reduction from 205 to 182 ohms in the first run, and the cavo-tricuspid isthmus impedance dropping from 184 to 170 ohms. Lesions were clearly visible in the necropsy images, although no lesions were identified in the crista terminalis for Animal P2.

CONCLUSION

The study demonstrated that the HeartTouch™ Electrophysiology Mapping Catheter and the NaviBlaze™ Electrophysiology Ablation Catheter are safe and effective for use in various heart chambers under different impedance field configurations in a porcine model. The mapping catheter successfully recorded electrograms from all targeted cardiac structures, confirming its navigability and signal acquisition capabilities. The ablation catheters, both non-irrigated and irrigated, effectively created lesions at intended anatomical sites, as evidenced by consistent impedance reductions and necropsy findings. These results support the functional performance and procedural safety of both catheters. The current pre-clinical study could serve as a basis for our forthcoming clinical implications of an aforementioned HeartTouch™ Electrophysiology Mapping Catheter and the NaviBlaze™ Electrophysiology Ablation Catheter.

However, the study conducted on two animals; demonstrated safety and effectiveness; however, due to the limited sample size, it is applicable only to a small population. To generate more robust and reliable data, a follow-up study involving a larger number of animals is being conducted prior to initiating clinical trials.

REFERENCES

1. Biological Evaluation of Medical Devices Part 2: Animal welfare requirements. ISO 10993-2:2006(E)
2. Organization for Economic Co-operation and Development Principles of GLP and Compliance Monitoring (as revised in 1997) ENV/MC/CHEM (98) 17
3. Guidance Document on the Recognition, Assessment and Use of Clinical signs as humane endpoints for Experimental Animals used in Safety Evaluation. ENV/JM/MONO (2000)7, OECD, December 2000
4. CPCSEA Guidelines for Laboratory Animal Facility. Indian Journal of Pharmacology, 2003; 35:257-274
5. Guide for the Care and Use of Laboratory Animals, Institute of Laboratory Animal Resources. Commission on Life Sciences, National Research Council, National Academy Press, Washington, D.C. 1996