International Journal of Allied Medical Sciences and Clinical Research (IJAMSCR)

ISSN: 2347-6567

IJAMSCR |Volume 3 | Issue 2 | April-June- 2015
www.ijamscr.com

Research article *Medical research*

Effectiveness of autologous blood and steroid injections in patients with lateral epicondylitis, study conducted in teaching hospital

Mirza Atif baig[1], E. Srinivas radhe shyam[2], P. N. Prasad[3]

[1]*Assistant professor, Department of Orthopaedics, Shadan institute of medical sciences, Hyderabad*

[2]*Assistant professor, Department of Orthopaedics, Shadan institute of medical sciences, Hyderabad*

[3]*professor, Department of Orthopaedics, Shadan institute of medical sciences, Hyderabad*

Corresponding author*: Mirza Atif baig

Email: eyyunnis@yahoo.co.in

ABSTRACT

Background: Lateral Epicondylitis is a degenerative type of disease, the onset of which is hastened by overuse of the arm and elbow along with repeated forceful activities and awkward posture of the limb or elbow.

Objective: To find whether autologous blood injection is effective or corticosteroid injection is effective to treat lateral epicondylitis.

Materials and methods: 164 patients were diagnosed by clinical examination and divided into Group A and Group B with 82 in each group based on treatment either autologous blood injection or corticosteroid injection respectively. The entire patient were treated according to their group and observed for effectiveness of both treatments to improve at least one grade of pain on Visual Analogue Scale at 3months follow up. Data was analyzed by SPSS version 10.0.

Results: Effectiveness of autologous blood injection and steroid injection were 63(76.83%) and 42 (51.22%) respectively with significant p value 0.1675. In group A and B the male and female ratios were 1:1.27 and 1:1.73. The mean ages were 34.12 years ± 7.28SD and 36.78 years ± 9.01SD respectively. Gender, age and duration of symptoms of patients were not significantly affecting the effectiveness.

Conclusion: This study concluded that autologous blood injection is effective than steroid injection in treating lateral epicondylitis

KEY WORDS: Lateral Epicondylitis, Autologous blood and Steroid injection.

INTRODUCTION

Lateral Epicondylitis (Tennis elbow) is a degenerative type of disease, the onset of which is hastened by overuse of the arm and elbow along with repeated forceful activities and awkward posture of the limb or elbow. It has been found to be the second most frequently diagnosed musculoskeletal disorders in the neck and upper extremity with an incidence of 1-3% of the population suffer from this condition with equal distribution between men and women. Commonly affected age group is 35 to 50 years1-4, the initial events in the disease are microscopic as well as macroscopic tears in the origins of the ECRB and other extensors at the lateral epicondyle due to overexertion. This tearing is followed by formation of granulation tissue and fibrosis. Angio fibroblastic hyperplasia, resulting from avascular compromise and subsequent micro tears in the origin of the

ECRB, is the basic cause[5]. It is a degenerative process rather than inflammatory process. Diagnosis is based on clinical manifestations that are discrete and characteristic. With the elbow fully extended, the patient feels points of tenderness over the affecte point on the elbow-which is origin of the extensor carpi radialis brevis muscle from the lateral epicondyle. There is also pain with passive wrist flexion and resistive wrist extension (cozen's test) [6]. Resisted middle finger extension might indicate the involvement of Extensor Digitorum also. These tests shall be used to measure the prognosis of the condition depending upon severity and quantity of multiple tendon injuries that have built up, the extensor carpi radialis brevis may not be fully healed by conservative treatment. Nirschl defines four stages of lateral epicondylitis, showing the introduction of permanent damage beginning at Stage 2.

1. Inflammatory changes that are reversible
2. Nonreversible pathologic changes to origin of the Extensor carpi radialis brevis muscle
3. Rupture of ECRB muscle origin
4. Secondary changes such as fibrosis or calcification[7].

Many treatment modalities are recommended for lateral epicondyle, unfortunately there is little objective evidence that they help. Undoubtedly this lack of evidence reflects in part the disagreement about the causes underlying this condition. Treatment can be a single modality; a combination of treatments; or some forms of stepped case approach[8]. Lateral epicondylitis was initially assumed to be an inflammatory process and thus corticosteroid injection was used. Later it was defined as degenerative process other treatment modalities are in action.

MATERIALS AND METHODS

This comparative study was conducted during the period of 2 years from November 2012 to October 2014 at Orthopaedics department, Shadan institute of medical sciences, Hyderabad on 164 patients presenting with lateral epicondylitis. Patients were divided into Group A and Group B with 82 patients in each group based on treatment they receive either autologous blood injection or steroid injection respectively. The patients of either gender between 20 to 70 years of age presenting with lateral epicondylitis with moderate to severe pain were included in the study. Inclusion criteria where included in study through OPD of Orthopaedic dept. with the permission from Hospital and Ethical committee. Patients were explained about the study and informed consent was obtained. Patient with history of Osteomyelitis, rheumatic disease, tendon rupture, corticosteroid treatment, fractures, carpal tunnel syndrome, bilateral elbow symptoms, prior surgery were excluded from the study. Patients' detailed history was taken along with physical and systemic examination and recorded as per case sheet proforma. Lateral epicondylitis was diagnosed by clinical signs and symptoms that are discrete and characteristic. With elbow fully extended patient felt points of tenderness over affected point on the elbow which is the origin of extensor carpi radialis brevis. Some of the tests performed for diagnosing as follows: Cozen's test: there was pain with passive wrist flexion and resistive wrist extension, coffee cup test: where patient felt pain at lateral epicondyle when picking up full cup of coffee, Mills test: full pronation combined with complete finger and wrist flexion prevents full elbow extension or atleast a feeling of resistance at elbow and pain at lateral epicondyle, Maudsley's test: where resisted extension of middle finger when elbow was fully extended and forearm was pronated causes pain at lateral epicondyle. The diagnosed patients were treated according to groups divided. For injection infiltration, the patients were placed in a supine position with affected arm resting at the side of the body and the elbow flexed up to 45° with wrist pronation. By gentle palpation tender point of the epicondyle was identified and needle was inserted at 90° levels of the bone axis and then 1 to 2 mm retrieve back and infiltration was done. In Group A, 2 ml of autologous venous blood collected from the antecubital fossa of the ipsilateral side mixed with 1 ml of 2% prilocaine hydrochloride and infiltrated at the lateral epicondyl while in Group B 1 ml of 40 mg methylprednisolone acetate mixed with 1 ml of 2% prilocaine hydrochloride and was infiltrate under aseptic condition. After injection patients were kept for 30 minutes under observation to attain hemodynamic stability. Female attendant was used for female patients. Patients were followed up to 3 months to determine intervention effectiveness in terms of improvement in at least one grade of pain on

Visual Analogue Scale. Pain was assessed by Visual Analogue Scale (VAS). Data was analyzed with the help of SPSS software version 10.0. Effectiveness was stratified among age, gender and duration of elbow pain. The results were presented as tables and graphs.

RESULTS

During the period from November 2012 to October 2014, among all the patients who came to orthopaedic OPD with symptoms of lateral epicondylitis, 164 patients were randomly selected based on inclusive criteria mentioned above and 82 were in each group. Accordingly the results are Among 164 patients 66(40.24%) were males and 98 (59.76%) were female patients with male to female ratio of 1:1.48. In group A (autologous blood injection), there were 36(43.9%) male and 46(56.1%) female patients. In group B (steroid injection), there were 30 (36.59%) males and 52(63.41%) female patients. The male to female ratios in Group A and B were 1:1.27 and 1:1.73. The patients with lateral epicondylitis were distributed according to their age group as follows : In Group A there were 18 (21.95%) patients in 21 to 30 years age group, 54(65.85%) patients in 31 to 40 age group, 8(9.76%) patients in 41-50 age group and from 51 years and above there was 2(2.44%) patient reported. In Group B there were 12(14.63%) patients in 21 to 30 age group, 52(63.41%) patients in 31 to 40 age group and 10 (12.2%) patients in 41 to 50 age group and from 51 years and above there were 8(9.76%) patients reported. The mean ages of the patients in Group A and Group B were 34.12 years ± 7.28SD and 36.78 years ± 9.01SD respectively with statistically insignificant p value of 0.1675. The patients with lateral epicondylitis were distributed based on duration of symptoms as follows: In Group A the patients with 45 to 60 days of duration were 22(26.83%), 61 to 90 days of duration were 24(29.27%) and those who were having symptoms more than 90 days of duration were 36(43.9%). In Group B the patients with 45 to 60 days of duration were 26(31.71%), 61 to 90 days of duration were 34(41.46%) and those who were having symptoms more than 90 days of duration were 22(26.83%). The mean duration of symptoms in patients with lateral epicondylitis in Group A and Group B were 58.52 days ± 33.24SD and 60.63 days ± 31.26SD with statistically insignificant p value of 0.0658 The number of patients who showed effectiveness with autologous and blood injection (Group A) and steroid injection (Group B) were 63(76.83%) and 42 (51.22%) respectively with significant p value of 0.011.

Graph 1: effectiveness of autologous blood injection (group a) and steroid injection (group b) in patients with lateral epicondylitis

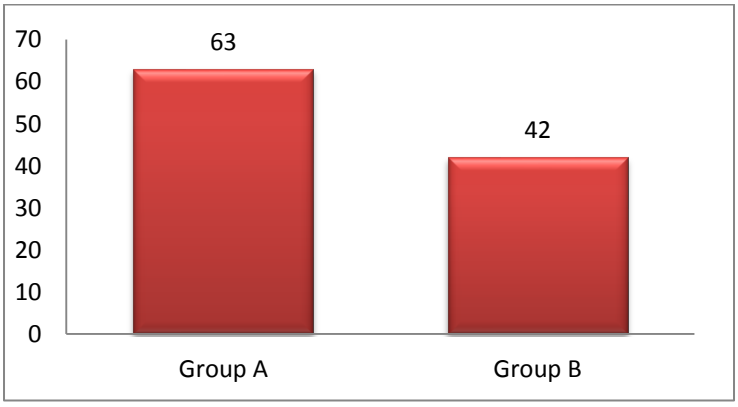

The effectiveness in patients with autologous blood injection (Group A) and steroid injection (Group B) was distributed according to age group as follows: Group A: In the age group of 21 to 30 years 13(20.63%) patients showed effectiveness, in 31 to 40 years 45(71.43%), in 41 to 50 years 4(6.35%) and the patients belongs to 51 years and above group showed effectiveness was 1(1.59%). Group B: In the age group of 21 to 30 years 6(14.29%) patients showed effectiveness, in 31 to 40 years 28(66.67%),

in 41 to 50 years 5(11.9%) and the patients belongs to 51 years and above group showed effectiveness was 3 (7.14%). (P value= 0.3093)

Graph 2: Distribution of Effectiveness of Autologous blood injection (Group A) and Steroid injection (Group B) according to Age

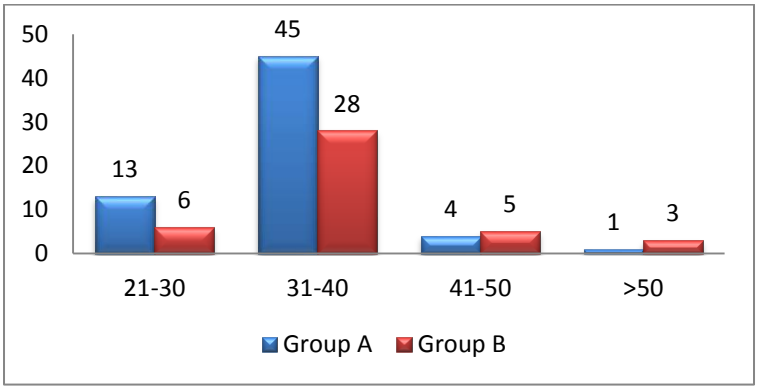

The effectiveness in patients with autologous blood injection (Group A) and steroid injection (Group B) was distributed according to duration of symptoms as follows: Group A: among 63 patients 16(25.4%) were 45 to 60 groups, 14 (22.22%) were 61 to 90 group and those who are having symptoms more than 90 days were 33(52.38%). Group B: among 42 patients 15(35.71%) were 45 to 60 group, 9(21.43%) were 61 to 90 group and those who are having symptoms more than 90 days were 18(42.86%). (p value =0.499)

Table 1: Distribution of Effectiveness of Autologous blood and steroid injection according to Duration of symptoms

Duration of symptoms	Group A n (%)	Group B n(%)	P value
45-60 days	16	15	0.499
61-90 days	14	9	
>90 days	33	18	

Sex distribution of effectiveness in autologous blood injection (GroupA) and steroid injection (GroupB) in patients with lateral epicodylitis respectively were; male patients were 21(33.33%) and 15(35.71%) while females were 42(66.67%) and 27(64.29%) with insignificant p value of 0.8379

Table 2.Distribution of Effectiveness of Autologous blood and steroid injection according to Gender

Group	Male n (%)	Female n (%)	P value
Group A	21(33.33%)	42(66.67%)	0.8379
Group B	15(35.71%)	27(64.29%)	

DISCUSSION

Lateral epicondylitis is a degenerative disorder rather than inflammatory, characterised by angiofibroblastic degeneration or hyperplasia[9]. Diagnosis is done based on clinical manifestation, there are many treatment modalities based on the type and severity of lesion. A proper treatment should be taken for pain relief with minimal side effects. In this study there were more females compared to males in both groups with the

ratio 1:1.27 and 1:1.73 (Group A and Group B respectively). The similar findings were seen in the study by DR. Ajay Bharti et al[10]. With female predominance of 78% and in the study by Hasan Onur Arik et al[11]. There was a high incidence of effectiveness among the age group of 31-40 which was similar to other previous studies. In this study the effectiveness is high when duration of symptoms was more than 90 days. The complete recovery rate at 3 months was 76.83% after autologous blood and 51.22% after corticosteroid injection, both autologous blood injection and corticosteroid injection decreased severity of pain but autologous, seemed to be more effective. It is clearly observed at 3 months. These findings are similar with the study by Hasan Onur Arik et al[11] where 95% effective with autologous blood injection and 62.5% effective with corticosteroid injection and mahumma saqib et al[12]. Where 82.05% patients were effective with autologous blood injection and 51.28% of patients were effective with corticosteroid injection. One study reported no significant difference between autologous blood injections, corticosteroid injection. There were no side-effects and complications observed during the study in any patients except two patients who showed increase in pain by first month and relieved by third month. We were unable to compare the two groups with respect to complications of the treatment, age, gender distribution and duration of symptoms had statistically insignificant effects on effectiveness of autologous blood injection and steroid injection in patients with lateral epicondylitis. At last we concluded that autologous blood injection is more effective than steroid injection in the treatment of lateral epicondylitis.

CONCLUSION

In this study it is concluded that autologous blood injection is significantly effective when compared to steroid injection in the treatment of lateral epicondylitis with the improvement of at least one grade of pain on Visual Analougue Scale at 3 months

REFERENCES

[1]. Assendelft W, Green S, Buchbinder R, Struijs P, Smidt N. Tennis elbow. BMJ. 2003;327:329
[2]. Gruchow HW and Pelletier DW: An epidemiologic study of tennis elbow. American Journal of Sports Medicine, 7(4):234-238, 1979.
[3]. J P Haahr, J H Anderssen, Physical and psychosocial risk factors for lateral epicondylitis: a population based case-referent study; Occup Environ Med 2003; 60:322–329.
[4]. Shiri R, Viikari-Juntura E. Lateral and medial epicondylitis: role of occupational factors. Best Pract Res Clin Rheumatol 2011 Feb; 25(1): 43-57.
[5]. Tennis elbow from the MedlinePlus Medical Encyclopedia.
[6]. Owens, Brett D; Moriatis Wolf, Jennifer; Murphy, Kevin P (2009-11-03). "Lateral Epicondylitis: Workup". eMedicine Orthopedic Surgery. Retrieved 2010-04-19.
[7]. PIERRE GEOFFROY, MD, CCFP, MARKJ. YAFFE, MD, CCFP, IVAN ROHAN, MD, CCFP, Diagnosing and treating lateral epicondylits; Canadian Family Physician VOL 40: January 1994.
[8]. Baily RA, Brock B; Hydrocortisone in tennis elbow; a controlled series. Proc R Soc Med 1957; 50:389–90.
[9]. Bharti A, Sachin A. Clinical assessment of functional outcome in lateral epicondylitis managed by local infiltration of autologous blood. Internet journal of medial update 2010 January; 5(1): 20-24.
[10]. Hasan Onur Arik, Ozkan Kose, Ferhat Guler et al; Injection of autologous blood versus corticosteroid for lateral epicondylitis: randomise controlled study; Journal of Orthopaedic Surgery 2014; 22(3):333-7.
[11]. Muhammad saqib, Muhammad Ayaz Khan, Muhammad Imran Khan, Comparative Effectiveness of Autologous Blood and steroid injections in patients with Lateral epicondylitis, JPOA; Vol 26(1) March 2014; 11-15.
[12]. Edwards SG, Calandruccio JH: Autologous blood injections for refractory lateral epicondylitis. J Hand Surg 2003; 28A: 272-8.
[13]. Mishra A, Pavelko T: Treatment of chronic elbow tendinosis with buffered platelet-rich plasma. Is J Sport Med 2006; 34:1774-8?

[14]. Kitai E, Itay S, Ruder A, EngelJ, Modan M. An epidemiological study of lateral epicondylitis (tennis elbow) in amateur male players. Ann Chir Main Memb Super 1986; 5: 113-21.
[15]. Orchard J, Kountouris A. The management of tennis elbow. British Med J 2011 May 10; 342:d2687.
[16]. Allman FL: Tennis elbow, Etiology, prevention and *treatment. Clin Orthop 3:* 308-316, 1975.
[17]. Nirschl RP. Soft-tissue injuries about the elbow. Clin Sports Med 1986; 5:637-52

How to cite this article: Mirza Atif B, Srinivas R S, Prasad P. N. Effectiveness of autologous blood and steroid injections in patients with lateral epicondylitis, study conducted in teaching hospital. Int J of Allied Med Sci and Clin Res 2015;3(2):212-217.