International Journal of Allied Medical Sciences and Clinical Research (IJAMSCR)
IJAMSCR |Vol.13 | Issue 2| Apr - Jun -2025
www.ijamscr.com
DOI : https://doi.org/10.61096/ijamscr.v13.iss2.2025.209-214
ISSN: 2347-6567

Case Study

Digital Smile Design: Aiding in the esthetic treatment of a Patient with Celiac Disease and Structural loss of Enamel

Dr. Rajbir Kaur*, Dr. Narendra Padiyar U, Dr. Aditi Sharma

MDS, PG-resident, Department of Prosthodontics, Crown $ Bridge, Mahatma Gandhi Dental College & Hospital, Jaipur.
MDS, Department of Prosthodontics, Crown & Bridge, Mahatma Gandhi Dental College & Hospital, Jaipur.
[*]Senior Lecturer, Department of Prosthodontics, Crown $ Bridge, Mahatma Gandhi Dental College & Hospital, Jaipur.

*Author for Correspondence: Dr. Rajbir Kaur
Email: brraji10@gmail.com

Published on: 25 May 2025

Published by:
DrSriram Publications

2025| All rights reserved.

Creative Commons Attribution 4.0 International License.

Abstract

Background: Dental case reports play a vital role in documenting rare presentations, innovative treatment approaches, and complications encountered in clinical dentistry. Patients with systemic conditions like celiac disease often exhibit unique oral manifestations such as enamel defects, which necessitate personalized management strategies.
Case Presentation: This report discusses a 50-year-old female patient with a medical history of celiac disease, presenting with extensive enamel wear and an unpleasant smile. Digital Smile Design (DSD) was employed to plan her aesthetic rehabilitation, ensuring a patient-centered approach and precise treatment planning.
Management and Outcome: The patient was managed through conservative enamel reduction complemented by fixed coronal restorations, guided by DSD to achieve optimal aesthetics and function. The treatment resulted in a significant improvement in smile aesthetics and patient satisfaction, with relief from psychological discomfort caused by aesthetic concerns.
Conclusion: This case underscores the importance of treatment strategies in managing unesthetic smiles. Utilizing digital tools such as DSD can enhance treatment precision and patient involvement, ultimately improving clinical outcomes.

Keywords: Dental anomaly, Celiac disease, Enamel wear, Digital Smile Design, Aesthetic rehabilitation

INTRODUCTION

Celiac disease (CD) is a chronic, immune-mediated systemic disorder triggered by the ingestion of glutena protein found in wheat, barley, and ryein genetically susceptible individuals. This condition results in inflammation and subsequent atrophy of the small intestinal villi, leading to impaired nutrient absorption. Globally, the prevalence of CD is estimated to be around 1%, though it varies depending on geographic, genetic, and environmental factors (1). While the gastrointestinal system is the primary site of manifestation, CD is increasingly recognized for its wide array of extraintestinal symptoms. Among these, oral manifestations are particularly significant, as they often precede gastrointestinal symptoms and can serve as early diagnostic clues for underlying systemic disease (2).

Oral findings associated with CD are diverse and may include recurrent aphthous ulcers, glossitis, cheilitis, delayed dental eruption, and various dental enamel defects. Of particular clinical interest are enamel anomalies, which are frequently symmetrical and bilaterally distributed, typically affecting the permanent dentition. These include enamel hypoplasia, characterized by pits, grooves, discoloration, and reduced enamel thickness. The pathogenesis of these defects is multifactorial, likely resulting from malabsorption of essential nutrients such as calcium, phosphate, and vitamins D and A during critical periods of tooth development (3). This deficiency impairs amelogenesis, leading to structurally compromised enamel that is more susceptible to mechanical wear and decay. Such dental anomalies not only compromise oral function and esthetics but can also contribute to significant psychological distress, particularly in adolescents and young adults (4).

Despite the clinical importance of these oral manifestations, there is a relative scarcity of literature documenting comprehensive restorative approaches in CD patients. This lack of detailed case-based evidence underscores the need for further exploration and dissemination of treatment strategies. Advances in digital dentistry have opened new avenues for patient-specific, minimally invasive, and esthetically driven dental care. Among these technologies, Digital Smile Design (DSD) has emerged as a powerful tool that enhances diagnostic accuracy, treatment predictability, and patient communication. DSD involves the digital analysis of facial and dental proportions to design a customized smile that aligns with the patient's unique anatomy and esthetic goals (3). This patient-centered methodology enables clinicians to create a virtual mock-up of the proposed treatment, allowing for real-time modifications and informed decision-making before initiating any irreversible procedures (5).

The application of DSD is particularly beneficial in managing dental anomalies secondary to systemic diseases like CD. When enamel defects result in extensive anterior wear, rehabilitation becomes both a functional necessity and an esthetic challenge. Traditional restorative approaches may fall short in addressing the nuanced anatomical and psychological needs of these patients. In contrast, digital planning allows for precise visualization of restorative outcomes, ensuring that the final result aligns with patient expectations. Additionally, DSD promotes interdisciplinary collaboration between restorative dentists, prosthodontists, orthodontists, and other healthcare professionals, which is crucial for addressing the multifaceted needs of CD patients (6).

This case report presents the anterior esthetic rehabilitation of a patient with severe enamel wear attributable to undiagnosed celiac disease. The management strategy involved a comprehensive assessment of the patient's medical and dental history, followed by the application of DSD to plan and execute a minimally invasive restorative treatment. Through this digitally assisted, patient-centered approach, the treatment not only restored dental function and esthetics but also improved the patient's self-esteem and quality of life. The case highlights the pivotal role of early recognition of oral signs in systemic diseases and the transformative impact of digital technologies in modern dentistry (7).

Case presentation

Patient Information

A 50-year-old female patient presented to the Department of Prosthodontics with concerns about worn dentition and dissatisfaction with her smile's esthetic appearance. She reported feelings of self-consciousness due to "shortened teeth," a "discolored smile," and a resulting "loss of confidence" in social interactions. Her medical history revealed a diagnosis of celiac disease at age 43, which had been effectively managed through a strict gluten-free diet. She reported no recent gastrointestinal symptoms and had maintained regular medical follow-ups. There was no significant history of dental trauma or prior extensive dental treatments. The patient expressed interest in improving the appearance of her smile while addressing functional concerns associated with enamel loss. Her dietary compliance and stable systemic condition provided an optimal background for proceeding with comprehensive oral rehabilitation. A holistic and esthetically oriented approach was considered, with emphasis on minimally invasive procedures to respect the remaining tooth structure and the patient's systemic health status.

Clinical Findings

A thorough extraoral and intraoral examination was conducted. The extraoral assessment revealed well-balanced facial proportions and a harmonious smile line, with no observable asymmetry or swelling. Lip support

was adequate, and the facial midline did not co-incided with the dental midline. The lips were competent during both rest and function. Intraorally, there was generalized enamel abrasion and attrition across anterior and posterior teeth. Particularly concerning were the maxillary and mandibular anterior teeth, which exhibited exposed dentin and asymmetric wear facets. A visible loss of incisal edges contributed to a flattened incisal plane and altered smile esthetics. Despite the extensive wear, the periodontal tissues remained healthy, with no signs of inflammation, bleeding, or gingival recession. The occlusal relationship was Angle Class I; however, there was a noticeable reduction in overjet and overbite attributed to attritional loss. The severity of the wear pattern indicated a long-standing progression, necessitating comprehensive diagnostic work-up and tailored intervention**.**

Diagnostic Assessment

Study models obtained through dental impressions revealed considerable clinical crown loss, especially in the maxillary anterior region, including the canines and incisors. Evaluation of overjet & overbite suggested it had been significantly reduced. Radiographic analysis, including an orthopantomogram (OPG) and periapical films, confirmed the absence of periapical pathology. The images demonstrated reduced enamel thickness and exposed dentin, consistent with chronic wear rather than active decay or pulpal involvement. Additional diagnostic measures included a review of the patient's medical records, which aligned with the presence of enamel hypoplasia—a common oral manifestation in patients with long-standing celiac disease. A cervical abrasion index was applied, confirming severe cervical enamel wear. These findings indicated that both systemic and mechanical factors contributed to the patient's dental condition. The case was thus categorized as a functional and esthetic impairment with an underlying systemic etiology, guiding the need for interdisciplinary treatment planning.

Therapeutic Intervention

Given the complexity of the case, a multidisciplinary treatment approach was planned, prioritizing functional rehabilitation and esthetic enhancement. The treatment objectives included restoring the lost tooth structure, improving smile esthetics, and enhancing the patient's self-confidence. Digital Smile Design (DSD) technology was utilized to aid in treatment planning and patient communication. Initial steps involved obtaining high-resolution extraoral photographs, intraoral digital scans using a TRIOS (3Shape) scanner, and facebow records. These were integrated into DSD software (exocad software) to generate a virtual design of the final outcome considering patient's facial analysis, dental midline, height & arc of smile, Golden proportion. The patient actively participated in smile design selection, allowing shared decision-making and visualization of the proposed treatment. The provisional plan included minimally invasive all ceramic restorations on the affected teeth, with focus on esthetics and structural preservation. Mock-ups and provisional restorations were used to evaluate function and esthetics prior to final placement. The phased treatment plan aimed to achieve predictable, patient-specific, and long-lasting results.

Preparatory Procedures

To begin the restorative process, minimal tooth reduction was performed on the anterior teeth to allow space for the full coverage all ceramic restorations. This conservative approach was guided by the pre-established Digital Smile Design (DSD) templates, ensuring precise and predictable preparation. The use of DSD provided a visual reference that preserved tooth structure while aligning with the desired esthetic outcome. Following tooth preparation, provisional restorations were fabricated and placed using the digital plan as a blueprint. These temporaries allowed the patient to preview the planned outcome, assess function and comfort, and provide feedback before finalizing the permanent restorations.

Restorative Procedures

The final full veneer crowns were fabricated using CAD/CAM technology based on the DSD blueprint. High-strength zirconia was selected to provide long-term durability and lifelike esthetics. The prepared teeth were thoroughly cleaned, etched, and conditioned before bonding. Adhesive resin cement was used to securely place the full veneer crowns, and careful attention was given to ensuring optimal fit, marginal integrity, and proximal contacts. The DSD mock-up acted as a guide for esthetic evaluation, ensuring symmetry and proportion were maintained. Functional assessments were conducted to confirm that occlusion was harmonious, and the patient's feedback was incorporated to refine the overall result.

Additional Interventions

Post-placement adjustments were necessary to refine the occlusion and eliminate any potential interferences. Occlusal contacts were checked in both centric and excursive movements to establish a mutually protected occlusion. These adjustments ensured long-term functional stability and minimized the risk of restoration failure. Additionally, the patient received thorough oral hygiene instructions to maintain gingival health around the restorations. Dietary counseling was also reinforced, emphasizing the importance of avoiding acidic

and abrasive foods that could compromise enamel or restorative materials. Patient education played a critical role in supporting long-term outcomes, especially given the systemic implications of her underlying celiac disease.

Follow-Up and Outcome

The patient was reviewed postoperatively at intervals of 1 week, 3 months, and 6 months. During each follow-up, clinical evaluations confirmed the integrity of the restorations, with no evidence of full veneer crowns debonding, marginal discoloration, or postoperative sensitivity. The patient reported complete satisfaction with the functional and esthetic outcomes. A noticeable improvement in her self-confidence and willingness to smile was observed during subsequent visits. No discomfort or sensitivity was reported throughout the follow-up period. Ongoing maintenance included professional prophylaxis and continued oral hygiene reinforcement. The success of the case highlights the value of digital planning and personalized, conservative intervention.



Fig 1: Photography For Digital Smile Designing

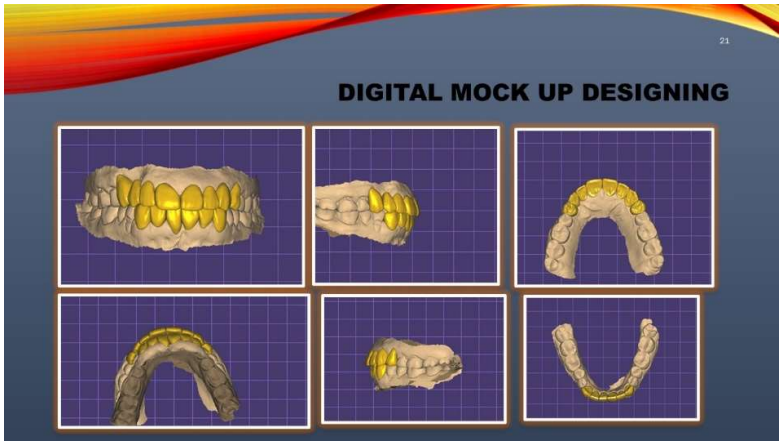

Fig 2: Digital Mock Up Designing



Fig 3: Drawing Facial & Intraoral Reference Lines And Ideal Dental Contours



Fig 4: Periodontal Treatment & Crown Preparations According To Templates



Fig 5: Comparison Between Before & After Treatment

DISCUSSIONS

Celiac disease's association with enamel hypoplasia and susceptibility to wear is well-documented (8). These anomalies pose unique clinical challenges due to their progression, esthetic implications, and functional

impact. Unlike typical wear cases, systemic conditions like CD necessitate a comprehensive diagnosis integrating medical history with oral findings.

Literature indicates that enamel defects in CD are primarily hypoplastic and opacities, leading to increased sensitivity and esthetic concerns (9). Management strategies vary from conservative resin restorations to full-coverage restorations, emphasizing early intervention to prevent further destruction.

In this case, the extensive enamel wear required a carefully tailored approach that integrated digital technology. DSD enabled precise visualization of the final smile outcome, facilitating patient involvement, which is essential given the psychosocial impact of anterior esthetic concerns (10). The use of intraoral scanning and CAD/CAM fabrication ensured accuracy, digital planning reduced chairside time, and patient expectations were managed effectively.

Compared to standard treatment protocols, this approach offers advantages such as reduced invasive procedures, predictable results, and improved communication. The challenge lay in restoring function without over-reduction of tooth structure, given the already compromised enamel. The conservative preparation, guided by digital planning, minimized tissue removal.

The choice of full veneer all ceramic restorations provided a minimally invasive yet durable solution, aligning with recent evidence favoring conservative biomechanics in rehabilitating affected teeth. Regular follow-up confirmed the longevity of restorations and the stability of the occlusion, supporting the efficacy of a digitally guided aesthetic approach in managing complex cases with systemic origins.

Notably, early diagnosis and interdisciplinary collaboration between periodontists, prosthodontists, and the patient's physician were crucial for comprehensive care. Recognition of systemic conditions and their oral manifestations can lead to improved patient outcomes and quality of life.

CONCLUSION

This case highlights the pivotal role of comprehensive clinical evaluation and personalized treatment planning in managing rare dental anomalies associated with celiac disease. The integration of Digital Smile Design facilitated precise, patient-centric rehabilitation, exemplifying the advancements in digital dentistry. Early diagnosis and tailored interventions are instrumental in restoring function and esthetics, ultimately enhancing patient confidence and overall well-being.

REFERENCES

1. Aine, L., Mäki, M., Collin, P., Keyriläinen, O. (1990). Dental enamel defects in celiac disease. *Journal of Oral Pathology & Medicine*, 19(6), 241–45.
2. Pastor-Clerigues, A., et al. (2007). Oral mucosal lesions in coeliac disease. *European Journal of Clinical Investigation*, 37(6), 512–17.
3. Rashid, M., Zarkadas, M. (2013). Oral manifestations of celiac disease: A clinical guide. *Canadian Journal of Gastroenterology*, 27(6), 353–356.
4. Jericho, H., Guandalini, S. (2016). Extraintestinal manifestations of celiac disease in children. *Current Opinion in Pediatrics*, 28(5), 626–32.
5. Tjäderhane, L. (1998). The cause and treatment of dental erosion. *Acta Odontologica Scandinavica*, 56(6), 325–329.
6. Coachman, C., *et al.* (2012). Digital Smile Design: A tool for treatment planning and communication in esthetic dentistry. *Quintessence Dental Technology*, 35, 103–111.
7. Gürel, G. (2003). The science and art of porcelain laminate veneers. *Quintessence Publishing.*
8. Mangano, F., *et al.* (2018). Digital dentistry: New materials and techniques. *International Journal of Dentistry*, 2018, Article ID 9649267.
9. Zimmermann, M., Mehl, A. (2015). Virtual smile design systems: A current review. *International Journal of Computerized Dentistry*, 18(4), 303-17.
10. Cortellini, D., *et al.* (2021). Full digital workflow for esthetic rehabilitations using monolithic lithium disilicate restorations: A case report. *Journal of Prosthetic Dentistry*, 126(3), 433–437.