International Journal of Allied Medical Sciences and Clinical Research (IJAMSCR)

IJAMSCR |Volume 3 | Issue 2 | April-June- 2015
www.ijamscr.com

Research article ***Medical research***

Accuracy of fine needle aspiration cytology and incidence of benign/malignant tumours in solitary thyroid nodules

Dr.Jamila Alagarsamy[1*] Dr.Ravi Sivaraman [2] Dr.Valarmathi Kadhirvel[3]

[1]*Department of Pathology, Stanley Medical College, Chennai, Tamilnadu, India*

[2]*Department of Pathology, Chengalpattu Medical College, Chengalpattu, Tamilnadu, India*

[3]*Department of Pathology, Stanley Medical College, Chennai, Tamilnadu, India*

***Corresponding author: Dr. Jamila Alagarsamy**

ABSTRACT

BACKGROUND AND AIMS

Fine needle aspiration cytology (FNAC) is still considered the gold standard test for the diagnosis of solitary thyroid nodules (STN). To determine the accuracy of Fine Needle Aspiration and Incidence of Malignant and Benign tumours in solitary nodules of thyroid

METHODS AND RESULTS

This is a cross-sectional and descriptive study involving 122 patients of any age and sex who had solitary thyroid nodules attending the surgical out-patient department and later subjected to surgery. The study was conducted at Government Chengalpattu Medical College, Chengalpattu. The study period was from 2012 to 2014.The patients included in the study had a STN clinically and sonographically. All the patients included were biochemically euthyroid and all underwent hemi-thyroidectomy. All the cytology and histopathology samples were correlated. The sensitivity (56.3), Specificity (98.10%), positive predictive value (81.80%), negative predictive value (93.70%) and accuracy of FNAC (93%) were analyzed. The incidence of malignant tumours was 13.11% and benign tumours were 7.38%.

CONCLUSION

We conclude that FNAC is an invaluable and minimally invasive procedure for pre-operative assessment of patients with a thyroid nodule. FNAC has high accuracy in the diagnostic evaluation of thyroid nodule. This study intends to alert the public about the simple mode of diagnosis, knowledge about definitive treatment and a proper follow-up once a histopathological diagnosis is obtained.

KEY WORDS: Aspiration Cytology, Accuracy, Solitary Nodules.

INTRODUCTION

Solitary thyroid nodules (STN) are widely prevalent among the Indian population (4-7 %). Majority of thyroid nodules are hyperplastic lesions followed by benign tumours and malignant tumours (1). STN is defined clinically as a localized thyroid enlargement with apparently normal rest of the gland. The main aim of evaluating STN is to identify lesions with malignant potential (2). Fine needle aspiration cytology (FNAC) is a simple, quick, outpatient procedure with less contraindications and low complications and hence considered the gold standard test in the initial

evaluation of thyroid nodules (3). The limitations of FNAC include false positive and false negative results and a minor proportion falls into the intermediate or suspicious group. This study aims to determine the accuracy of FNAC by correlating the histopathological diagnosis with the cytological diagnosis. The incidence of benign and malignant tumours in the study group was also analyzed and categorized.

MATERIALS AND METHODS

This cross-sectional descriptive study was conducted at Chengalpattu medical college over a period of 3 years from January 2012 to December 2014. The study included 122 patients who came to the surgical out-patient department with a solitary thyroid nodule. A detailed history, thyroid function tests, ultrasound neck, FNAC and post-operative histopathology were analyzed. The patients included in the study had a STN clinically and sonographically. All the patients included were biochemically euthyroid and all underwent hemithyroidectomy. All the cytology and histopathology samples were reported by the same team of pathologists. All the FNAC procedures were performed using Non-aspiration and Aspiration technique with a 23-gauge needle and 5 ml syringe. 2-3 sites were aspirated with multiple passes at various angles and depths. The cytological material was placed on 4-5 slides, fixed in 100% Isopropyl alcohol for 30 minutes and stained with Haematoxylin and Eosin. If fluid was aspirated, the material was centrifuged at 3000 revolutions per minute for 15 minutes and smears were made using the sediment. The results were categorized using The Bethesda Classification (4) as insufficient, benign, atypical follicular lesion of undetermined significance, suspicious for malignancy and malignancy. Adequacy of the smear was considered if atleast 5 groups of follicular cells, each group containing 10 or more cells were seen (5). All the patients underwent hemi-thyroidectomy and the sample was received in our department. A detailed gross examination of the sample, representative sections were taken from the sample, processing of the tissue was done and stained with Haematoxylin and Eosin stain. A definite histopathology diagnosis was made and compared with FNAC results. Data was analysed using SPSS – 16 version software to assess sensitivity, specificity and accuracy of FNAC.

RESULTS AND DISCUSSION

RESULTS

Total number of cases included in the study was 122. Age and sex distribution among the 122 cases was tabulated. The youngest patient in this study was 14 years old and the oldest was 85 years old. STN was common in females compared to males. The incidence of benign and malignant tumours among the 122 cases was 13.11% and 7.38% respectively. Among the benign tumours, 14 cases were follicular adenoma, 2 cases were Hurthle cell adenoma and 1 case of Hyalinizing trabecular adenoma were reported. Among the 16 malignant tumours, 13 cases of papillary carcinoma, 1 case of Follicular carcinoma, 1 case of Carcinosarcoma and 1 case of medullary carcinoma was documented. Among the 13 cases of papillary carcinoma, 2 cases were papillary micro carcinoma and 2 cases were follicular variant of papillary carcinoma. Regarding the correlation of FNAC with histopathology, 9 cases had a negative correlation. 7 cases were diagnosed as benign in cytology which turned out to be malignant on histopathology (False negative).2 cases were diagnosed as malignant in cytology which was benign in histopathology (False positive). The false negative cases were diagnosed as colloid nodules, toxic goiter or as Follicular neoplasm. 2 cases turned out to be papillary micro carcinoma. The false positive cases were diagnosed as papillary carcinoma which later turned out to be hyperplastic nodules.

Table No 1 – Fnac Diagnosis of Various Lesions

FNAC Diagnosis	Frequency	Percentage
Colloid Goitre	102	83.61
Adenoma	6	4.92
Carcinoma	11	9.02
Others	3	2.46
Total	122	100

Table 2 – Histopathology Diagnosis of Various Lesions

Histopathology Diagnosis	Frequency	Percentage
Colloid Goitre	94	77.05
Adenoma	9	7.38
Carcinoma	16	13.11
Others	3	2.46
Total	122	100

TABLE 3 – FNAC AND HISTOPATHOLOGY DIAGNOSIS CORRELATION

		Histopathology				
		Colloid Goitre	**Adenoma**	**Carcinoma**	**Others**	**Total**
FNAC	Colloid Goitre	88	5	7	2	102
	Adenoma	2	3	1	0	6
	Carcinoma	2	0	9	0	11
	Others	1	1	0	1	3
	Total	93	9	17	3	122

TABLE 4 – FINAL CONCLUSIONS

Accuracy Statistics		**Lower CI**	**Upper CI**
Sensitivity	56.30%	31.90%	80.60%
Specificity	98.10%	95.50%	100.00%
Positive Predictive Value	81.80%	59.00%	100.00%
Negative Predictive Value	93.70%	89.20%	98.20%
Likelihood Ratio +ve	0.30	7.07	1.26
Likelihood Ratio -ve	0.45	0.26	0.78
Diagnostic Effectiveness	0.93	0.88	0.97
Prevalence	0.13		

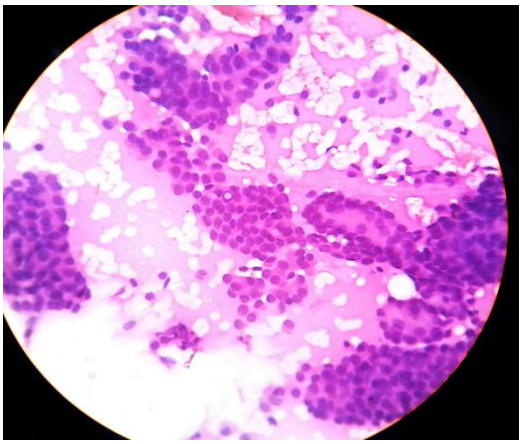

Fig 1 – Fnac of Colloid/Hyperplastic Nodule, H&E, 10 X

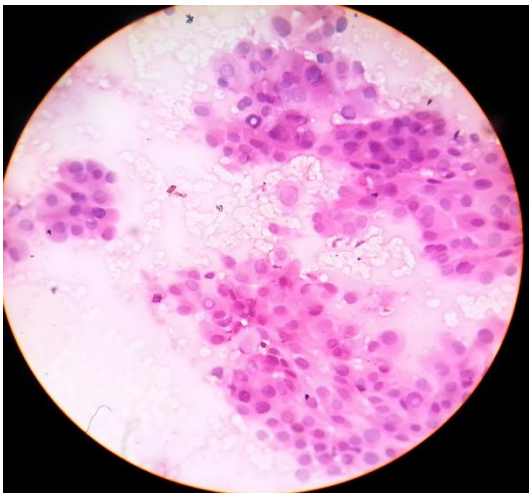

Fig 2 – Papillary Carcinoma Thyroid Exhibiting Intranuclear Vacuolation, H& E, 10 X

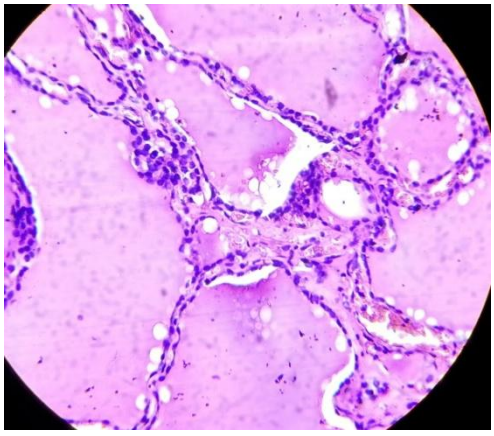

Fig 3 - Histopathology of Colloid Goitre, H& E, 10 xs

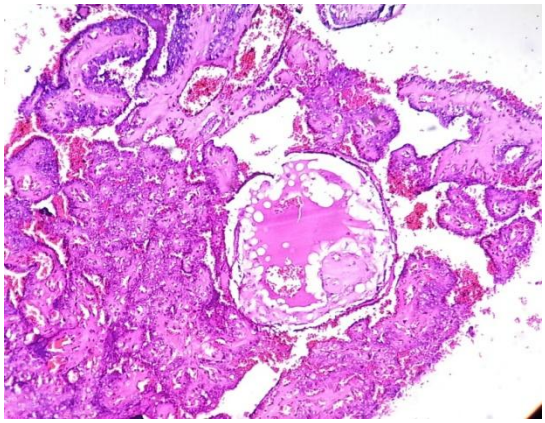

Fig 4 - Histopathology Picture Of Papillary Carcinoma, H&E, 10 X

DISCUSSION

STN presents a challenge for us to diagnose and manage the patient. A palpable nodule is usually more than 1 cm. It is more common in women (6.4%) than men (1.5%) and prevalence increases with age. Prevalence by Ultrasound is 30-50% and at autopsy is upto 50%.Thyroid nodules are more common in women and increases in incidence with age. Male sex and increasing age is also a risk factor for malignancy. Exposure to radiation increases the risk of both benign and malignant thyroid lesions and persists for at least 3 decades beyond time of exposure. Family history of medullary thyroid cancer or multiple endocrine neoplasia (MEN - 2 or 2 b syndrome) increases the risk for Medullary carcinoma of the thyroid. The pathological differential diagnosis for a solitary thyroid nodule are Primary thyroid cancer, dominant nodule of a nodular colloid goiter, Functioning nodules, Nonfunctioning adenoma, Cyst, Thyroid lymphoma, Cancer metastasizing to the thyroid and Hashimoto's Thyroiditis. Evaluation consists of whether the nodule is autonomously functioning and possibly causing hyperthyroidism or has high risk of malignancy. Nodules with high risk of malignancy require surgery whereas benign can be followed up. FNAC is the most accurate test for the evaluation of solitary thyroid nodules. Still, The major pitfalls are inability to distinguish follicular adenomas from follicular carcinomas, as carcinomas require to reveal vascular or capsular invasion of the adenoma and Specimen inadequacy especially in cystic lesions were cystic malignancies can be a problem. Degirmenci et al. reported that the highest specimen adequacy rate was observed among nodules smaller than 1 cm (76.4%) and the lowest rate was observed among nodules larger than 3 cm (56.9%). They inferred that the lower rate in larger nodules probably resulted from increased vascularity and the larger size of blood vessels, with resultant blood staining of the material acquired at fine needle aspiration (6). Scott N. Pinchot et al. recommended that diagnostic lobectomy be strongly considered in patients with thyroid nodules 4 cm or larger regardless of FNAB cytologic test results [7]. A possible way to reduce such error is to do aspirations from different parts which could reveal the typical nuclear features of papillary carcinoma [8]. FNAC has high sensitivity and specificity for predicting thyroid malignancies averaging 83% and 92% respectively (9, 10). In our study, the sensitivity and specificity was 56.30 % and 98.10% respectively. The diagnostic accuracy was 93 %. 2 cases of papillary microcarcinoma was not made out by FNAC, but detected only by histopathology. This may be one of the reasons for the reduced sensitivity; other probable reasons may be inadequate or non-representative samples as all the procedures were done without ultrasound guidance. It is anticipated that improvement in diagnosis will develop from specific cytopathological training in thyroid FNAC, consideration of the cytopathologist performing the aspiration biopsy, and the development of immuno histochemical and molecular techniques applied to the cytologic smears. Thyroid nodules that are sclerotic or calcified and those with large areas of cystic degeneration or necrosis are

extremely difficult to aspirate. The advent of ultrasound guided FNAC improved specimen acquisition, especially in patients with small thyroid nodules or nodule that are difficult or impossible to detect on physical examination (11-13).

CONCLUSION

- In our study, the sensitivity of FNAC was low as compared with other studies.
- The PPV of FNAC was high, meaning false positives are uncommon in those who screen positive.
- The NPV of FNAC was high, meaning false negatives are rare in those who screen negative, suggesting a potentially useful test in the initial evaluation of thyroid nodules.
- LH ratio for positive test was high, meaning that the test is more indicative of malignancy. It is good in ruling-in malignancy
- LH ratio for negative test was not very low, meaning that it is more likely the negative test result to occur in a patient than in a subject without disease. It is not good in ruling-out malignancy.
- The diagnostic effectiveness or diagnostic accuracy was very high. It means that the overall value of FNAC in detecting malignancy as a combined screening and case-finding test is good.
- The assessment of the patient with a thyroid nodule includes the triple modalities of clinical examination, cytology and imaging investigations. The result of thyroid aspiration cytology is therefore only one factor governing the management decision. Indeterminate FNAC results and cytodiagnostic errors are unavoidable due to overlapping cytological features particularly among hyperplastic adenomatoid nodules, follicular neoplasms and follicular variants of papillary carcinomas.
- Correlation of cytology and histology is an important quality assurance measure and it allows laboratories to calculate their false positive and false negative rates.
- We conclude that FNAC is an invaluable and minimally invasive procedure for pre-operative assessment of patients with a thyroid nodule. FNAC has high accuracy in the diagnostic evaluation of thyroid nodule.

ACKNOWLEDGEMENT AND SOURCE OF FUNDING – Nil

REFERENCES

[1] S. A. Roman, “Endocrine Tumors. Evaluation of Thyroid Nodule,” Current Opinion in Oncology, Vol. 15, No. 1, 2003, pp. 66-70.

[2] H. K. Zygnunt, “The Thyroid Gland and Thyroglossal Tract: Short Practice Of Surgery,” 24th Edition, Arnold, London, 2004, pp. 784-786. [3]

[3] U. Handa, S. Garg, H. Mohan and N. Nagarkar, “Role of Fine Needle Aspiration Cytology in the Diagnosis and Management of Thyroid Lesions: A Study on 434 Patients,” Journal of Cytology, Vol. 25, No. 1, 2008, pp. 13-17. [5] 7

[4] E. S. Cibas and E. Z. Ali, “The Bethesda System for Reporting Thyroid Cytopathology,” Thyroid, Vol. 19, No. 11, 2009, pp. 1159-1165.

[5] Orell and Sterret’s Fina Needle Aspiration Cytology, Fifth Edition, Pages 118-121.

[6] B.Degirmenci, A. Haktanir, R. Albayrak, M. Acar, D. A. Sahin, O. Sahin, A. Yucel and G. Caliskan, “Sonographically Guided Fine-Needle Biopsy of Thyroid Nodules: The Effects of Nodule Characteristics, Sampling Technique, and Needle Size on the Adequacy of Cytological Material,” Clinical Radiology, Vol. 62, No. 8, 2007, pp. 798-803.

[7] S. N. Pinchot, H. Al-Wagih, S. Schaefer, R. Sippel and H. Chen, “Accuracy of Fine-Needle Aspiration Biopsy for Predicting Neoplasm or Carcinoma in Thyroid Nodules 4 cm or Larger,” Archives of Surgery, Vol. 144, No. 7, 2009, pp. 649-655. http://dx.doi.org/10.1001/archsurg.2009.116

[8] X. J. Cai, N. Valiyaparambath, P. Nixon, A. Waghorn, T. Giles and T. Helliwell, "Ultrasound-Guided Fine Needle Aspiration Cytology in the Diagnosis and Management of Thyroid Nodules," Cytopathology, Vol. 17, No. 5, 2006, pp. 251-256.

[9] M. Bouvet, J. I. Feldman and G. N. Gill, "Surgical Management of the Thyroid Nodule: Patient Selection Based on the Results of Fine-Needle Aspiration Cytology," Laryngoscope, Vol. 102, No. 12, 1992, pp. 1353-1356.

[10] J. Cap, A. Ryska, P. Rehorkova, E. Hovorkova, Z. Kerekes and D. Pohnetalova, "Sensitivity and Specificity of the Fine Needle Aspiration Biopsy of the Thyroid: Clinical Point of View," Clinical Endocrinology, Vol. 51, No. 4, 1999, pp. 509-515.

[11] Safirullah, Naeem Mumtaz, Akbar Khan. Role of Fine Needle Aspiration Cytology (FNAC) in the diagnosis of Thyroid swellings. J Postgrad Med Inst 2004; 18(2): 196- 201.

[12] Leenhardt L, Hejblum G, France B, et al Indications and limits of ultrasound guided cytology in the management of non-palpable thyroid nodules. J Clin Endocrine Metab, 1999; 84: 24-8

[13] Mittendorf EZ, tamarkin SW, Mc Henry CR. The results of ultrasound guided fine needle aspiration biopsy for evaluation of nodular. Thyroid disease Surgery 2002; 132: 648 – 54.