International Journal of Allied Medical Sciences and Clinical Research (IJAMSCR)

IJAMSCR |Volume 3 | Issue 2 | April-June- 2015
www.ijamscr.com

Case report Medical research

A rare case of aldosteron-secreting giant adrenal carcinoma: A case report and review of literature

***Mehtap Evran, Gamze Akkuş, Murat Sert, Tamer Tetiker**

[1]*Asist. Prof., Cukurova University Medical Faculty, Department of Internal Medicine, Division of Endocrinology, 01330 Adana / Turkey*

***Corresponding author: Mehtap Evran**

E-mail: mehtap.evran@hotmail.com

ABSTRACT

İNTRODUCTİON

Primary aldosteronism is the most common and curable form of secondary hypertension with on estimated prevalence of 10% in referred patients, and 4% in primary care. Primary aldosteronism is presented with signs of hypertension and hypokalemia classically.

CASE PRESENTATİON

A 46 years old male patient was referred to our hospital with weakness, dry mouth and weight loss. He was hypertensive at out-of-office measures as grade II according to last guidelines. The patient was hospitalized to service as primer hyper aldosteronism however adrenocortical carcinoma with distant metastases was detected.

CONCLUSİON

We presented a case of a man who had isolated aldosterone-producing adrenal cortical carcinoma. This is very rare case and also clinicians should be aware that primary hyperaldosteronism can occur in the context of adrenocortical carcinoma.

KEY WORDS: Adrenocortical carcinoma, Aldosteron, Metastasis, Hypertension

INTRODUCTİON

Primary aldosteronism is the most common and curable form of secondary hypertension with on estimated prevalence of 10% in referred patients, and 4% in primary care however can be diagnosed as high as 20% in patients with resistans hypertension [1]. It is usually presented with signs of hypertension and hypokalemia classically [2-5]. Primary aldosteronism is usually diagnosed in third to sixth decade of life period. Patients with severe hypokalemia may have suffer from muscle weakness and cramping, headaches, palpitations, polydipsia, polyuria, nocturia, or combination of these. Adrenocortical carcinoma (ACC) is rarely diagnosed and believed to be highly aggressive type of cancer with an incidence of one to two per million annually [6-8]. Moreover a hıgher incidence of ACC has been reported in females. ACC is associated with a bimodal age distribution. Two peaks are reported: first one is represented in children in the first decade of life and the other one is in fourth to fifth decades of life [9,10]. The patients with hormone producing ACC s usually present with Cushing's syndrome alone (45%) or a mixed Cushing's and virilization syndrome overproduction of both glucocorticoids and

androgen (% 25) [7]. Aldosteron secretion is a only 10 per cent of the ACC s patients (9). Five year survival is approximately 45-60% for early stage disease and 10-25% for advanced stage disease. We aimed to present a patient patient with a metastatic adrenal carcinoma after the primary diagnosis of hyper aldosteronism.

CASE PRESENTATİON

A 46 years old male patient with no known disease was referred to our hospital with weakness, dry mouth and weight loss. He had lost weight as 31 pounds during last three months. Moreover nocturia, poliuria , weakness , fatigue and edema in leg were developed . Physical examination revealed diffuse crackles in lungs. Cardiovascular system, gastrointestinal system, head and neck examination was found normal without any organomegaly or lymphadenopathy. However, pretibial edema was profoundly positive. Arterial tension was measured at 170/100 mmHg at admission. Differential diagnosis was planned on uncontrolled hypertension and persistant hypokalemia with elevated aldosterone levels and low renin levels as 753 ng/dL (normal, 3-28 ng/dL) and 0.57 ng/ml/h (normal range, 0.65-5 ng/ml/h), respectively. Biochemical parameters at admission were summarized in Table 1.

Table 1. Biochemical parameters at admission

BUN: 16 mg/dl	Na: 140 mEq/dl	WBC: 11 x 103 uL	pH:7.46
Creatinin: 0,9 mg/dl	K:1.9 mEq/dl	Hb: 12 g/dl	pCO2: 36
AST: 62 U/L (0-45 U/L)	T. Protein: 5.7 g/dl	Htc: % 37	pO2: 46
ALT: 87 U/L (0-35 U/L)	Albumin: 2.5 g/dl	Plt: 291 x 103 uL	HCO3: 25.4

Electrocardiogram revealed U waves with sinüs rythm. Potassium replacement was initiated at the first place of our therapy. The control potassium was 3.1 meq/dl. Doxazosin 8mg /day with aldactone 100 mg/day was started. The cortisol and ACTH values were measured as 21.93 mcg/dl and 5.93 pg/ml; respectively. Supression was established with 1 mg dexamethasone supression test protocole. Urine pH was found 6,5 and primary aldosteronism was considered as pre-diagnosis. Diffuse-patchy nodular opacities was determined in Chest X-Ray, bilaterally (Figure 1). Thorax-Abdominal CT was performed. Bilateral diffuse nodules (biggest was nearly ~2.5 cm) in lungs were consisted with metastatic cancer (Figure 2). A giant mass with 12 cm diameter in suprarenal region, which involves liver partially, consisted with adrenal gland tumor was determined (Figure 3).

Figure 1. Bilateral diffuse-patchy nodulary opacities in Chest X-Ray.



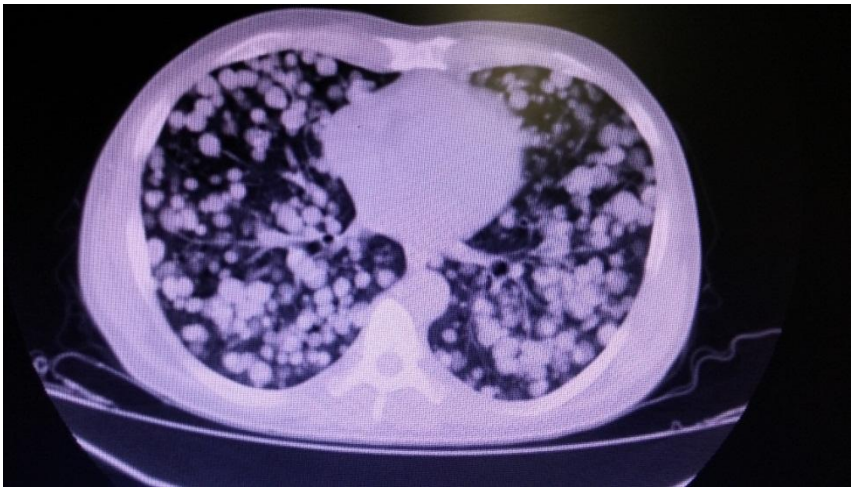

Figure 2: Detailed view of patchy metastatic nodular infiltration in computerized tomography of Lung. Black arrows indicate diffuse metastatic formations.

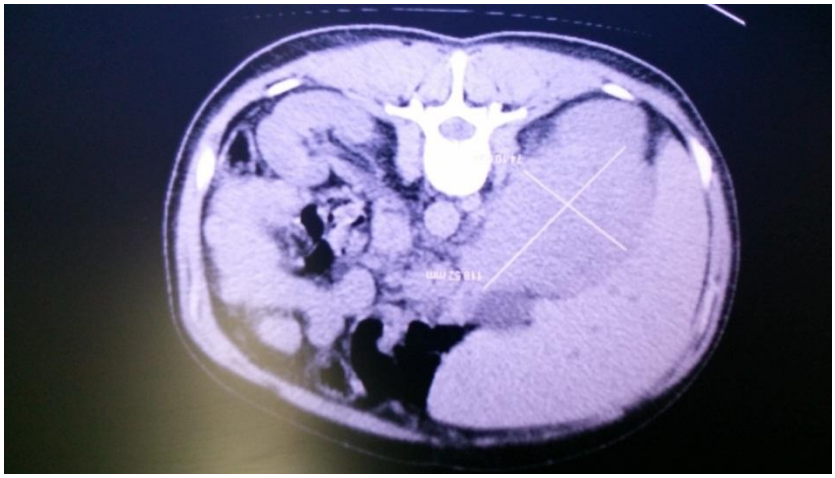

Figure 3: Tumoral formation in abdominal computerized tomography. Suprarenal mass was thought to be originate from surrenals with diameter of nearly 12 cm. Black arrow indicates the tumoral formation.

Bronchoscopy was performed and miliary tuberculosis ruled out. Transthorasic echocardiography revealed slight mitral insufficiency, the left ventricle diastolic dysfunction as stage I, and minimal pericardial effusion. Metastatic multiple hyper-metabolic lesions in lungs and hyper-metabolic mass in surrenal region were detected in positron emission tomography. Fine needle aspiration biopsy was performed from right surrenal mass with CT scan. Pathology revealed ACC. Chemotherapy (mitotane) was the chosen treatment because of the distant metastases. Patient died during the chemotheraphy.

DİSCUSSİON

Primary aldosteronizm is first described in 1955. The syndrome includes hypertension, suppressed plasma renin activity (PRA), and increased aldosteron excretion [5]. Previously, clinicians would not consider the diagnosis of primary aldosteronism unless the patient presented with hypokalemia, and then the diagnostic evalution would require discontinuation of antihypertensive medications for at least 2 weeks. However, it is now recognized that most patients with primary aldosteronism are not hypokalemic [4-11] and that screening can be completed while the patient is taking anti-

hypertensive drugs with a simple blood test that the ratio of plasma aldosterone concentration (PAC) to PRA [12,13]. The diagnostic approach to primary aldosteronism can be considered in three phases: case- detection tests, confirmatory tests, and subtype evaluation tests. Case detection test is a measurement of PAC and PRA in a random morning ambulatory blood sample (preferably obtained between 8 and 10 a.m). Primary aldosteronism should be suspected if the PRA is suppressed (1.0 ng/ml per hour) and the PAC (> 15 ng/dl) is increased. Primary aldosteronism subtype evaluation may require one or more tests, the first of which is imaging of the adrenal glands with CT. Aldosteron Producing Adenoma are usually hypodense nodules (<2 cm in diameter) on CT and golden yellow in color when resected. Adrenal glands may be normal on CT or may show noduler changes in idiopathic hyper aldosteronism (IHA). Aldosteron-producing adrenal carcinomas are almost always larger than 4 cm in diameter and have homogeneous phenotype on CT [14,15]. Likewise, in our case, the tumor diameter size was 12 cm. Adrenocortical carsinomas (ACCs) are thought to be very rare with incidence of approximately one or two per million population per year [16]. Although most cases of ACCs appear to be sporadic, some have been related as a component of several hereditary syndromes (Li-Fraumeni Syndrome, Beckwith-Wiedemann Syndrome etc.). Approximately 60 percent of ACCs are sufficiently to present syndrome of hormone excess [17]. In our case, high isolated aldosteron level was detected.

The overall ACCs of distant metastases are the liver, lungs, lymph nodes and bone. In our case lungs metastases was detected (Figure 1). Nowadays, standard therapy for ACC is complete surgical resection and adjuvant mitotane therapy in patients with resectable disease. Combination chemoterapy should be considered in patients with unresectable or metastatic disease [18-21]. Recurrence rates are high after surgical resection. In general, hyper aldosteronism is most frequently secondary to an aldosterone-producing adrenal adenoma (APAC) or adrenal hyperplasia. Accordingly the rarity of APAC might explain the lack of information on biological behavior, clinical features, natural history and survival of APAC patients. To our knowledge only 60 cases have been reported in literature, including our case. In the study of Seccia et al. the patients with preliminary diagnosis of Conn was analyzed. Moreover 10% of patients was found to have metastatic disease at time of diagnosis. 56% of patients was found to have hypokalemia with nearly 70 mm tumoral diameter at the time of diagnosis [22].

CONCLUSİON

Primary adrenal carcinoma is very rare with annual incidence of 1 per 1 million population. Current treatment choices for what is often an aggressive tumor are poor. We presented a case of a man who had isolated aldosterone-producing adrenal cortical carcinoma. Also clinicians should be aware that primary hyperaldosteronism can occur in the context of adrenocortical carcinoma.

İNFORM CONSENT

Written informed consent has been obtained from the patient for publication of the case report.

CONFLİCT OF İNTEREST

The authors declare that there is no conflict of interest that could be perceived as prejudicing the impartiality of the research reported.

REFERENCES

[1] Zennaro MC, Boulkroun S, Fernandes-Rosa FL. An update on novel mechanisms of primary aldosteronizm. Journal of Endocrınology, 2014; 224(2): 63-77.

[2] Conn JW. Aldosterone in clinical medicine; past, present, and future. AMA Arch Intern Med, 1956; 97: 135.

[3] Mattsson C, Young WF Jr. Primary aldosteronism: diagnostic and treatment strategies. Nat Clin Pract Nephrol, 2006; 2: 198.

[4] Young WF. Primary aldosteronism: renaissance of a syndrome. Clin Endocrinol (Oxf), 2007; 66: 607-18.

[5] Conn JW. Presidental address. Part I: Painting background. Part II: Primary Aldosteronism, a new clinical syndrome. J Lab Clin Med, 1955; 45: 3-17.

[6] Lacroix A. Approach to the patient with adrenocortical carcinoma. J Clin Endocrinol Metab, 2010; 95: 4812–22.
[7] Zini L, Porpiglia F, Fassnacht M. Contemporary management of adrenocortical carcinoma. Eur Urol, 2011; 60: 1055–1065.
[8] Fassnacht M, Libé R, Kroiss M, Allolio B. Adrenocortical carcinoma: a clinician's update. Nat Rev Endocrinol, 2011; 7: 323–35.
[9] Ng L, Libertino JM. Adrenocortical carcinoma: diagnosis, evaluation and treatment. J Uro, 2003;169: 5–11.
[10] Roman S. Adrenocortical carcinoma. Curr Opin Oncol, 2006; 18: 36–42.
[11] Funder JW, Carey RM, Fardella C, et al. Case detection, diagnosis, and treatment of patients with primary aldosteronism: an endocrine society clinical practice guideline. J Clin Endocrinol Metab, 2008; 93: 3266-81.
[12] Dunn PJ, Espiner EA. Outpatient screening tests for primary aldosteronism. Aust N Z J Med, 1976; 6: 131-5.
[13] Schwartz GL, Turner ST. Screning for primary aldosteronism in essential hypertension: diagnostic accuracy of the ratio of plasma aldosterone concentration to plasma renin activity. Clin Chem, 2005; 51: 386-94.
[14] Weinberger MH, Fineberg NS. The diagnosis of primary aldosteronism and separation of two majör subtypes. Arch Intern Med, 1993; 153: 2125-9.
[15] Young WF, Stanson AW, Thompson GB, et al. Role for adrenal venous sampling in primary aldosteronism. Surgery, 2004; 136: 1227-35.
[16] Allolio B, Fassnacht M. Clinical Review: Adrenocortical carcinoma: clinical update. J Clin Endocrinol Metab, 2006; 91: 2027.
[17] Wajchenberg BL, Albergaria Pereira MA, Medonca BB, et al. Adrenocortical carcinoma: clinical and laboratory observations. Cancer, 2000; 88: 711.
[18] Fassnacht M, Kroiss M, Allolio B. Update in adrenocortical carcinoma. J Clin Endocrinol Metab, 2013; 98: 4551–64.
[19] Fassnacht M, Terzolo M, Allolio B, et al. Combination chemotherapy in advanced adrenocortical carcinoma. N Engl J Med, 2012; 366: 2189–97.
[20] Habra MA, Ejaz S, Feng L, et al. A retrospective cohort analysis of the efficacy of adjuvant radiotherapy after primary surgical resection in patients with adrenocortical carcinoma. J Clin Endocrinol Metab, 2013; 98: 192–7.
[21] Terzolo M, Angeli A, Fassnacht M, et al. Adjuvant mitotane treatment for adrenocortical carcinoma. N Engl J Med, 2007; 356: 2372–80.
[22] Seccia TM, Fassina A, Nussdorfer GG, Pessina AC, Rossi GP. Aldosterone-producing adrenocortical carcinoma: an unusual cause of Conn's syndrome with an ominous clinical course. Endocr Relat Cancer, 2005; 12: 149–159.