International Journal of Allied Medical Sciences and Clinical Research (IJAMSCR)

***IJAMSCR |Volume 3 | Issue 2 | April-June- 2015***
**www.ijamscr.com**

*Case report* *Medical research*

# A rare case of solitary plasmacytoma of rib with pleural effusion, unusual presentation

**Dr. Gunjan S. Loney*, Dr. Kalpana A. Bothale, Dr. Sadhana D. Mahore, Dr. Aliya Niyazi, Dr. Akanksha Bothale**

*Resident, Associate professor, Professor and HOD, Resident, Resident (Pathology department)*
*N. K. P. Salve Institute of Medical Sciences and Research Centre, Nagpur- 440019.*

***Corresponding author: Gunjan S. Loney**

**E-mail id: gsloney@gmail.com**

## ABSTRACT

Solitary plasmacytoma of bone (SPB) is a rare localized lesion that accounts for only 4% of malignant plasma cell tumors. The rib involvement is still rare. We report a case of unsuspected solitary plasmacytoma of rib and subsequent pleural effusion in a 65 year old male patient. The finding of many plasma cells in the pleural fluid cytology led to the diagnosis of SPB. Pleural effusion due to myelomatous involvement is very rare, occurring in less than 1% of patient. Therefore we are reporting this case for its rarity and unusual presentation.

**Keywords -** plasmacytoma, rib, solitary plasmacytoma, pleural effusion.

## INTRODUCTION

We report a unique case of unsuspected plasmacytoma of rib. Plasmacytomas are localized neoplasms characterized by clonal proliferation of plasma cells that display variable morphologic features ranging from bland and mature to anaplastic forms.[1] Plasmacytoma may be primary or secondary to the disseminated multiple myeloma and may arise from the osseous (medullary) or non-osseous (extramedullary) sites. Solitary plasmacytoma is rare as compared with multiple myeloma. Solitary bone plasmacytoma (SPB) is a rare localized lesion that accounts for only 4% of malignant plasma cell tumors.[2] The axial skeleton is the most common location for osseous lesions.[1]

## CASE REPORT

A 65 year old chronic smoker male presented with a diffuse mass in right lateral chest wall. He complained of cough with expectoration, fever, breathlessness since 15 days. General examination revealed mild pallor, icterus and clubbing. On systemic examination, centrally placed trachea, bilateral crepitations and occasional ronchi were appreciated. On local examination, there was a firm, non tender, diffuse swelling of size 10 x 5 cm on the lateral aspect of right chest wall which was fixed to the chest wall but free from skin (fig.1).



**Fig. 1Clinical photograph showing diffuse swelling on lateral aspect of right side of chest wall.**

Clinical diagnosis of soft tissue sarcoma was offered. Routine haemogram showed hemoglobin 9 gm/dl and total and differential leucocyte counts were within normal limits. Serum calcium was normal. Chest x ray was done which showed right sided massive pleural effusion and lytic bone lesion in 8$^{th}$ rib (fig.2).

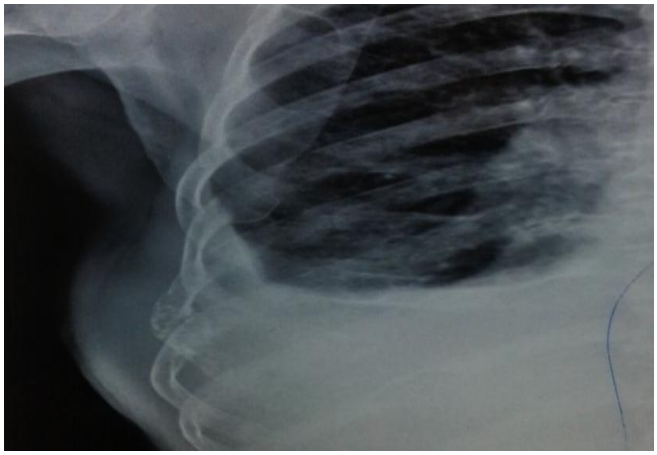

**Fig. 2 - Chest X ray PA view showing right sided pleural effusion and large extra pulmonary opacity with well defined margin and lytic lesion in the mid-part of 8$^{th}$ rib.**

Ultrasonography thorax revealed moderate free fluid in the right pleural cavity with underlying lung collapse. Therefore, pleural fluid tapping was done. Papanicolaou and Hematoxylin & Eosin stained smears of centrifuged pleural fluid revealed many plasma cells, some of which were binucleate (fig3). In view of presence of many plasma cells, possibility of plasmacytoma was considered.




**Fig. 3 Contrast-enhanced computed tomography of the chest revealing lytic lesion of 8$^{th}$ rib.**

In the meanwhile, patient underwent computed tomography (CT) thorax which was suggestive of lytic lesion in the mid-part of 8th rib and significant soft tissue component on lateral aspect of 8th and 9th ribs on the right side (fig4).

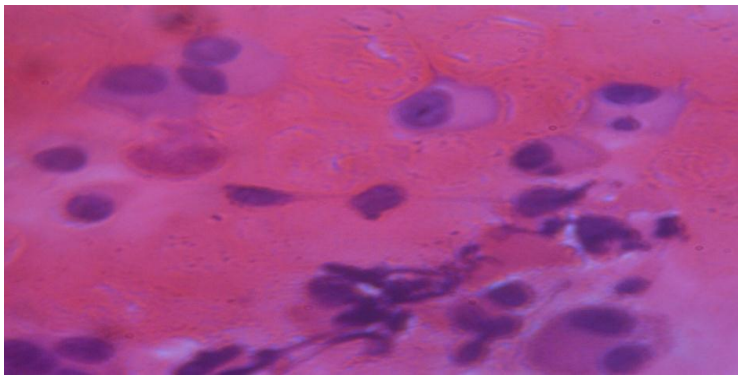

**Fig. 4 Smear of pleural fluid showing many plasma cells including some binucleate forms (H & E, X1000)**

Thereafter, fine needle aspiration cytology from right lateral thoracic wall swelling was done which revealed many plasma cells with eccentric round nuclei with clumped chromatin and moderate amount of cytoplasm. Few cells showed binucleation and perinuclear 'hof' (fig5).

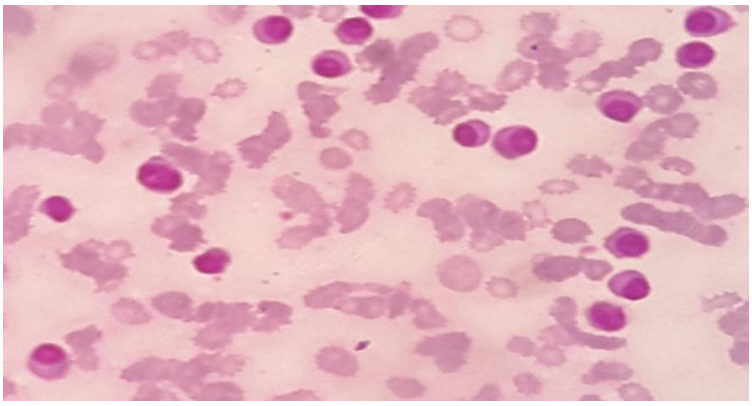

**Fig. 5 Photomicrograph of fine needle aspiration from chest swelling showing many plasma cells with eccentric nucleus and perinuclear 'hof' (H & E, X 400)**

On fiber-optic bronchoscopy, there was no evidence of any growth in the bronchus. X ray skull and vertebrae appeared normal. Then the patient underwent bone marrow aspiration which revealed normal haematopoiesis. There was no increase in the number of plasma cells in bone marrow. Serum and urine electrophoresis and kidney function tests were within normal limits.

## DISCUSSION

Solitary plasmacytoma may be an isolated disease or the first manifestation of a multiple myeloma.[3] The isolated form of plasmacytoma seems to have a better prognosis.[4] The most common symptom of SBP is pain at the site of the skeletal lesion due to bone destruction by the infiltrating plasma cell tumor.[6] In our case, there was a diffuse painful swelling. SBP may involve any bone. Spinal disease is observed in

34-72% of cases. The thoracic vertebrae are most commonly involved, followed by lumbar, sacral, and cervical vertebrae.[7] The rib, sternum, clavicle, or scapula is involved in 20% of cases.[8] Singhal et al reported a rare case of solitary plasmacytoma of rib.[9] A solitary plasmacytoma in a rib usually shows destruction of the bone cortex with extension into the surrounding soft tissues.[10] In our case also, there was destruction of rib with extension into surrounding soft tissues.

Criteria for identifying SBP vary among authors.[11] The currently accepted criteria are as follows:- [6,7]

- Single area of bone destruction due to clonal plasma cells
- Bone marrow plasma cell infiltration not exceeding 5% of all nucleated cells
- Absence of osteolytic bone lesions or other tissue involvement (no evidence of myeloma)
- Absence of anemia, hypercalcemia, or renal impairment attributable to myeloma
- Low, if present, concentrations of serum or urine monoclonal protein
- Preserved levels of uninvolved immuno-globulins.

Our patient was unusual in that he presented with pleural effusion. Pleural effusion occurs in around 6% of patients with myeloma, and aetiology is multifactorial. Pleural effusion due to myelomatous involvement is rare, occurring in <1% of cases.[12] Unilateral pleural effusion as a presentation of unsuspected multiple myeloma has not been reported. Presence of plasma cells in pleural effusion is uncommon. So our case is extremely rare. It draws attention to the fact that the presence of many plasma cells in the pleural fluid is not always a sign of the more frequent multiple myeloma. SBP develops into multiple myeloma in 50-60% of patients.[13] Some have postulated that SBP may be considered an intermediate step in the evolution from monoclonal gammopathy of undetermined significance to multiple myeloma.[6] Median overall survival time is 10 years.[14] Although levels are lower than in multiple myeloma, electrophoresis reveals a monoclonal protein in the serum or urine in 24-72% of patients. In a series of 46 patients by Galieni and colleagues, all patients had normal uninvolved immunoglobulins.[13] Local radiotherapy is the treatment of choice.[6,7] Local control is achieved in 88-100% of patients. Virtually all patients have major symptom relief and a local tumor recurrence rate approximately 10%.[14] Surgery is contraindicated in the absence of structural instability or neurologic compromise. Chemotherapy may be considered for patients not responding to radiation therapy. Regimens useful in multiple myeloma can be considered.[15] Periodic evaluation for progression and development of multiple myeloma is recommended every 6 weeks for the first 6 months.

Our patient was treated with radiotherapy for 5 weeks. Both the chest wall swelling and the pleural effusion progressively improved without conversion to myeloma. Thereafter, patient lost the follow up.

## CONCLUSION

In the reviewed literature, myelomatous pleural effusion is rare. It is usually seen in late course of the disease. The finding of many plasma cells in the pleural fluid led to the diagnosis of plasmacytoma.. Every case of pleural effusion should be investigated thoroughly to rule out such rare diagnosis.

## REFERENCES

[1] McKenna RWKR, Kuehl WM, Grogan TM, Harris NL, Coupland RW. Plasma cell neoplasms. In: Swerdlow SH, Campo E, Harris NL, Jaffe ES, Pileri SA, Stein H, et al., editors. WHO Classification of Tumors of Hematopoietic and Lymphoid Tissues. Lyon: IARC; 2008.

[2] Goel G, Rai S, Naik R, Gupta A, Baliga P, Sinha R. Cytodiagnosis of extra medullary plasmacytomas. ActaCytol 2010;54:255-8.

[3] Kadokura M, Tanio N, Nonka M, Yamamoto S, Kataoka D, Kushima M, et al. A Surgical case of solitary plasmacytoma of rib origin with biclonalgammopathy.Jpn J ClinOncol 2000;30:191-5.

[4] Di Micco P, Niglio A, Torella R, Di Micco B. Solitary plasmacytoma of the jaw occurring in a elderly woman affected by hepatitis C virus infection: a case report. Tumori 2002; 88: 421-4.

[5] Ferrer AC, Ferrer AE, Fernandez IA, Pinzo BJ, Ramos FV, Rancho TR. Solitary plasmacytoma of the mandibole. Report of one case and review of the literature. A Otorrinolaringollbero Am 1995; 22: 609-18.

[6] Dimopoulos MA, Moulopoulos LA, Maniatis A, Alexanian R. Solitary plasmacytoma of bone and asymptomatic multiple myeloma. Blood.2000;96(6):2037-44.
[7] Dimopoulos MA, Kiamouris C, Moulopoulos LA. Solitary plasmacytoma of bone and extramedullary plasmacytoma. Hematol Oncol Clin North Am. 1999;13(6):1249-57.
[8] Burt M, Karpeh M, Ukoha O, et al. Medical tumors of the chest wall. Solitary plasmacytoma and Ewing's sarcoma .J Thorac Cardiovasc Surg.1993;105(1):89-96.
[9] Singal R, Dalal U, Dalal AK, Attri AK, Gupta S, Raina R. Solitary plasmacytoma of the rib: A rare case. Lung India 2011;28:309-11.
[10] Singh A, Patel R, Singh A, Patel R, Devgarha S, Mathur RM. Solitary plasmacytoma of rib in a young adult- a rare case report. IOSR-JDMS. 2014;13:56-59.
[11] McLain RF, Weinstein JN. Solitary plasmacytomas of the spine: a review of 84 cases. J Spinal Disord.1989;2(2):69-74.
[12] Diebold J. World Health Organization classification of malignant lymphomas. ExpOncol 2001; 23: 101-3.
[13] Galieni P, Cavo M, Avvisati G. Solitary plasmacytoma of bone and extra medullary plasmacytoma: two different entities? Ann Oncol. 1995;**6**:687-691.
[14] Hu K, Yahalom J. Radiotherapy in the management of plasma cell tumors. Oncology (Williston Park).2000;14(1):101-8, 111; discussion 111-2, 115.
[15] Soutar R, Lucraft H, Jackson G, et al. Guidelines on the diagnosis and management of solitary plasmacytoma of bone and solitary extramedullary plasmacytoma. Clin. Oncol (R CollRadiol). 2004;16(6):405-13.