ISSN: 2347-6567

*International Journal of Allied Medical Sciences and Clinical Research (IJAMSCR)*

*IJAMSCR |Vol.12 | Issue 2| Apr - June -2024*

**www.ijamscr.com**

DOI : https://doi.org/10.61096/ijamscr.v12.iss2.2024.135-140

**Research**

# Calcaneal-Cuboid-Cuneiform Osteotomy In The Treatment of Flexible Flatfoot in Children About 21 Patients

**Amel Djerbal[1*], Kenza Badache[2], Samir Tebani[1], Mustapha Noumi[3], Yousria Akloul[1], Reda Harrar[1]**

*[1]Faculty of Medicine, University of Algiers I, Specialized Hospital Establishment Salim Zemirli, El Harrach, Algiers*
*[2]Faculty of Medicine, University of Algiers I, University Hospital Center of Algiers, Hospital of Algiers Mustapha*
*[3]Faculty of Medicine, University of Algiers I, University Hospital Center of Algiers, Hospital of Algiers Mustapha*

*Author for Correspondence: Amel Djerbal
Email: djerbalamel@gmail.com

Published on: 13 May 2024

Published by:
DrSriram Publications

2024| All rights reserved.

Creative Commons Attribution 4.0 International License.

## Abstract

New therapeutic approach for idiopathic reducible severe valgus flatfoot, symptomatic of children and adolescents, which respects the growth and joint mobility of the foot. Extra-articular corrective osteotomies associated with gestures on the soft parts are the treatment of choice to restore the morphology and biomechanics of the foot and avoid early joint deterioration. The calcaneal-cuboid-cuneiform osteotomy, extra-articular osteotomy is the treatment current ideal of idiopathic reducible severe valgus flatfoot of the child and the teenager. The deformation of the foot is corrected while maintaining mobility. Conceptualized by Rathjen and Mubarak (JPO 1998). This technique is described under the name 3C osteotomy by the Anglo-Saxons: a closure osteotomy (subtraction based medial) associated with a medial translation of the Calcaneus, a closure osteotomy plantar or pronation of the medial Cuneiform and an osteotomy of opening of the Cuboid to restore the alignment of the forefoot and the midfoot. For the sake of refinement, efficiency of surgical procedures and improvement of the final result both aesthetically and functionally, we propose a strategy less aggressive surgery on immature bones that are still growing.

**Keywords:** Flatfoot, idiopathic, Osteotomy, 3C, Extra-articular.

## INTRODUCTION

The calcaneal osteotomy of medial translation of the posterior tuberosity described by Koutsogiannis [1] realigns the hindfoot under load, but does not correct the plantar flexion of the talus. Rathjen and Mubarak [2] have made modifications to this technique by associating with it two other osteotomies respectively of the cuboid and the medial cuneiform. The 3C osteotomy, this technique is described under the name of 3C

osteotomy by the Anglo-Saxons: a closure osteotomy (subtraction with a medial base) associated with a medial translation of the calcaneus, a plantar closure osteotomy or pronation of the medial cuneiform and a cuboid opening osteotomy to restore the alignment of the forefoot and the midfoot. This intervention seems to be the method of choice if the talus is not in excessive plantar flexion and if the naviculum is not translated outside.

## MATERIALS AND METHODS

34 patients (21 patients) treated with 3C osteotomy combining a medial valgization-translation osteotomy of the Calcaneus, an opening osteotomy of the Cuboid and a plantar closure osteotomy of the first Cuneiform. Regardless of the surgical procedure, all patients benefited from an elongation of the Achilles Tendon (TA), the Short Fibular (CF) according to the Vulpus technique, a TN capsulography and a transposition with advancement of the posterior tibialis (TP).The 34 feet are all operated on by the same orthopedic surgeon who masters this surgical process. The clinical and radiological results at the end of growth were analyzed and compared. Boys were considered to be at the end of lower limb growth after the age of 15 and girls after the age of 13. The clinical examination, the subjective assessment of the quality of life, according to the KITAOKA scores (AOFAS). Study inclusion criteria All reducible severe idiopathic valgus flatfoot (RSIFF) and symptomatic. All these RSIFF have been classified 3rd degree according to the classification of the impression on the podoscope. Criteria for exclusion from the study all malformative, neurological, post-traumatic RSIFF or associated with tarsal synostosis. Opening of a specialized consultation for valgus flatfoot to receive, examine patients and follow up on operated patients. Imaging: X-rays of the feet according to a protocol, 2D and 3D CT, MRI. Iconography: digital camera, computer. The preoperative and postoperative radiographic examinations included load-bearing incidences of both feet of face and profile to evaluate five radiological parameters: the talo-calcaneal divergence (TCD), the talo-navicular coverage angle, the talus-M1 angle or Meary angle, the slope of the calcaneus (calcaneal pitch) and the angle of the talus with the horizontal (talus-H). Interrogation Methods It was based on the search for: the unusual wear of shoes, or a family history of difficulties in putting on shoes or soles during childhood. In older children or adolescents, we are looking for the gait in external rotation associated with a certain difficulty in sports practice and pain. Clinical examination it is done on an undressed child. It includes a global gait analysis, a dynamic and static examination with uni and bipodal support, clinical reducibility tests, a muscle testing and an analysis of plantar impressions under load (podoscope) (Figure 1). It is supplemented by a neurological examination. The reducibility of the deformation of the foot is rigorously evaluated compartment by compartment: the tibialis-talian joint (Achilles Tendon) in particular the dorsal flexion by correcting the valgus and blocking the hindfoot in the neutral position to evaluate the retraction of the Achilles Tendon (TA), the midfoot joint and its valgus for the Short Fibular tendon (CF), and the Posterior Tibialis tendon (PT) and the forefoot joint for supination and pronation. Imagerythe per and postoperative radiographic examinations included load-bearing incidences of face and profile to evaluate (Figure 2): the talo-calcaneal divergence (TCD), the talo-navicular coverage angle, the talus-M1 angle or Meary angle, the slope of the calcaneus (calcaneal pitch) and the angle of the talus with the horizontal (talus-H). The consolidation or not of the osteotomies, the integration or not of the cortico-spongy grafts of interposition. The joint ratios of the torsional torque and their modifications. The growth disorders of the talian dome or the navicular: ossifications, deformations and osteonecrosis. Signs of torsional torque arthrosis. Gestures on the soft parts they are represented by: An elongation of the calcaneal tendon (TA) of the Vulpus type or fasciotomy of the twins in order not to weaken it, an elongation of the short fibular tendon of the Vulpus type. A talo-navicular capsuloraphy (TN), an advancement of the posterior tibialis tendon on the inner face of the first cuneiform. This technique is described under the name of osteotomy 3C by the Anglo-Saxons includes a closure osteotomy (subtraction with a medial base) associated with a medial translation of the calcaneus, a plantar closure osteotomy or pronation of the medial cuneiform and a cuboid opening osteotomy to restore the alignment of the forefoot and the midfoot. This intervention seems to be the method of choice if the talus is not in excessive plantar flexion and if the naviculum is not translated outside. Principle of the 3C osteotomy / the valgization osteotomy-medial translation of the calcaneus correct the valgus of the back foot and allow it to be repositioned in the axis of the tibia. The opening osteotomy of the cuboid corrects the valgus of the forefoot.the closing osteotomy of the first wedge-shaped corrects the supination of the forefoot.

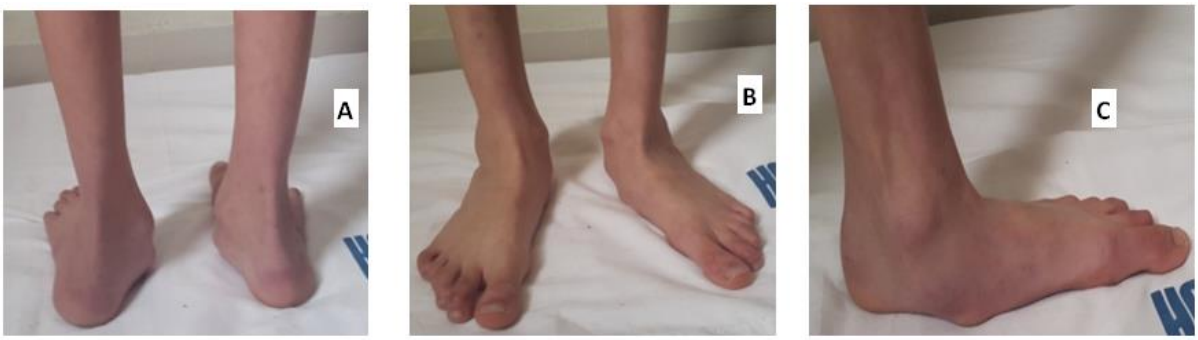


*A: Valgus of the hindfoot with toe many toe sign,*
*B: Midfoot break on hindfoot, C: Collapse of the medial arch*

**Fig 1: Severe valgus flatfoot Bilateral symptomatic in a 12-year-old girl**




**Fig 2: x-rays foot in charge preoperative face (A) and profile (B)**

Operating technique in the operating room, under general anesthesia, the patient is placed in a supine position on an ordinary table, with a pneumatic tourniquet at the root of the thigh. The intervention takes place under control by gloss amplifier. First step: lengthening of the Achilles tendon and the short fibular according to the Vulpus technique. Postero-external incision at the middle third- lower third junction over approximately 4 cm, Vulpus-type elongation which makes it possible to gain dorsal flexion of the ankle by 20°, Elongation according to the vulpus technique of the short lateral fibular, Second step: osteotomy of the calcaneus of subtraction with an internal base of closure and internal translation. External incision 1 cm below the external malleolus going up to the top of the cuboid, The fibular tendons and the external saphenous nerve are bent upwards, Oblique osteotomy with an internal base with a saw then scissors, up to the internal cortical, To ensure the total mobility of the distal part of the osteotomy in order to make an internal translation of 1 cm. Third stage: osteotomy of opening of the cuboid in order to lengthen the lateral arch. Extend the incision from the calcaneus to the cuboid, Opening osteotomy with a saw in the middle of the cuboid perpendicular to the axis of the calcaneal-cuboid joint. Fourth step: plantar base closure osteotomy. Medial incision of 6cm under the internal malleolar to the cuneiform, Identification of the posterior tibialis tendon which passes into the plantar it is not its normal position to release it and put it on a tractor wire, Talo-navicular capsulectomy, Reduction of the valgus of the midfoot and dorsal flexion pronation talo-navicular capsulography by non-absorbable wire, Advancement of the posterior tibialis and fixation by trans-osseous points on the inner face of the first cuneiform. Fifth step: osteosynthesis by pins of the 3 osteotomies in the reduction position. A pin with a closing diameter of 2 mm in the axis of the cuneiform, A pin with a diameter of 2 mm for opening the cuboid, the graft being interposed at the level of the first cuneiform in the axis of the cuboid, Two pins with a diameter of 2 mm perpendicular to the axis of the calcaneus osteotomy after the internal translation, Immobilization by plaster in a boot, ankle at 90° for a duration of 6 weeks. Postoperative sequelae Postoperative immobilization by plastered or resin boot, ankle at 90 ° for a period of 6 weeks and prohibited support (crutch or armchair) during this period. The removal of the pins is performed at the end of the sixth postoperative week. Rehabilitation based on a protocol in an adapted center with progressive support and learning to walk is recommended for a period of three months, after the removal of the cast. Follow-up of patients in periodic consultation: the follow-up is clinical and radiological at the 6th week, 6th month, 12th month and at the 24th postoperative month. Evaluation the intraoperative and postoperative evaluation at the last setback was carried out according to the KITAOKA

score (AOFAS) [3]. This score is determined on the basis of subjective criteria (pain, impression of stability) and objective criteria (lameness, joint mobility, limitation of activities or walking perimeter) and gives a final score out of 100 points. The clinical results judged excellent between 90 and 100 points, good from 75 to 89, average between 60 and 74 and bad if less than 60.

## RESULTS

The short-term results of our series treated according to this 3C osteotomy are good and excellent both radiographically and functionally. The complete disappearance of the pain, the deepening of the medial arch, the correction of the valgus of the hind foot, the disappearance of the medial and plantar prominence of the head of the talus and the ease of putting on testify to the reliability of this surgical method. The preoperative and postoperative Kitaoka score is significantly improved (from 38 points (25-50) to 85 points (70-92). (Fig 3)

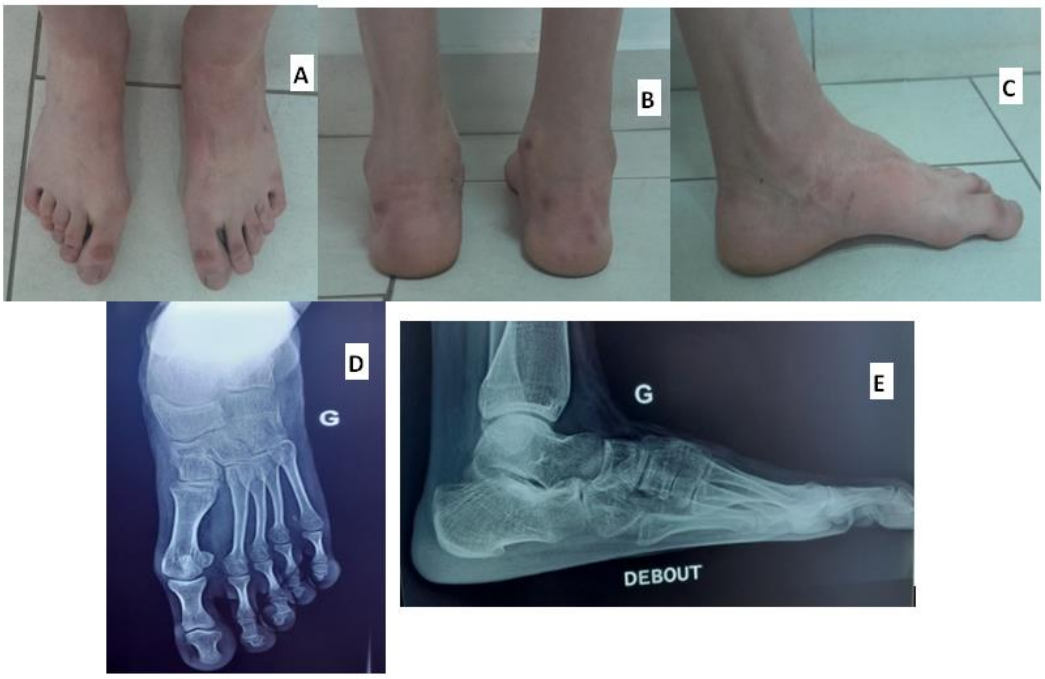


**Fig 3: The patient was surgically treated by 3C procedure bilaterally, a 5-year follow-up shows a good clinical (A,B,C) and radiological result (D,E).**

We had noted an improvement in the angular values in the frontal and sagittal plane. The TCD of the face is decreased, its value being on average 22.24° (standard deviation 2.31, extremes 23-35, median 27.25). testifies to a correction of the posterior valgus. The stripping angle is decreased with a mean value of 22.9° (standard deviation 5, extremes 13 -32, median 23). It translates a correction of the mid-tarsal valgus. Meary angle is decreased its mean value is 11.93° (standard deviation 1.9, extremes 8 ½ -16 ½, median 12). Translates the normalization and deepening of the medial arch. T-H angle decreased with an average of 20.21° (standard deviation 3.93, extremes 12-27, median 20).testifies to the correction of the equinism of the slope. Slope calcaneal is increased its average value is 21.35° (standard deviation 2.53, extremes 18-25, median 21).Translates the correction of the calcaneal equinism. We had a residual valgus defect of the left hind foot < 10° in a girl who had surgery for both of her feet at the same time left surgery. There was no infection, or lack of consolidation of the osteotomy site. (Table 1)

**Table 1: Pre and postoperative radiological values in the 3C osteotomy**

| OSTEOTOMIE 3C | | | | |
|---|---|---|---|---|
| | **Normal values** | **Preoperative** | **Postoperative** | **P** |
| T-M1 Méray angle | 1 – 35 | 31.78 ± 3.52 | 10.81 ± 2.06 | $< 10^{-3}$ |
| Calcaneal pitch angle | 11-38 | 9.33 ± 2.94 | 23.75 ± 2.68 | $< 10^{-3}$ |
| T-Horizontal (T-H) angle | -15 – 55 | 39.56 ± 5.92 | 27.18 ± 4.11 | $< 10^{-3}$ |
| Talocalcaneal divergence (TCD) angle | 10-56 | 36.42 ± 4.75 | 22.76 ± 3.94 | $< 10^{-3}$ |
| Talonavicular coverage angle | 5 – 39 | 41.64 ± 5.73 | 19.38 ± 4.34 | $< 10^{-3}$ |

## DISCUSSION

Idiopathic sever flat feet, underestimated in children and adolescents in our country with a high demographic constitutes a reason for daily consultation by the deformation of the foot and its unaesthetic appearance, the difficulties of putting on and the functional discomfort that it generates. Her increasing frequency in pediatric orthopedics consultations has not ceased to arouse our interest. A thorough knowledge of the patho-physiological bases of RSIFF allows a better surgical therapeutic approach called "functional", less aggressive vis-à-vis the growth cartilage and joints. During the last decades, advances in computer science, imaging (2D and 3D CT, MRI and arthro-MRI) and very sophisticated walking analysis systems on the track have allowed a better static and dynamic understanding of the foot and also of the entire lower limbs (Computerized gait analysis with Vicon or Elite type devices ...). In our work, the X-ray study of the RSIFF aimed to define the anatomical relationships of the talo-naviculo-calcaneal, talo-crural and tarso-metatarsal joints. The complexity, the entanglement of the deformations and the cartilaginous state of the bones of the foot reflected the difficulties of interpretation, the great variability of the criteria and the radiographic angular measurements. The interest of these examinations was the subject of numerous discussions and speculations as to their reliability in the evaluation of the results. Conservative treatment has no place in the valgus flatfoot because it does not allow restoring the normal architecture of the foot. Indeed, orthotics, orthopedic insoles and adapted shoes have no interest or beneficial effect in the vast majority of RSIFF of children and the studies of Gould [4] and Wenger [5] clearly highlight the absence of difference between spontaneous evolution and evolution after conservative treatment, or even their ineffectiveness [6]. Rehabilitation can be useful to improve the extensibility to the triceps and strengthen the relatively weakened posterior tibialis muscle. To date, no objective studies have confirmed the effectiveness of this type of treatment in avoiding the aggravation of the deformity in adulthood [7]. The corrective surgery of the RSIFF is indicated in front of a significant functional discomfort, a rapid wear of the shoes, a persistence of the pains and of course after a failure of the conservative treatment [8].Indeed, the severe deformation of the flat foot remains the main reason for consultation, found in 70% of cases in our series, followed by the wear of the shoes and the pains with the effort. The surgical procedures are numerous and concern the soft parts or the bony elements or both. Apart from the elongation of the Achilles tendon, the isolated surgery of the soft parts plays no role on the reduction of the pain of the symptomatic flat foot [9]. The classic surgical interventions enraiding blocking the subtalar joint or the torsional torque have no place in the RSIFF of the child or the adolescent [7]. In addition, they carry an undeniable arthrogenic risk for the other joints of the foot and ankle [10, 11]. The retraction or the talo-calcaneal repositioning by opening the sinus of the tarsus and interposition of plastic or metallic material (arthrorization) [12]. Is not devoid of complications such as expulsion or intolerance of the material and the risk of necrosis of the talus [4, 13]. The better dynamic and static understanding of this three-dimensional deformation and the undeniable contribution of modern imaging have made it possible to establish a more adapted and more effective so-called "functional" surgical strategy. This new therapeutic approach respects the growth and joint mobility of the foot. It aims to restore clinical morphology and radiographic joint ratios, normalize dynamic pressures [14].And finally relieve the patient in the long term [9]. Among these extra-articular surgical procedures, two types of osteotomy of the calcaneus, most often associated with other gestures, recently occupy the first place. Many authors [15, 16, 17, 1, 18, 19, 9] report good and excellent functional results in the medium and long term after treatment with extra-articular osteotomies. The latter appear as the treatment of choice for these painful flat feet. Koutsogiannis [1], from a series of 19 patients (34 feet) treated with medial translational calcaneal osteotomy, reports good results with a disappearance of the valgus of the hind foot in 30 feet (88.2%), a deepening of the arch of the foot in 25 feet (73.5%), a disappearance of fatigue and a shoe without difficulty in 17 feet (89.5%). On the other hand, the plantar flexion of the talus has not been corrected. Rathjen and Mubarak [6,7] report the clinical results of a series of 26 feet in 18 patients treated with the 3C method are very encouraging with 23 feet (95.8%) of good or excellent results. Radiographically, 19 feet (79%) have an angle of the slope with the horizontal normal or close to the normal value allowed. On the other hand, in our series the 3C osteotomy was performed in 34 feet (21 patients), the clinical results were good or excellent in 33 feet (97%), the angular values of the 5 radiological parameters of the face (TCD, T-N stripping) and profile (TM1, Calcaneus pitch, T-H) were normal or close to normal values. The clinical and radiological results of our series of 21 patients with 34 symptomatic RSIFF, treated respectively by two CM1 and 3C surgical procedures, are superior to those of the two series of literature. No report in the literature reports the residual valgus of the hind foot, less than 10 ° found in one patient in our series due to insufficient medial translation of the osteotomy of the calcaneus. The analysis of the results of the 34 feet operated on and followed up to the end of growth in our series highlights the maintenance of the chirugical correction. No recurrence has been recorded. 92% of these patients are satisfied or very satisfied and practice sports activities. No foot showed radiographic signs of osteoarthritis at the last setback.

## CONCLUSION

The calcaneal-cuboid-cuneiform osteotomy, extra-articular osteotomy is the treatment current ideal of idiopathic reducible severe valgus flatfoot of children and adolescents. This intervention seems to be the method of choice if the talus is not in excessive plantar flexion and if the naviculum is not translated outside. The deformation of the foot is corrected while maintaining mobility.The short-term results of our series treated according to the 3C process are good and excellent both anatomically and functionally. This new therapeutic approach of idiopathic, symptomatic RISFF for children and adolescents respects the growth and joint mobility of the foot.d adolescents.

## REFERENCES


1. Koutsogiannis E. Treatment of mobile flat foot by displacement osteotomy of the calcaneus. The Journal of Bone & Joint Surgery British Volume. 1971 Feb 1;53(1):96-100. https://boneandjoint.org.uk/article/10.1302/0301-620X.53B1.96
2. Rathjen KE, Mubarak SJ. Calcaneal-cuboid-cuneiform osteotomy for the correction of valgus foot deformities in children. Journal of Pediatric Orthopaedics. 1998 Nov 1;18(6):775-82. https://journals.lww.com/pedorthopaedics/fulltext/1998/11000/calcaneal_cuboid_cuneiform_osteotomy_for_the.15.aspx
3. Thomas JL, Christensen JC, Mendicino RW, Schuberth JM, Weil LS, Zlotoff HJ, Roukis TS, Vanore JV. ACFAS Scoring Scale user guide. The journal of Foot and Ankle Surgery. 2005 Sep 1;44(5):316-35. https://www.jfas.org/article/S1067-2516(05)00470-9/abstract
4. Gould N, Moreland M, Alvarez R, Trevino S, Fenwick J. Development of the child's arch. Foot & ankle. 1989 Apr;9(5):241-5. https://journals.sagepub.com/doi/abs/10.1177/107110078900900506
5. Dr Wenger. Corrective shoes and inserts as treatment for flexible flatfoot in infants and children. J Bone Joint Surg Am. 1989;71:800-10. https://cir.nii.ac.jp/crid/1573387450270672384
6. Wicart P, Toullec E. Pied plat valgus idiopathique. Cahiers d'enseignement de la SOFCOT. 2010:157-73. https://pascal-francis.inist.fr/vibad/index.php?action=getRecordDetail&idt=23741592
7. Mosca VS. Flexible flatfoot in children and adolescents. Journal of children's orthopaedics. 2010 Apr;4(2):107-21. https://journals.sagepub.com/doi/abs/10.1007/s11832-010-0239-9
8. Mosca VS. Flexible flatfoot and skewfoot. Instructional course lectures. 1996;45:347-54. https://pubmed.ncbi.nlm.nih.gov/8727755/
9. Moraleda L, Salcedo M, Bastrom TP, Wenger DR, Albiñana J, Mubarak SJ. Comparison of the calcaneo-cuboid-cuneiform osteotomies and the calcaneal lengthening osteotomy in the surgical treatment of symptomatic flexible flatfoot. Journal of Pediatric Orthopaedics. 2012 Dec 1;32(8):821-9.
10. Adelaar RS, Donnelly EA, Meunier PA, Stelling FH, Goldner JL, Colvard DF. A long term study of triple arthrodesis in children. Orthopedic Clinics of North America. 1976 Oct 1;7(4):895-908. https://www.sciencedirect.com/science/article/pii/S0030589820322379
11. Golano P, Fariñas O, Sáenz I. The anatomy of the navicular and periarticular structures. Foot and ankle clinics. 2004 Mar 1;9(1):1-23. https://www.foot.theclinics.com/article/S1083-7515(03)00155-4/abstract
12. Verheyden F, Vanlommel E, Van Der Bauwhede J, Fabry G, Molenaers G. The sinus tarsi spacer in the operative treatment of flexible flat feet. Acta orthopaedica belgica. 1997 Dec 1;63(4):305-9. https://europepmc.org/article/med/9479785
13. Gray EG, Basmajian JV. Electromyography and cinematography of leg and foot ("normal" and flat) during walking. The anatomical record. 1968 May;161(1):1-5. https://onlinelibrary.wiley.com/doi/abs/10.1002/ar.1091610101
14. Grice DS. An extra-articular arthrodesis of the subastragalar joint for correction of palalytic flat feet in children. J Bone Joint Surg. 1952;34:927-40. https://cir.nii.ac.jp/crid/1570009749917379328
15. Furdon SA, Donlon CR. Examination of the newborn foot: positional and structural abnormalities. Advances in Neonatal Care. 2002 Oct 1;2(5):248-58.
16. RI H, Beath T. Hypermobile flat-foot with short tendo achillis. The Journal of Bone and Joint surgery. American Volume. 1948 Jan 1;30(1):116-40. https://europepmc.org/article/med/18921631
17. Harris RI, BeathT. Army foot survey, vol 1. National Research Council of Canada, Ottawa, 1947; pp 1-268.
18. Moraleda L, Mubarak SJ. Flexible flatfoot: differences in the relative alignment of each segment of the foot between symptomatic and asymptomatic patients. Journal of Pediatric Orthopaedics. 2011 Jun 1;31(4):421-8.
19. Mosca VS. Calcaneal lengthening for valgus deformity of the hindfoot. Results in children who had severe, symptomatic flatfoot and skewfoot. JBJS. 1995 Apr 1;77(4):500-12.