International Journal of Allied Medical Sciences and Clinical Research (IJAMSCR)
IJAMSCR |Vol.12 | Issue 2| Apr - June -2024
www.ijamscr.com
ISSN: 2347-6567
DOI : https://doi.org/10.61096/ijamscr.v12.iss2.2024.124-127

Case Report

Isolated trapezium fracture about a case and review of the literature

Amel Djerbal[1*], Kenza Badache[2], Samir Tebani[1], Mohammed Yacef[1], Lamya-Nawel Benamer [3], Reda Khiali[4], Reda Harrar[1]

[1]Faculty of Medicine, University of Algiers I, Specialized Hospital Establishment Salim Zemirli, El Harrach, Algiers
[2]Faculty of Medicine, University of Algiers I, University Hospital Center of Algiers, Hospital of Algiers Mustapha
[3]Faculty of Medicine, University of Algiers I, Obstetrics and Gynecology Department, Kouba public hospital
[4]Faculty of Medicine, University of Algiers I, General surgery department, Ain Taya hospital, Algiers

[*]Author for Correspondence: Amel Djerbal
Email: djerbalamel@gmail.com

Published on: 18 Apr 2024

Published by:
DrSriram Publications

2024| All rights reserved.

Creative Commons Attribution 4.0 International License.

Abstract

Isolated fractures of the trapeziums' are rare; they represent 3 to 5% of fractures of the carpal bones and can go unnoticed. They are often associated with other fractures of the hand and wrist, in particular the Bennett fracture, the mechanism remains poorly known, and the diagnosis can be difficult. The purpose of our work was to emphasize the importance of the clinical examination which must be thorough and specific radiological implications. Computed tomography (CT) should be performed at the slightest doubt. Poorly treated, these fractures can be the cause of painful sequelae in the trapezo-metacarpal joint type of disabling rhizarthrosis. Reporting to us the case of a 23-year-old young patient with an isolated fracture of the trapezius displaced from his right wrist, surgically treated The fracture consolidated without complications, after six weeks and the patient returned to work after three months and did not present pain with the mobilization of the thumb, nor loss of strength. Conclusion: The isolated trapezoid fracture is very rare in traumatology. Its suspicion must lead to more advanced para-clinical investigations because neglected, it can be the cause of painful sequelae at the level of the trapezo-metacarpal joint with an important maintenance on daily activity.

Keywords: trapezium, literature

INTRODUCTION

Isolated fracture of the trapezium are rare, they represent 3 to 5% of fractures of the carpal bones and can go unnoticed. They are often associated with other fractures of the hand and wrist, in particular the Bennett fracture, the mechanism remains poorly known, and the diagnosis can be difficult.The purpose of our work was to emphasize the importance of the clinical examination which must be thorough and specific radiological

implications. Computed tomography (CT) should be performed at the slightest doubt. Poorly treated, these fractures can be the cause of painful sequelae in the trapezo-metacarpal joint type of disabling rhizarthrosis.

Presentation of the case

C. I am 23 years old, victim of deliberate beatings and injuries, followed by a fall on my right wrist in extension. On examination, he presented edema and pain in the right thenary region, total functional impotence of the right thumb. The diagnosis was made on an X-ray of the hand; a CT scan was made confirming the diagnosis. The fracture was vertical, external, displaced (Walker type IV) (Figure 1), without associated lesions.



a b

Fig 1: a: preoperative X-ray of the hand from the front and in profile showing the fracture of the trapezius b: Preoperative CT

The treatment was surgical, under locoregional anesthesia, first by the dorso-lateral route, which allowed the reduction of the fracture and the stabilization was entrusted to a pinout (Fig 2).

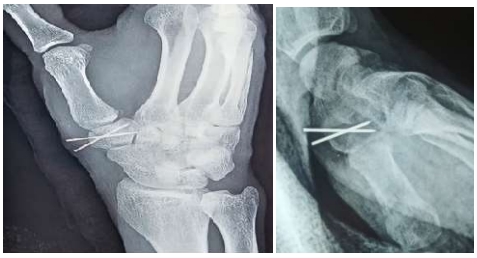

Fig 2: Immediate postoperative radiography of the osteosynthesis of the trapezius fracture

RESULTS

The fracture consolidated without complications, after six weeks and the patient resumed his work after three months and did not present pain during the mobilization of the thumb, nor loss of strength with an opposition of the thumb rated at 10 according to the rating of kapandji, with hindsight of 28 months, the result was considered excellent (Fig 3,4,5).



Fig 3: Face X-ray at 06 weeks postoperative



Fig 4: Face X-ray at 03 months postoperative

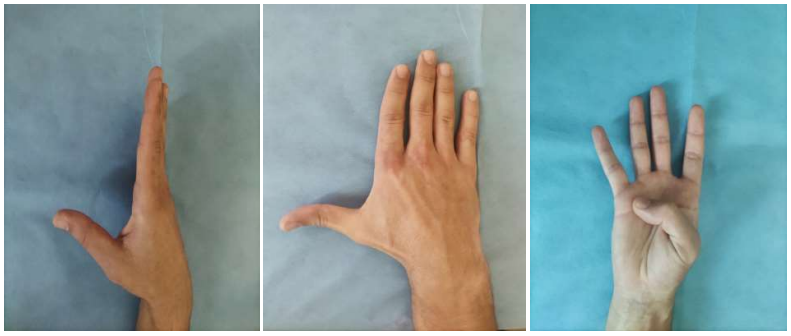

Fig 5: Clinical result after removal of the osteosynthesis material

DISCUSSION

Isolated fractures of the trapezius remain rare or rather often unknown. The associated lesions are those of the thumb spine, in particular the Bennett fracture. Simple radiographs are poorly performing for the diagnosis of trapezoid fractures due to the radiological overlap with the trapezoid. The specific occurrence of kapandji from the front and in profile better shows the body of the trapezoid and the base of the first metacarpal. Computed tomography allows an accurate diagnosis of these fractures. As with any joint fracture, anatomical reduction is the rule. Orthopedic treatment by plastered immobilization with thumb in the opposition position gives good results for isolated and non-displaced fractures of the trapezius. In case of displacement or association with another fracture of the thumb, surgical treatment is necessary and requires an anatomical reduction. Osteosynthesis can involve thin kirschner pins, or screwing. Trapezectomy can be considered in comminuted fractures. Postoperative plastered immobilization is not essential if the osteosynthesis seems solid, but usually it is resorted to for 15 to 30 days.

CONCLUSION

The isolated trapezoid fracture is very rare in traumatology. Its suspicion must lead to more advanced para-clinical investigations because neglected, it can be the cause of painful sequelae at the level of the trapezo-metacarpal joint with an important maintenance on daily activity.

REFERENCES

1. Arabzadeh A, Vosoughi F. Isolated comminuted trapezium fracture: a case report and literature review. International Journal of Surgery Case Reports. 2021 Jan 1;78:363-8.
2. N. Bousselmame, H. Kasmaoui, F. Galuia, K. Lazrak, H. Taobane, I. Moulay, the fractures of the trapezoid, Belgian Orthopedic Acts, 66, 2,2000.
3. S. R. Beekhuizen, C. R. Quispel, J. Jasper, R. L. M. Deijkers, The uncommon trapezoid fracture: a series of cases, J. Wrist Surgery 9 (February (1) (2020) 63-70,
4. Pierre Francès1, Widad Gallaf2, Julien Planas3, Soleiman Abokassem3, Guilhem Mauret3 , Isolated fracture of the trapezoid, The Practitioner's Review. December 2022, 36(1072); 5e&33
5. Ouchrif Y, Affes H, Robial N. Fracture isolée du trapèze chez un coureur cycliste: à propos d'un cas et revue de la littérature. Journal de Traumatologie du Sport. 2016 Sep 1;33(3):173-6. https://www.sciencedirect.com/science/article/pii/S0762915X16300432

6. Panigrahi R, Biswal MR, Palo N, Panigrahi N. Isolated coronal fracture of trapezium-a case report with review of literature. Journal of Orthopaedic Case Reports. 2015 Jul;5(3):29. https://www.ncbi.nlm.nih.gov/pmc/articles/PMC4719393/
7. Samson D, Jones M, Mahon A. Non-union of the trapezium: rare consequence of a rare injury. Journal of Surgical Case Reports. 2018 Apr; 2018(4):076. https://academic.oup.com/jscr/article-abstract/2018/4/rjy076/4990323
8. Suresh SS. Isolated split coronal fracture of the trapezius. Indian orthosis J. 2012; 46: 99-101.