International Journal of Allied Medical Sciences and Clinical Research (IJAMSCR)

IJAMSCR |Volume 3 | Issue 1 | April-June- 2015
www.ijamscr.com

Case report *Medical research*

A case report on Atropine induced CNS side effects and Tachycardia

R SiddaRama[1]*, M Javeed Baig[1], A Arjun Kumar[2]

[1]*Department of pharmacy practice, P Rami Reddy Memorial College of Pharmacy, Kadapa, India, 516003*

[2]*MD Associate Professor, General Medicine, Rajiv Gandhi Institute of Medical Science, Kadapa, India, 516003*

***Corresponding author: R. Siddarama**

E-mail id: siddaramapharmd22@gmail.com

ABSTRACT

Atropine is an anti-cholinergic, prototype of drug obtained from *Atropa Belladonna*. It mainly blocks the muscarinic receptors which place a major role in performance of the brain for learning, memory, and orientation. In the therapeutic dose, atropine has a mild CNS stimulant effect but large doses can produce excitement, restlessness, agitation, hallucinations, coma and death. In therapeutic dose of atropine produces tachycardia through the blockage of M_2 receptors of the heart. The use of atropine includes, brad arrhythmias, Severe bradycardia, organophosphate poisoning, 1st degree A-V block, salivary and bronchial secretion reduction. the extreme doses of atropine can causes the tachycardia, delirium, coma, flushed and hot skin, blurred vision, excitement, restlessness, hallucinations and ataxia. Here in this case report, a 30 years old female patient was developed excitement, hallucinations, restlessness, blurring of vision, photophobia, tachycardia, palpitation medullary paralysis and ECG abnormalities due to the atropine administration.

Keywords: Atropine, anti-cholinergic drug, ECG abnormalities, excitement, hallucinations, restlessness, palpitations.

INTRODUCTION

Atropine sulphate active substance is atropine which is obtained from *Atropa Belladonna*, it is a tertiary amine with half-life of 2.6 - 4.3 hours[1,2]. The plant Atropa belladonna is an intermittent herb belonging to the family of Solanaceae[3]. It is known to be tremendously toxic and the name of Atropa is derived from "Atropos" in Greek and Belladonna denods "beautiful women" in Italian[4]. The atropine blocks the muscarinic receptor acetylcholine, which plays an major role in the performance of the brain for learning, memory and orientation. In the occasion of the muscarinic blockade, the lack of acetylcholine causes dysfunctional memory, hallucination and disorientation[4]. Atropine has a stronger outcome than scopolamine in producing tachycardia and cardiovascular changes, although the peripheral effects of both atropine and scopolamine are the similar[5,6]. Atropine is an anticholinergic or antimuscarinic agent which competitively antagonizes acetylcholine at postganglionic nerve endings, consequently disturbing the receptors of the exocrine glands, smooth muscle, central nervous system and the cardiac muscle. Peripheral properties which include tachycardia, sweat and bronchial, lacrimal and gastric secretions, decreased production of saliva, nasal, decreased intestinal motility and inhibition of micturation. The uses of atropine include brad arrhythmias, Severe bradycardia, organophosphate poisoning, 1st degree A-V block, salivary and bronchial secretion reduction. The mechanism of atropine induced tachycardia till not known but tachycardia may result from vagal inhibition and induce angina pectoris in patients with coronary heart disease[7]. The extreme doses of atropine can causes the tachycardia, delirium, coma, flushed and hot skin, blurred vision, excitement, restlessness, hallucinations and ataxia. Paradoxical bradycardia might consequence from doses less than 0.5 mg of atropine. Side effects may include palpitations, nausea and vomiting, dysarhythmias, headache, dizziness[8]. Atropine is a tertiary amine and it freely enters in to the CNS. The high doses of atropine stimulate and then discourage the medulla and higher cerebral centres in the body[9].

CASE REPORT

A 30 Years old female patient was admitted in ICU, RIMS, kadapa, with the chief complaints of burning sensation in the stomach, throat, vomiting 2-3 episodes and history of urination involuntary due to intake of organophosphate poisoning (Dimethoate). Past history of the patient was found to be intake of some amount of kerosene 1 year back. He was not known Diabetic, COPD, Asthma, Epilecy and CAD patient. On general Examination the patient was conscious and coherent. But looking she was very weak and her vitals were: BP-120/70 mm/Hg, PR-

108 bpm, CVS- S1,S2+ & S3, RR-12 Cpm, RS-BLAE+, P/A- soft, CNS- Pupils were not reacted to light. Her ECG report was found to be abnormal (ST segment depression in aVR, aVL at V_1 to V_4). On day 4 patient were developed excitement, hallucinations, restlessness, blurring of reason, photophobia, tachycardia palpitation, and medullary paralysis. Based on subjective (CNS side effects) and objective (ECG abnormalities) evaluation the patient was confirmed to have atropine induced CNS side effects and tachycardia as shown in figure-1

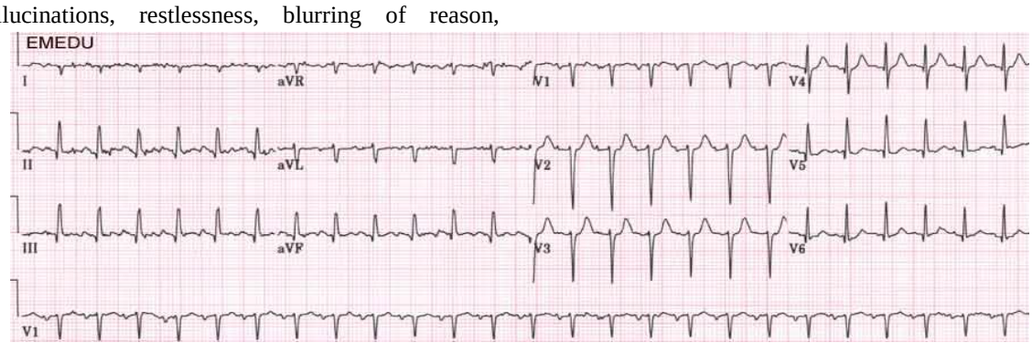

Figure 1: Atropine induced Tachycardia (ST segment depression in aVR, aVL at v_1 to v_4)

Patient was treated with following medications which include antibiotic (ceftriaxone 1gm IV BD), parenteral anti-ulcer (Pantaprazole 40mg IV BD), Anti-cholinergic drug (Atropine .06Mg IV Tid) and intravenous fluids. We the Pharm-D students informed to the physician that, atropine has induced CNS and CVS side effect in the patient. In response to the adverse drug reaction occurred due to atropine, immediately the doctor had stopped prescribing the drug atropine.

ADR Analysis

After collecting complete history from the patient and followed by case details, it was suspected the patient had develop atropine induced CNS side effects and tachycardia. After analyzing the ADR profile of the all drugs prescribed, it was found that the most suspected the drug for causing CNS side effects and tachycardia was "atropine" here we have done causality assessment by using naranjos scale, WHO – UMC ADR assessing scale as well as karch & lasgna scale.results are recorded as shown in table **1**. We have also assessed the severity, predictability & preventability scales thrown the modify HARTUING & SIEGEL seviority scale, schumock & thoranton preventability scale.

ADR management

The management of the ADR include withdrawn/ suspension, dose reduction of suspected drug & administration of supportive therapy but in this case it is not possible to withdrawn & reduced dose because of OP poisoning. Atropine is drug of the choice and no alternative medications made available in medical centre so here in this case symptomatic treatment is only possible other voice patient suffer from psychosis.

Suspected drug and reaction	Narranjos scale	WHO-UMC scale	Karch & LASGNA SCALE
Atropine induced CNS side effects and tachycardia	Probable ADR (6)	Probable / likely	Probable ADR

Table 1: causality assessment of suspected ADR

Severity –moderate level 4 a
Predictability – Predictable ADR (type B)
Preventability- not preventable

DISCUSSION

Atropine, is an alkaloid used commonly used for antimuscarinic property[10]. It acts as a competitive antagonist of acetylcholine at muscarinic receptors. It can be administered with different routes, include the eye drop formulation of atropine sulfate, used to induce cycloplegia and mydriasis[11]. In overdose of atropine can cause tachycardia, agitation, delirium, dilated pupils, dry mucous membranes, dry skin, and hypoactive bowel sounds. These phenomenon have been describe even with attempted therapeutic ophthalmic use[10,12]. Atropine is a belladonna alkaloid it produces the anticholinergic effects. Atropine systemic toxicity cause the characteristics of anticholinergic toxic syndrome including dilated pupils, dry skin, dry mucous membranes, tachycardia and urinary retention, other features are tachypnea, elevated body temperature, and central nervous system (CNS) stimulation obvious by confusion, restlessness, psychotic reactions (i.e. aggression, psychomotor agitation, and delirium) and infrequently seizures[13,14]. In severe intoxication, the central stimulation might cause CNS depression, circulatory and respiratory failure, coma and death[15]. the Diagnosis of anticholinergic toxicity may be complicated and generally based on current and post history, since exact laboratory tests are not regularly available and the extensive range of signs and symptoms cannot be present in every case[16]. in addition, signs and symptoms of anticholinergic toxicity (i.e. altered mental status and hallucinations) may happen in other cases such as hypoglycemia, sepsis, psychiatric disorders, intracranial infections, intracerebral hemorrhage, and other poisonings[13,17].

in excess of dose, the patient can present with mydriasis, agitation, anxiety, confusion, hallucinations, delirium, tremor, hyper reflexia, paranoia, movement disorders, and seizures. Cardiac effects are primarily tachycardia and hypertension. All of these symptoms be present in our patient.13 first treatment choice for atropine poisoning are gastrointestinal decontamination and antidote treatment. Gastric lavage can be useful particularly in the first hours of poisoning. Decontamination by activated charcoal may be successful for poisons which are recognized to be absorbed by charcoal in the first hour of intake[18,19]. However, it may be administer after one hour the patients who are taken anticholinergic drugs orally for delaying gastric alteration[20]. Both peripheral and central anticholinergic symptoms can be treated by physostigmine, it's a reversible cholinesterase inhibitor and the chosen agent for the control of peripheral and central anticholinergic symptoms including agitation and delirium [21,22]. intake of as little as a few drops of atropine in eye drop formulation be able to cause anti-cholinergic, or more particularly antimuscarinic, toxicity[23]. The anti-muscarinic toxidrome marks from blockade of the neurotransmitter acetylcholine at central and peripheral muscarinic receptors[24].

CONCLUSION

The patients who are receiving atropine for the treatment of organophosphate poisoning should be closely monitored at regular intervals to find the development of central nervous system side effects, cardiovascular toxicity and other complications (ECG abnormalities) which help in prevention and better management of disease and therapy problems.

REFERENCES

[1] Donovan JW (2005) Anticholinergic plants: Critical care toxicology: diagnosis and management of the critically poisoned patient. (1st edtn) Elsevier Mosby-Year Book, Philadelphia.

[2] Berdai MA, Labib S, Chetouani K, Harandou M (2012) *Atropa Belladonna* intoxication: a case report. Pan Afr Med J 11: 72.

[3] Berdai MA, Labib S, Chetouani K, Harandou M (2012) *Atropa belladonna* intoxication: a case report. Pan Afr Med J 11: 72.

[4] Joshi P, Wicks AC, Munshi SK (2003) Recurrent autumnal psychosis. Postgrad Med J 79: 239-240.

[5] Mirakhur RK, Dundee JW (1979) Cardiovascular changes during induction of anaesthesia. Influence of three anticholinergic premedicants. Ann R Coll Surg Engl 61: 463-469.

[6] Diaz DM, Diaz SF, Marx GF (1980) Cardiovascular effects of glycopyrrolate and belladonna derivatives in obstetric patients. Bull N Y Acad Med 56: 245-248.

[7] http://www.public.health.wa.gov.au/cproot/2548/2/atropine%20sulfate%20injection.pdf

[8] http://www.dhss.delaware.gov/dph/ems/files/pharmacology08.pdf

[9] http://www.icuadelaide.com.au/files/primary/pharmacology/autonomic.pdf

[10] Galichet LY, Moffat AC, Osselton MD, et al, eds. Clarke's Analysis of Drugs and Poisons. 3rd ed. London, UK: Pharmaceutical Press; 2004: 658.

[11] Bishop AG, Tallon JM. Anticholinergic visual hallucination from atropine eye drops. CJEM. 1999;1:115–116.

[12] Baker JP, Farley JD. Toxic psychosis following atropine eyedrops. BMJ. 1958:1390–1392.

[13] Glatstein M, Alabdulrazzaq F, Scolnik D (2013) Belladonna alkoloid intoxication: The 10-year Experience of a Large Tertiary Care Pediatric Hospital. Am J Ther 20 [Epub ahead of print]

[14] Jakabová S, Vincze L, Farkas A, Kilár F, Boros B, et al. (2012) Determination of tropane alkaloids atropine and scopolamine by liquid chromatography-mass spectrometry in plant organs of Datura species. J Chromatogr A 1232: 295–301.

[15] Robenshtok E, Luria S, Tashma Z, Hourvitz A (2002) Adverse reaction to atropine and the treatment of organophosphate intoxication. Isr Med Assoc J 4: 535-539.

[16] Al-Shaikh AM, Sablay ZM (2005) Hallucinogenic plant poisoning in children. Saudi Med J 26: 118-121.

[17] Spina SP, Taddei A (2007) Teenagers with Jimson weed (Datura stromonium) poisoning. CJEM 9: 1634-1639.

[18] American Academy of Clinical Toxicology, Europan Association of Poisons Centres and Clinical Toxicologists (1997) Position statement: single-dose activated charcoal. J Toxicol Clin Toxicol 35: 721-741.

[19] Green R, Grierson R, Sitar DS, Tenenbein M (2001) How long after drug ingestion is charcoal still effective? J Toxicol Clin Toxicol 39: 601-605.

[20] Green R, Sitar DS, Tenenbein M (2004) Effect of Anticholinergic Drugs on the Efficacy of Activated Charcoal. J Toxicol Clin Toxicol 42: 267-272.

[21] Berdai MA, Labib S, Chetouani K, Harandou M (2012) Atropa Belladonna intoxication case report. Pan Afr Med J 11: 72.

[22] Burns MJ, Linden CH, Graudins A, Brown RM, Fletcher KE (2000) A comparison of physostigmine and benzodiazepines for the treatment of anticholinergic poisoning. Ann Emerg Med 35: 374-381.

[23] Glatstein M, Alabdulrazzaq F, Scolnik D (2013) Belladonna alkoloid intoxication: The 10-year Experience of a Large Tertiary Care Pediatric Hospital. Am J Ther 20 [Epub ahead of print]

[24] Caksen H, Odabaş D, Akbayram S, Cesur Y, Arslan S, et al. (2003) Deadly nightshade (Atropa belladonna) intoxication: an analysis of 49 children. Hum Exp Toxicol 22: 665–668.

.