International Journal of Allied Medical Sciences and Clinical Research (IJAMSCR)

IJAMSCR |Volume 3 | Issue 2 | April-June- 2015
www.ijamscr.com

Case report ***Medical research***

Mesenteric fibromatosis with involvement of colon, mimicking as gastrointestinal stromal tumor- A case report

Dr. Hrushikesh S Kolhe[*], Dr. Sadhana D Mahore[1], Dr. Revati Patil[2], Dr. Mahendra Parage[3], Dr. Kalpana A Bothale[4], Dr. Anne Wilkinson[5], Dr. Neha Dalal[6]

*[1]*Asst. Lecturer, Dept. of Pathology, NKPSIMS, Nagpur, India.*
[1]Professor & HOD, Dept. of Pathology, NKPSIMS, Nagpur, India.
[2]Resident, Dept. of Pathology, NKPSIMS, Nagpur, India.
[3]HOD (Histopathology, Global Hospitals, Hyderabad, India.
[4]Associate Professor, Dept. of Pathology, NKPSIMS, Nagpur, India.
[5] Pathology Dept. NKPSIMS, Nagpur, India.
[6]Asst. lecturer, Dept. of Pathology, NKPSIMS, Nagpur, India.

***Corresponding author: Hrushikesh S Kolhe**
E-mail id: dr_rishii@yahoo.co.in

ABSTRACT

Mesenteric Fibromatosis is a locally aggressive myofibroblastic proliferation of the mesentery and adjacent tissues that lack the capacity to metastasize. Mesenteric Fibromatosis (MF) and gastrointestinal stromal tumors (GISTs) are distinct lesions, but they are often confused with each other. Although rare, it is the most common primary tumor of the mesentery and can develop at any age. Here, we describe a rare case of primary Intra-abdominal Fibromatosis involving the mesentery and transverse colon in a 50 year old female which clinically, grossly and histologically mimicked gastrointestinal stromal tumor (GIST). Immunohistochemistry was done which revealed that the tumor mass showed focal coarse granular positivity for c-kit (CD117), while negative for CD34, DOG, desmin, S-100 and SMA. Furthermore, tumor mass showed over expression of β-catenin. This confirmed the diagnosis of localized mesenteric fibromatosis. Correct identification of both the entities (GIST & Fibromatosis) is of utmost importance as they differ vastly in therapeutic and prognostic considerations.

Keywords: Mesenteric Fibromatosis, Gastro Intestinal Stromal Tumor.

INTRODUCTION

Mesenteric Fibromatosis (MF) is a locally aggressive myofibroblastic proliferation of the mesentery and adjacent tissues that, lacks the capacity to metastasize[1][2] and can occur throughout the gastrointestinal tract. Although rare in humans, intra-abdominal fibromatosis (IAF) is the most common primary mesenteric tumor with spindle cell morphology. It may occur at any age, can be solitary or multiple, and may involve the small bowel, omentum, mesocolon and/or retroperitoneum.[1] [3].

GISTs originate from gastrointestinal pacemaker Cajal cells, which are the primary effectors controlling gut motility.[4] [5]

We describe here a rare, localized variant of primary Intra-Abdominal Fibromatosis involving the mesentery and transverse colon, which mimicked a GIST clinically, grossly, histo pathologically & also focally expressing the c-kit protein. Because of the remarkably overlapping immuno phenotype of the two lesions, the aim of this report is to highlight the need to discriminate them because of the introduction of specific therapeutic strategies and the fact that they have different biological behaviors: Intra-Abdominal Fibromatosis is benign and exclusively locally aggressive, whereas GISTs are malignant and may lead to distant metastases.

CASE REPORT

A 50 yr old female was admitted to our hospital with complaints of abdominal discomfort. She gave history of similar symptoms intermittently for 7 months duration. No history of diarrhea/ constipation, blood in stools or any other relevant complaints. No previous history of surgical therapy or trauma. Colonoscopy done was normal. General examination findings were unremarkable. Abdominal examination revealed a mobile, non-tender, firm and globular mass measuring approximately 15cm x 10cm in the suprapubic area. A trans- abdominal ultrasound showed an ovoid, well- defined, homogenously hypoechoic mass. CT scan- abdomen was suggestive of a mass arising from transverse colon. This patient underwent surgery. Intra operatively, a huge mass along the mesenteric border of transverse colon was found. Subsequent lumpectomy along with segmental resection of transverse colon was done and sent for histopathology.

We received a 45cm long, segment of intestine and a mass measuring 14 x 14 x 7cm, well circumscribed, congested external surface, attached to its mesenteric border. Cut surface of the mass showed hemorrhagic areas in the periphery with homogenous grayish white central area (Fig.1).

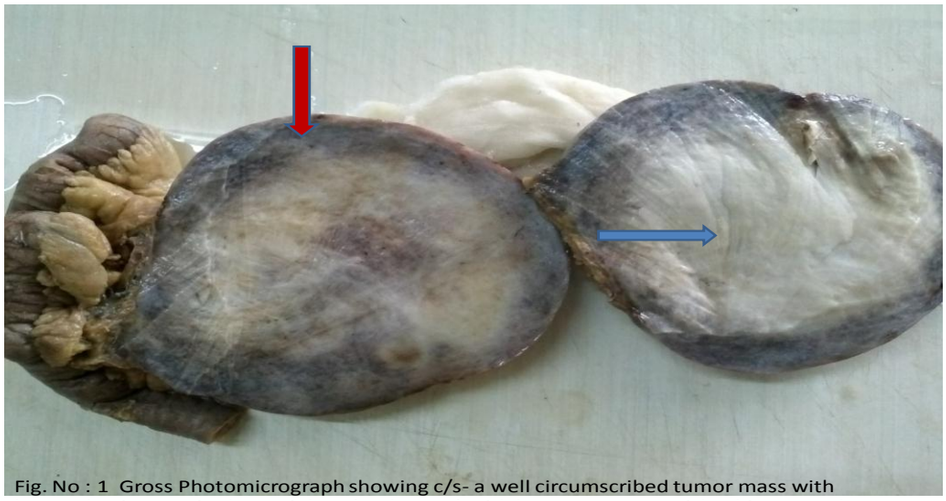

Fig. No : 1 Gross Photomicrograph showing c/s- a well circumscribed tumor mass with hemorrhagic areas in the periphery(red arrow) with homogenous grayish white central area(blue arrow)

Histopathologic findings revealed a circumscribed mild to moderately cellular mass composed of spindle cells arranged haphazardly and at places in fascicles and storiform pattern (fig.3). Individual cells showed wavy pattern with moderate amount of eosinophilic cytoplasm and plump elongated nuclei. Amidst these proliferating cells, many bands of collagen (fig.2) were seen.

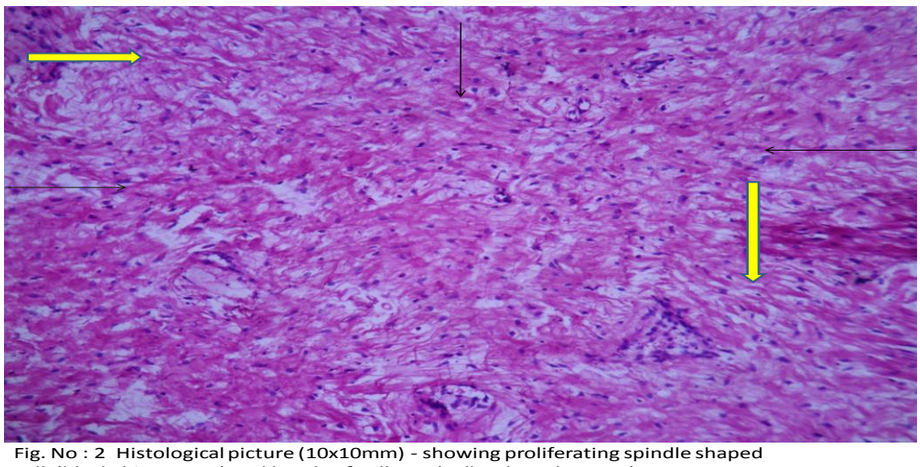

Fig. No : 2 Histological picture (10x10mm) - showing proliferating spindle shaped cells(black thin arrows) and bands of collagen(yellow broad arrows)

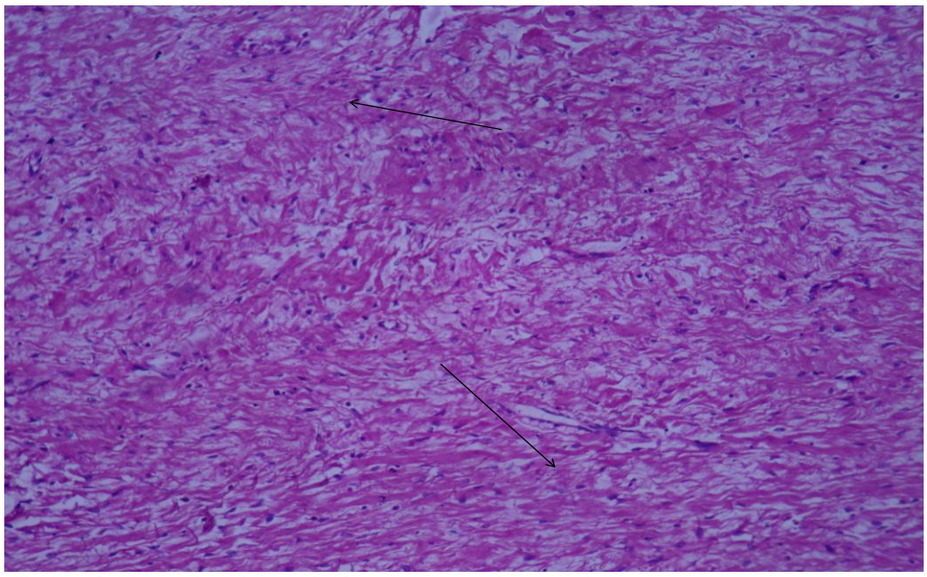

Fig. No : 3 Histological picture (4x10mm)- scanner view showing tumor mass composed of spindle cells, collagen bands(black arrows)

Numerous thin walled, compressed and few dilated vascular channels were also seen. Perivascular spaces showed mild mononuclear inflammatory cell infiltrate. No evidence of cellular atypia or necrosis.

2-4 mitotic figures were seen per hpf. Abnormal mitoses were not evident. Further, immuno histochemistry was done, which revealed, the proliferating spindle cells showing focal coarse granular positivity for c-kit (CD117) & negative for CD34, DOG1, desmin, SMA (smooth muscle actin) and S-100(fig.4). However β-catenin overexpression was seen in these proliferating spindle cells (Fig.5, 6).

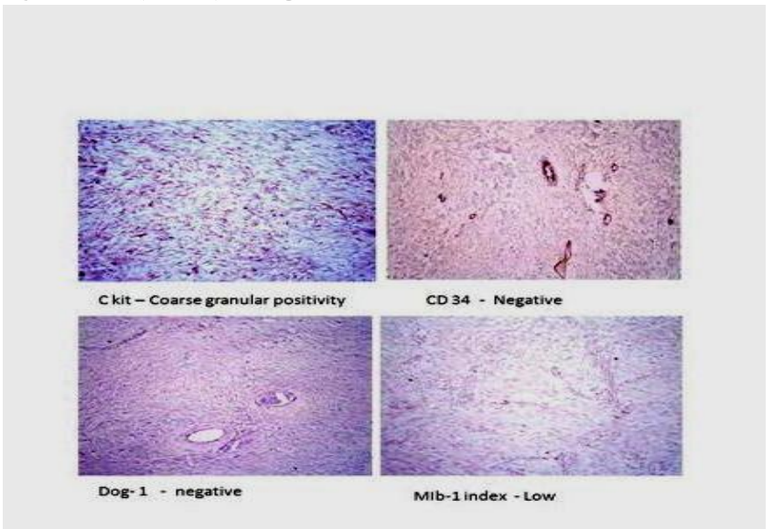

Fig. No : 4 Photomicrograph of Immunohistochemistry- 1) c-kit- tumor cells showing coarse granular positivity, 2) CD34 negative, 3) DOG1 negative, 4) MIB-I proliferation index(2-3%)

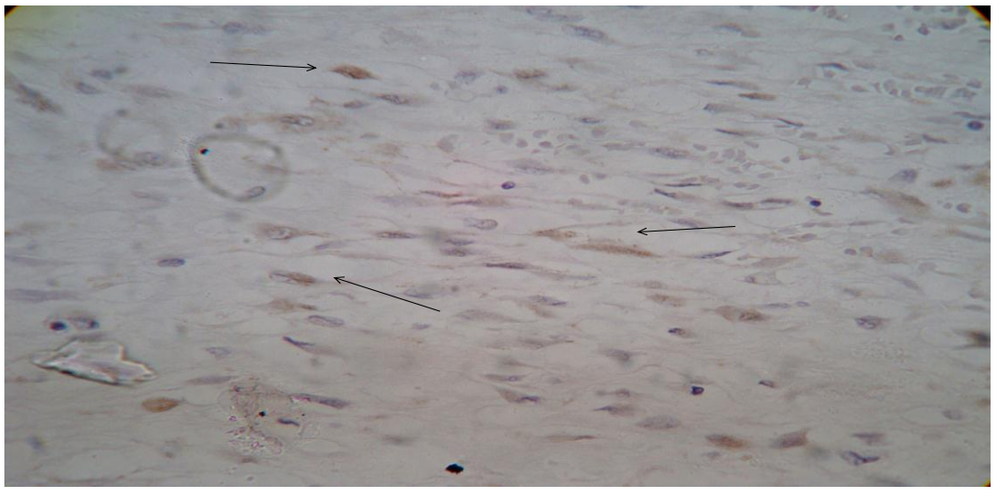

Fig. No : 5 Photomicrograph showing- B-catenin positivity(nuclear) in spindle cell(black arrows)

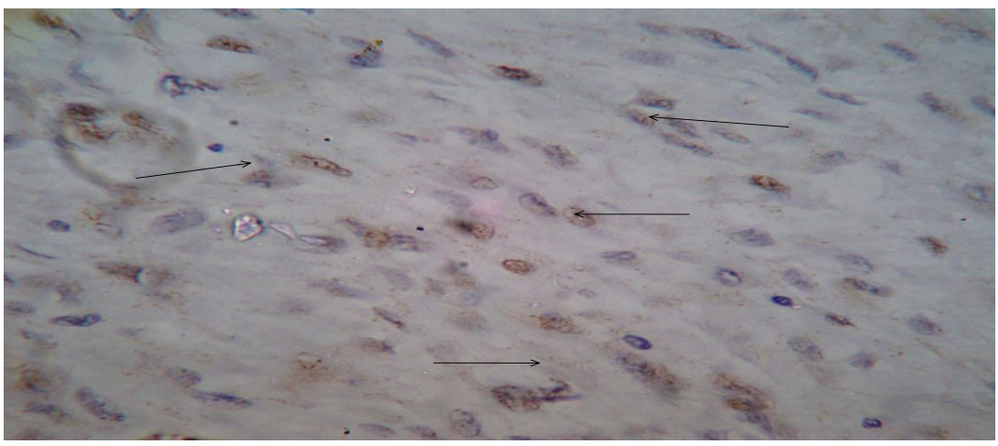

Fig. No: 6 Photomicrograph showing- B-catenin positivity(nuclear) in spindle cells(black arrows)

Thus, after correlating histopathological features and immuno histo chemical profile, final diagnosis was given aslocalized Mesenteric Fibromatosis.

DISCUSSION

The fibromatoses comprise a broad group of myofibroblastic proliferations that have been divided into 2 Groups- superficial and deep-seated. Deep-seated fibromatoses are also known as desmoid tumors.[6] [7].

The deep-seated fibromatoses have been subdivided into extra-abdominal, abdominal, and intra-abdominal. The intra- abdominal fibromatoses have been sub classified further into Localised Mesenteric Fibromatosis, MF associated with Gardner syndrome, and Pelvic Fibromatosis.[6]

Mesenteric Fibromatosis in particular is characterized by an infiltrative pattern of growth and a tendency to local recurrence when excised incompletely and/or associated with Gardner syndrome.[1] [7] [8] However, they are thought to lack the capacity to metastasize.[1] [9]

Some authors consider MF as a non-neoplastic processes while others as well-differentiated low grade sarcomas.[10]

APC gene mutations have been detected in MF which suggests their clonal nature. This relates to an increase of β-catenin, which binds transcription factors and which can lead to an increase of cell proliferation through a nuclear mechanism, hence have abnormal nuclear accumulation of β-catenin protein.[11] [12]

MF and GISTs are distinct lesions, but they are often confused. A panel of gross, microscopic, immuno histochemical and ultra-structural features allow a correct identification in majority of cases. With reference to immuno histochemical studies MF is negative for CD34 and S-100 protein as compared to GISTs. While in the expression of vimentin, CD117, smooth muscle actin and desmin, both the neoplasms do not differ significantly.[13] [14] [15]

Table 1: Distinguishing features between Mesenteric fibromatosis and GIST[16]

Feature	**Mesenteric Fibromatosis**	**GIST**
Shape of tumor cells	Spindle and wavy	Spindle and/or epithelioid
Pleomorphism and atypia	Absent	Often present
Mitotic count per 50 HPF	<10, average 1 to 2	May be >10
Atypical mitoses	Absent	May be present
Pattern of growth	Uniform	Organoid, fascicles, occasional nuclear palisading
Cellularity	Mild, focally moderate	Moderate to high
Vessels	Muscular arteries, dilated thin veins	Hyalinized vessel walls
Keloid-type collagen	Often present	Absent
Cystic degeneration	Absent	May be present
Necrosis	Absent	May be present
Margins	Infiltrative	Usually pushing
CD117	Cytoplasmic only, coarsely granular	Cytoplasmic with membrane accentuation
CD34	Negative	Usually positive
β-catenin	Positive (nuclear)	Negative

In our case, the mass was 1) well-circumscribed, 2) mild to moderately cellular, 3) composed of spindle cells arranged haphazardly, at places in fascicles & storiform pattern, 4) individual cells showing wavy pattern at places 5)showed bands of collagen amidst the proliferating cells, 6)Thin-walled compressed & few dilated vascular channels, 7) focal coarse granular positivity for C-Kit (CD117), negative for CD34, DOG-1, desmin, S100 and SMA, MIB-1 proliferative index low (2-3%) & overexpression of β- catenin was seen.

Considering all the histopathological features and correlating with IHC profile, diagnosis of mesenteric fibromatosis was confirmed.

CONCLUSION

In conclusion, MF is an uncommon benign locally aggressive but not meta stasizing mesenchymal tumor often confused with GIST, which is a potentially malignant tumor. In doubtful cases, histological features along with immuno histochemistry allow a decisive diagnostic differentiation. Correct identification of the lesion is of the utmost clinical importance because MF and GIST are widely diverse processes from biologic, clinical, prognostic, and therapeutic standpoints.

REFERENCES

[1] Burke AP, Sobin LH, Shekitka KM, Federspiel BH, Helwig EB. Intra-abdominal fibromatosis. A pathologic analysis of 130 tumors with comparison of clinical subgroups. Am J SurgPathol1990; 14: 335-341

[2] Yannopoulos K, Stout AP. Primary solid tumors of the mesentery. Cancer. 1963;16:914-927.

[3] Al Nafussi A, Wong NA. Intra-abdominal spindle cell lesions: a review and practical aids to diagnosis. Histopathology 2001;38: 387-402

[4] Kindblom LG, Remotti HE, Aldenborg F, Meis Kindblom JM. Gastrointestinal stromal tumors show phenotypic characteristics of the interstitial cells of Cajal. Am J Pathol1998; 152: 1259-1269

[5] Robinson TL, Sircar K, Hewlett BR, Chorneyko K, Riddell RH, Huizinga JD. Gastrointestinal stromal tumors may originate from a subset of CD34-positive interstitial cells of Cajal. Am J Pathol2000; 156: 1157-1163

[6] Weiss S, Goldblum JR. Enzinger and Weiss's Soft Tissue Tumors. 4th ed. St Louis, MO: Mosby; 2001:309-346.

[7] Stout AP. Fibrosarcoma, the malignant tumor of fibroblasts. Cancer. 1948;1:30-63.

[8] Rosai J. GIST: an update. Int J Surg Pathol. 2003;11:177-186.

[9] Kempson RL, Fletcher CDM, Evans HL, et al. Tumors of the Soft Tissues. Washington, DC: Armed Forces Institute of Pathology; 2001:78-81.

[10] Bridge JA, Sreekantiah C, Mouron B, et al. Clonal chromosomal abnormalities in desmoid tumors: implications for histo pathogenesis. Cancer.1992;69:430-436.

[11] Li M, Cordon-Cardo C, Gerald W, et al. Desmoid Fibromatosis is a clonal process. Hum Pathol. 1996;27:939-943.

[12] Middleton SB, Frayling IM, Phillips RK. Desmoids in familial adenomatous polyposis are monoclonal proliferations. Br J Cancer. 2000;82:827-832.

[13] Alman BA, Li C, Pajerski ME, et al. Increased beta-catenin protein and somatic APC mutations in sporadic aggressive fibromatoses (desmoid tumors). Am J Pathol. 1997; 151: 329-334.

[14] Yantiss R.K., Sipro I J., Compton C., Rosenberg A.: Gastrointestinal stromal tumor versus intra-abdominal fibromatosis of the bowel wall: a clinically important differential diagnosis. Am. J. Surg. Pathol.2000; 24:947-957.

[15] Monihan J.M., Carr N J., Sobin L.H.: CD34 immuno expression in stromal tumors of the gastrointestinal tract and in mesenteric fibromatosis. Histopathology 25:469-473, 1994.

[16] Rodriguez J. A., Guarda L.A., Rosa J.: Mesenteric fibromatosis with involvement of the gastrointestinal tract. A GIST simulator: a study of 25 cases. Am. J. Clin. Pathol. 121: 93-98, 2004.

.