International Journal of Allied Medical Sciences and Clinical Research (IJAMSCR)

ISSN: 2347-6567

IJAMSCR |Volume 3 | Issue 2 | April-June- 2015
www.ijamscr.com

Research article Medical research

The craniometric study of foramen magnum of Indian population and variations in its dimensions

Dr.Gopalakrishna. K[1*] and Dr.B.S.Rathna[2]

[1]*Assistant Professor, Department of Anatomy, Malabar Medical College and Research Centre, Modakkallur, Atholi, Calicut- 673315 Kerala, India.*

[2]*Professor and Head, Department of Anatomy, Malabar Medical College and Research Centre, Modakkallur, Atholi, Calicut- 673315 Kerala, India.*

***Corresponding Author: Dr. Gopalakrishna. K**

E-mail: gkemail01@gmail.com

ABSTRACT

OBJECTIVE

Evaluation of the measurements of the foramen magnum in male and females skulls of Indian origin as well as to observe the variations in its shape

INTRODUCTION

The foramen magnum is the large opening located in the occipital bone of skull. The dimensions of the foramen magnum are greater in males than in females. It is used to determine sex of skeleton in the medicolegal conditions such as explosions, aircraft accidents and war injuries. Dimensions and its variations are important in dealing with different neurosurgical conditions and surgeries.

MATERIALS AND METHODS

This descriptive study was performed on fifty five (n=55) dry adult human skulls on following parameters. 1) Antero posterior diameter, 2) Transverse Diameter, 3) Shape of the foramen. Procedure: The parameters and shapes were carefully inspected and noted with proper illumination by single observer in uniform manner on a work sheet. Descriptive Statistics, Student's t test and correlation between the groups were analysed for statistical significance at $\alpha < 0.05$.

RESULT

In males the mean Sagittal and transverse diameter was 34.72±2.95 and 28.4±2.37 with correlation coefficient of r=0.858. In females it was 33.21±3.25 and 27.71±2.6 with correlation coefficient of r=0.899. The scatter diagram revealed a linear form, positive relationship. Results were presented with tables and scatter plots.

CLINICAL SIGNIFICANCE AND CONCLUSION

The dimensions of foramen magnum are not constant between male and females, and between different populations. The knowledge on the dimension, shape with its normality and laterality is essential for determination of sex in forensic science, diagnostic and planning and conducting neurosurgical procedures at cranio-vertebral junction with effective management, better result and prognosis.

KEY WORDS: Foramen magnum, shape, Measurements, Variations.

INTRODUCION

The foramen magnum is the large opening located in the occipital bone of skull in the median plane. It is surrounded by squamous part posteriorly, basilar part anteriorly, and two condyles on right and left lateral sides. It communicates posterior cranial fossa with the vertebral canal. It plays important role in determination of sex of skeleton in the field of forensic medicine, archaeology and anatomy departments [1, 2]. The diameters and area of the foramen magnum are greater in males than in females, hence its dimensions can be used to determine sex in the medico legal conditions such as explosions, aircraft accidents and war injuries [3,4]. The dimensions of the Foramen magnum are very important in dealing with compression during achondroplasia of foramen magnum [5], brain herniation [6, 7] and in neurosurgical approach to access the lesions located anterior to the brainstem [8] and in malformations like Arnold Chiari syndrome, which shows expansion of transverse diameter [9]. Furthermore, Wanebo et al [10] stated that longer foramen magnum sagittal diameter permitted greater contralateral surgical exposure for condylar resection. This study is aimed to evaluate the measurements of the foramen magnum in male and females skulls of Indian origin as well as to observe the variations in its shape.

MATERIALS AND METHODS

This descriptive study was performed on fifty five (n=55) non-pathological dry adult human skulls were randomly selected from department of anatomy, Malabar Medical College And Research Centre, Modakkallur, Calicut, Kerala, India- during November 2013 to November 2014.

INCLUSION CRITERIA

The skulls regular in shape and devoid of deformities in the occipital bone were selected.

EXCLUSION CRITERIA

The damaged, fractured, eroded, with degenerative changes or deformed skulls and those having evidence of pathological abnormalities were excluded.

INSTRUMENTS

Magnifying lens, calipers of 1/20 mm accuracy have been used.

PARAMETERS

1. Antero posterior diameter- straight line length from basion to opisthion along the median plane. (Figure-1)
2. Transverse Diameter- Distance of the point of maximum concavity on right and left margins perpendicular to the median plane
3. Shape of the foramen

PROCEDURE

The parameters were carefully inspected and noted with proper illumination. The shape of the foramen magnum were observed and recorded. They were classified according to Richards and Jabbour method[11], where foramen magnum was classified into following shapes-

1. Circular
2. Two Semicircle
3. Heart-like
4. Wide oval
5. Bi-rounded oval
6. Ventrally wide oval
7. Bi-pointed oval
8. Dorsally convergent oval.

The data were obtained with Craniometrical measurements (sagittal and transverse diameter) of the foramen magnum (figure-1) with a millimetric sliding caliper by single observer in uniform manner on a work sheet. Average of two readings was taken. When the two readings were found to be having difference of more than 0.1 mm, a third reading was performed according to the Method recommended by Krag et al [12], and Scoles et al [13].

STATISTICAL ASSESSMENT [14, 15]:

The mean and standard deviation were calculated manually. The comparisons of mean values of the male and female skull were made. The statistical analysis for sex comparison was made by Student's t test. Relationships between the study parameters were determined by Pearson correlation coefficients. Statistical assessment with p-values < 0.05 was considered significant.

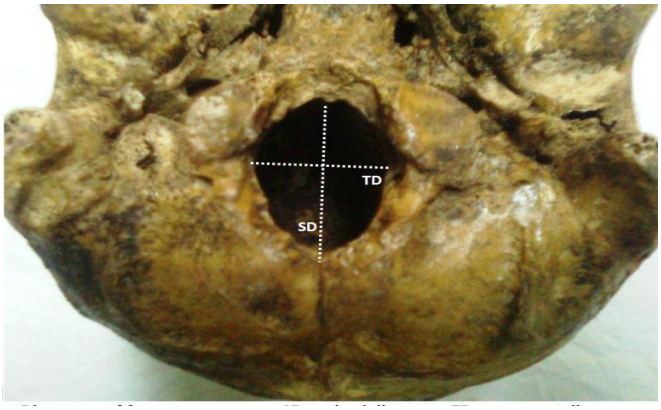

Figure-1. Diameters of foramen magnum.SD-sagittal diameter, TD-transverse diameter

OBSERVATION

In the present study, totally fifty five (n=55) dry adult human skulls were studied. The measurements were presented in the following tables and figures. The following different shapes of foramen magnum were observed as shown below (table-1, figure-2 & 3). Oval shape (41.0%), round shape (25.0%), irregular shape (20.0%), tetragonal shape (14.0%)

Table-1. Showing the Frequency of Different Shapes of Foramen Magnum (n=55)

	Shape	*Frequency*	*Percent*
1	Round	14	25.0%
2	Oval	22	41.0%
3	Tetragonal	08	14.0%
4	Irregular	11	20.0%

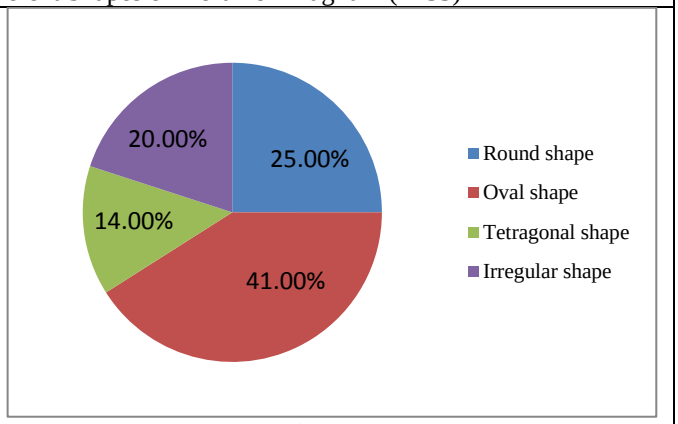

Figure 2.



A-Round shape **B-**Tetragonal shape **C**-Oval shape

Figure-3.The different shapes of foramen magnum

Descriptive statistics with values of the maximum, minimum, means and standard deviations of measurements the Foramen Magnum in both males and females are presented in the following table-2.

Table-2 Morphometric Data of foramen magnum.

Sex	***Parameters***	***Max (mm)***	***Min (mm)***	***Mode (mm)***	***Mean (mm)***	***SE***	***(r)***
Male	Sagittal diameter	39.5	27.6	34.1	34.72±2.95	0.39	0.858
	Transverse diameter	34.4	24.3	29.6	28.4±2.37	0.32	
Female	Sagittal diameter	38.1	26.3	34.6	33.21±3.25	0.44	0.899
	Transverse diameter	33.3	23.8	25.7	27.71±2.6	0.35	

Max =Maximum, Min= Minimum, SE=Standard Error, r= Correlation.

The scatter diagrams [Scatter plot 1and 2] reveals a linear form, positive association between sagittal diameter and transverse diameter of foramen magnum. The prominent outliners were not found. Moderately strong strength of relationship between the sagittal diameter and Transverse diameter can be observed in both scatter diagrams. The correlation coefficient of r=0.858 in male and r=0.899 in female dataset shows a moderate correlation with upward trend. The coefficient of determination quantifies that 73.6% of the variation in transverse diameter in males and 80.7% in females is related with the change in sagittal diameter of foramen magnum. The correlation coefficient of was statistically significant at α=0.05.

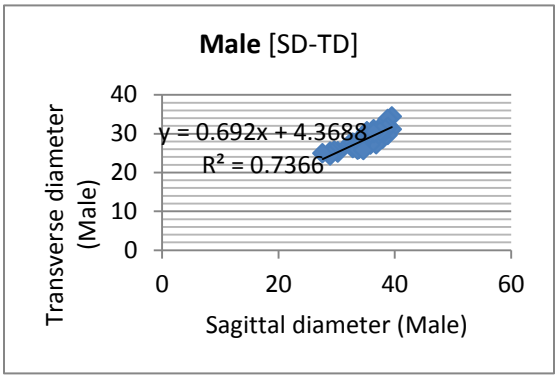

Scatter plot 1.

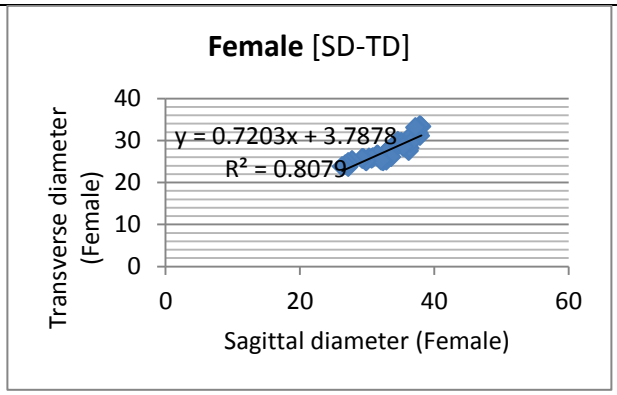

Scatter plot 2.

Scatter plots of the correlation between sagittal diameter and Transverse diameter of foramen magnum (mm). SD= Sagittal diameter, TD= Transverse diameter.

DISCUSSION

Comparisons of present results with previously published studies were done and it is presented in following tables. The present study has revealed the significant variations in size and shape of foramen in male and female skulls. The irregular shape of foramen magnum is accentuated by the developmental anomalies of the bone and soft tissues at the cranio-vertebral junction [16].

HIGHER DIMENSIONS IN MALE SKULL THAN FEMALES

Significant differences were observed in the values from males and female skulls for sagittal diameter and Transverse diameter of foramen magnum. Studies [17, 20, 21, 22, 23, 24] have reported similar views (Table-3). It is helpful in determination of sex of skull or skeleton in forensic departments and anthropology [25].

Table-3 Comparison of study results on - Indian population

Authors	Sagittal diameter (mm)		Transverse diameter (mm)	
	Male	**Female**	**Male**	**Female**
Babu Raghavendra YP et.al [17]	36.40 ± 3.27	31.62 ±2.05	32.93 ± 2.35	28.32 ± 2.12
Fatma Hayat Erdil et al [18]	30.75	29.98	36.95	34.41
Muralidhar PS et al [19]	38.5	35.2	29.1	27.6
Kanchan T [20]	34.51 ±2.77	33.60 ±2.63	27.36 ±2.09	26 .74 ± 2.36
Routal RR et.al [21]	35.5 ± 2.8	32.0 ± 2.8	29.6 ± 1.9	27.1 ± 1.6
Singh G et.al [22]	33.54 ±2.80	32.31 ±3.24	27.77 ±2.10	27.21 ±2.99
Radhakrishna SK et.al [23]	34.04±2.36	31.72±2.14	28.63±1.89	26.59±1.64
Santhosh CS et al[24]	34.37 ± 2.38	33.80 ± 2.56	28.98 ± 2.22	27.60 ± 2.67
Present study	34.72±2.95	33.21±3.25	28.4±2.37	27.71±2.6

RACIAL DIFFERENCE IN DIMENSIONS

Study results on different populations by different scholars were shown in table-4. It can be observed that the dimensions of foramen magnum are not constant between male and females and between different populations

Table-4 Racial difference in dimensions of foramen magnum

-	Research by	Population	Gender	Sagittal diameter (mm)	Transverse diameter (mm)
1	Manoel C et al [26]	Brazilian	Male	35.7 ± 0.29	30.3 ± 0.20
			Female	35.1 ± 0.33	29.4±0.23
2	Murshed KA et al [27]	Turkish	Male	37.2 ± 3.43	31.6 ± 2.99
			Female	34.6 ± 3.16	29.3 ± 2.19
3	Herrera CJC at al [28]	Spanish	Male	36.2 ± 0.3	31.1 ± 0.3
			Female	34.30 ± 0	29.6 ± 0.3
4	Gruber P et al [29]	Europe	Min-max	30 to 43	25 to 39
			Mean	36.6	31.1
5	Present study	Indian	Male	34.72±3.23	28.12±3.42
			Female	33.82 ±4.35	27.03±4.71

CLINICAL SIGNIFICANCE

The following structures are passing through the foramen magnum- the medulla oblongata, meninges, accessory spinal nerve, dural sinuses, vertebral and spinal arteries. Hence it is important for neurosurgery, anthropology, and forensic science, radiological and diagnostic procedures.

FORENSIC MEDICINE

The foramen magnum reaches its adult size rather early in childhood. During the determination of sex of incomplete or damaged skeletons, the foramen magnum plays a vital role in medicolegal cases such as explosions, aircraft accidents and war injuries [3,4].

POPULATION DIFFERENCES

Population differences also have impact on size of foramen magnum. Therefore, it is necessary to know the source population of any unidentified skull.

SURGERIES

Dimensions of foramen are important Regarding Occipital condyle resection in transcondylar approach [30], compression of vital structures in foramen magnum achondroplasia [31] and herniation of brain [32]. Wanebo et al [33], stated that longer foramen magnum sagittal diameter permits greater contralateral surgical exposure for condylar resection.

VARIATION IN SHAPE

Variations of the shape of foramen magnum have got diagnostic, clinical and radiological importance [(34)].

THE LIMITATIONS OF STUDY

Small sample size, exact age is not determined; CT and MRI scans were not used.

CONCLUSION

The present study concludes that the dimensions of foramen magnum are not constant between male and females, and between different populations. The knowledge on the dimension, shape with its normality and laterality is essential for determination of sex in forensic science, diagnostic and planning and conducting neurosurgical procedures at cranio-vertebral junction with effective management, better result and prognosis.

ACKNOWLEDGEMENTS

The authors are grateful to scholars / editors / publishers of the articles, journals and text books mentioned in the references of this manuscript, from where the literature for this article has been reviewed and discussed. Authors gratefully acknowledge all the authorities of the college, teaching, non-teaching staff members and students for their help, support and cooperation.

FOOTNOTES

FUNDING

Authors wish to clarify that they have not received any financial support or funding from any commercial sources.

CONFLICT OF INTEREST

There is no conflict of interest to be declared.

REFERENCES

[1] Krogman WM, Iscan MY. Skeletal Age: Cranium, Skeletal Age: Post Cranium and Determination of Sex and Parturition. In: The Human Skeleton in Forensic Medicine. 2nd ed. USA: Charles C Thomas Publishers, 1986: 103-267.

[2] Luiz AS and Marco S. Sexing the human skull through the mastoid process. Rev. hosp. Clin. Fac. Med. S. Paulo, 2003; 58(1): 15-20.

[3] Sgouros S, Goldin HJ, Hockely AD, Wake MJ, et al. Intracranial volume change in childhood. Journal of Neurosurgery. 1999; 91:610-616

[4] Gunay Y, Altinkok M. The value of the size of foramen magnum in sex determination.Journal of Clinical & foirensic Medicine.2000;7(3):147-49.

[5] Hecht TJ, Horton WA, Reid CS, et al. Growth of the foramen magnum in achondroplasia. American Journal of Medical Genetics.1989;32: 528-35.

[6] Reich JB, Sierra J, Camp W, et al. Magnetic resonance imaging measurements and clinical changes accompanying transtentorial and foramen magnum brain herniation. Annals of Neurology.1993; 33: 159-70.

[7] Ropper AH. MRI demonstration of the major features of herniation. J Neurol Neurosurg Psychiatry.1993; 56: 932-5.

[8] Muthukumar N, Swaminathan R, Venkatesh G, Bhanumathy SP: A morphometric analysis of the foramen magnum region as it relates to the transcondylar approach. Acta Neurochir (Wien.) 2005;147:889-895.

[9] Sgouros S, Goldin HJ, Hockely AD, Wake MJ, et al. Intracranial volume change in childhood. J Neurosurg; 1999;91:610-616.

[10] Wanebo JE, Chicoine MR. Quantitative analysis of the transcondylar approach to the foramen magnum. Neurosurgery.2001;49: 934-41.

[11] Richards GD, Jabbour RS. Foramen magnum ontogeny in Homo sapiens: a functional matrix perspective. Anat Rec.2011; 294: 199–216.

[12] Krag MH, Waever DL, Beynnon BD, Haugh LD. Morphometry of the thoracic and lumbar spine related to transpedicular screw placement for surgical spine fixation. Spine. 1988; 13:27–32.

[13] Scoles PV, Linton AE, Latimer B, Levy ME, Digiovanni BF. Vertebral body and posterior element morphology: the normal spine in middle life. Spine. 1988. 13:1082–1086.

[14] B.Burt Gerstman. Basic Biostatistics: Statistics for public health practice. Johnes and Bartlett publications, Inc. Sudbury, Massachusetts .2008. Page 63-83, 210-250,295-332.
[15] Carol E Osborn. Basic Statistics for heath information management technology. Johnes and Bartlett publications, Inc. Sudbury, Massachusetts.2008. Page 109-137,174-185, 193-202.
[16] Furtado SV, Thakre DJ, Venkatesh PK, Reddy K, Hegde AS. Morphometric analysis of foramen magnum dimensions and intracranial volume in pediatric chiari I malformation. Acta Neurochir (Wien). 2010; 152:221-227
[17] Babu Raghavendra YP , Manjunath S, Rastogi Prateek, Kumar Mohan TS, Bhat Vrinda, et al. Determination of Sex by Foramen Magnum Morphometry in South Indian Population. Indian J Forensic Med Pathol. 2011;4(1):29-33.
[18] Fatma Hayat Erdil, Vedat Sabancýoðullarý, Mehmet Çimen, Oktay Iþýk: Morphometric Analysis of the Foramen Magnum by Computed Tomography. Erciyes Medical Journal. 2010; 32(3):167-170.
[19] Muralidhar PS, Magi M. Morphometric analysis of foramen magnum. Int J Anat Res. 2014; Vol-2(1):249-55.
[20] Tanuj Kanchan, Anadi Gupta, and Kewal Krishan. Craniometric Analysis of Foramen Magnum for Estimation of Sex. World Academy of Science, Engineering and Technology 2013; 79.
[21] Routal RR, Pal GP, Bhagwat SS. Metrical studies with sexual dimorphism in foramen magnum of human crania. J Anatom Soc India. 1984; 2(33): 85-89.
[22] Gagandeep Singh, Indu Talwar. Morphometric analysis of foramen magnum in human skull for sex determination. Human Biol Rev. 2013; 2(1):29-41.
[23] Radhakrishna SK, Shivarama CH, Ramakrishna A, Bhagya B. Morphometric analysis of foramen magnum for sex determination in south Indian population. NUJHS. 2012; 2(1):20-22.
[24] Santhosh CS et al.Morphometry of the Foramen Magnum: An Important Tool in Sex Determination. Research and Reviews: Journal of Medical and Health Sciences. 2013; Volume 2, (4) October-December, 88-91.
[25] Catalina-Hercera CJ. Study of the Anatomical matrix values of the foramen magnum and its relationship with sex. Acta Anat (Basel).1987;130(4):344-7.
[26] Manoel C, Prado FB, Caria PHF, Groppo FC. Morphometric analysis of the foramen magnum in human skulls of brazilian individuals: its elation to gender. Braz J Morphol Sci 2009; 26(2): 104-108.
[27] Murshed KA, Çiçekçibasi AE, Tuncer I. Morphometric Evaluation of the Foramen Magnum and Variations in its Shape: A Study on Computerized Tomographic Images of Normal Adults. Turkish J Med Sci. 2003; 33(1): 301-306.
[28] Herrera CJC. Study of the anatomic metric values of the foramen magnum and its relation to sex. Acta Anatomica. 1987; 130: 344-347.
[29] Gruber, P., Henneberg, M., Böni, T. and Rühli, F. J. Variability of Human Foramen Magnum Size. Anat Rec.2009; 292:1713–19.
[30] George B, Lot G, Boissonnet H. Meningioma of the foramen magnum: A series of 40 cases. Surg Neurol. 1997;47: 371-9.
[31] Hecht TJ, Horton WA, Reid CS, et al. Growth of the foramen magnum in achondroplasia. American Journal of Medical Genetics.1989; 32: 528-35.
[32] Ropper AH. MRI demonstration of the major features of herniation. J Neurol Neurosurg Psychiatry. 1993; 56: 932-5.
[33] Wanebo JE, Chicoine MR. Quantitative analysis of the transcondylar approach to the foramen magnum. Neurosurgery. 2001; 49: 934-41.
[34] Murshed KA, Cicekcibasi AE, Tuncer I: Morphometric evaluation of the foramen magnum and variations in its shape: A study on computerized tomographic images of normal adults. Turk J Med Sci. 2003; 33:301-306