International Journal of Allied Medical Sciences and Clinical Research (IJAMSCR)

ISSN:2347-6567

IJAMSCR |Volume 10 | Issue 2 | Apr - Jun - 2022
www.ijamscr.com

Case Study *Medical*

A rare pediatric case report of MOG positive parainfectious Longitudinal extensive Transverse myelitis

Dr Shatanshi Shukla[1] , Dr Jean pratheesh J[1], Dr Vivek Sirolia,[2] Dr Siddarth Aggarwal [1], Dr Mamta Dhaneria [3]

1. *Junior Resident, Department of Peadiatrics, R.D. Gardi Medical College, Ujjain, Madhya Pradesh, India.*
2. *Assistant Professor, Department of Peadiatrics, R.D. Gardi Medical College, Ujjain, Madhya Pradesh, India.*
3. *Professor & Head, Department of Peadiatrics, R.D. Gardi Medical College, Ujjain, Madhya Pradesh, India.*

***Corresponding author: Dr. Shatanshi Shukla**
Email: Shatanshi.shukla@gmail.com

ABSTRACT

MOG-AD is a distinct nosological entity with specific management and therapeutic requirements.[1] Optic neuritis is the most frequent presenting phenotype. The disease course can be either monophasic or relapsing, with subsequent relapses most commonly involving the optic nerve. MOG-associated myelitis is a less frequent clinical phenotype observed in children at their initial event. In the present article, we present a rare pediatric case of clinically diagnosed transverse myelitis with a positive anti-MOG antibody. A 13 year-old patient presented with weakness on both legs and decreased sensation below T2 level with bowel and bladder retention 2 weeks preceding a varicella infection. MOGAD may be a severe relapsing and devastating disorder for a subgroup of patients. Moderate response to current standard chronic therapies. Additional safe and long-term efficacious treatment options are still much needed for children with relapsing MOGAD.

Keywords: Myelitis, Phenotype, Neuritis.

INTRODUCTION

MOG-AD is a distinct nosological entity with specific management and therapeutic requirements.[1] Optic neuritis is the most frequent presenting phenotype. Disease course can be either monophasic or relapsing, with subsequent relapses most commonly involving the optic nerve. MOG-associated myelitis is less frequent clinical phenotypes observed in children at their initial event. In the present article, we present a rare pediatric case of clinically diagnosed transverse myelitis with positive anti-MOG antibody.

CASE REPORT

A 13 year-old patient presented with weakness on both legs and decreased sensation below T2 level with bowel and bladder retention 2 weeks preceding a varicella infection. Contrast MRI spine revealed extensive intramedullary hypersignal intensity of spinal cord extending from D2 to Conus (figure 1 and 2). Contrast MRI brain and Orbit were normal Serology studies were negative for oligoclonal band and anti-aquaporin-4 but positive for anti-MOG. Patient was treated with intravenous pulse methylprednisolone for five days and partially recovered.



Fig 1: Contrast MRI of spine

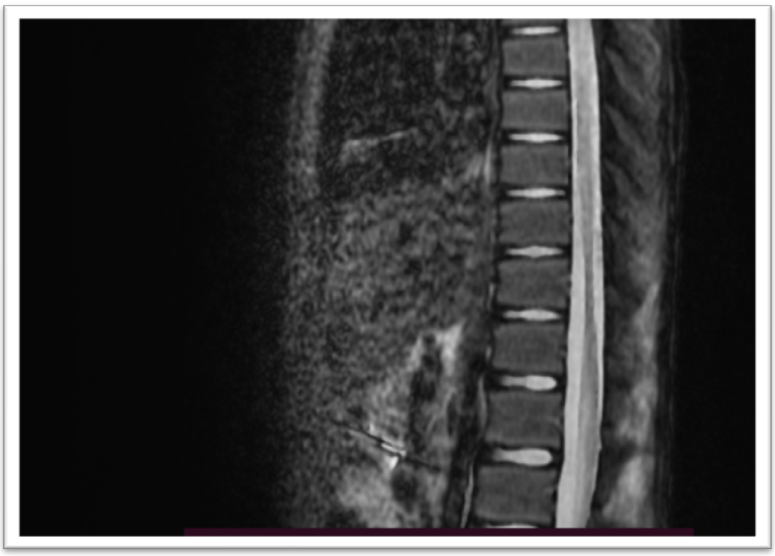

Fig 2: Contrast MRI of spine

Alternative diagnostic considerations according to the clinical presentation in pediatric MOG-associated transverse myelitis included Postinfectious myelopathy, Infectious myelopathies, Acute flaccid paralysis (Non polio enteroviruses and flavivures) , Systemic disease: lupus, Sjögren, sarcoidosis-associated, myelopathy, Vascular: infarct, arteriovenous malformations, vasculitis, AQP4-IgG–associated myelitis, NMOSD, GFAP-IgG–associated myelitis , Biotinidase deficiency (late-onset form), Vitamin B12 deficiency (subacute combined degeneration of spinal cord), Neoplastic: lymphoma, glioma, ependymoma. The examination of CSF showed protein – 52, glucose 72, 4 cells and all lymphocytes.

DISCUSSION

High anti - MOG antibody titers are frequently observed among pediatric patients with recurrent optic neuritis. Huppke et al. reported that seven pediatric patients with acute disseminated encephalomyelitis (ADEM) followed by optic neuritis were positive for anti-MOG antibodies, but not anti-AOP4 antibodies.[2] We present the first report of a patient with anti-MOG antibody-positive LETM after varicella infection. Varicella infection triggers various autoimmune diseases, included neurological disorders (e.g., Guillain-Barre syndrome and ADEM). Our case showed that varicella infection may trigger anti-MOG-IgG positive myelitis. Presence of serum antiMOG antibodies has been recently proposed as a new inflammatory disease of the CNS driven by antibodies of the IgG1 class, which target MOG expressed on myelin sheaths and promote demyelination. Transverse myelitis at onset was a significant predictor of long-term disability.[3] Wide spectrum of MOG-associated CNS demyelination is now better understood. Most children have a good clinical outcome.

MOGAD may be a severe relapsing and devastating disorder for a subgroup of patients. Moderate response to current standard chronic therapies. Additional safe and long-term efficacious treatment options are still much needed for children with relapsing MOGAD.

CONCLUSION

MOGAD may be a severe relapsing and devastating disorder for a subgroup of patients. Moderate response to current standard chronic therapies. Additional safe and long-term efficacious treatment options are still much needed for children with relapsing MOGAD.

REFERENCES

1. De Mol C, Wong Y, van Pelt E, Wokke B, Siepman T, Neuteboom R et al. The Clinical spectrum and incidence of anti-MOG-associated acquired demyelinating syndromes in children and adults. Mult Scler J. 2020;26(7):806-14. doi: 10.1177/1352458519845112.
2. Huppke P, Rostasy K, Karenfort M, Huppke B, Seidl R, Leiz S et al. Acute disseminated encephalomyelitis followed by recurrent or monophasic optic neuritis in pediatric patients. Mult Scler. 2013;19(7):941-6. doi: 10.1177/1352458512466317, PMID 23128668.
3. Jurynczyk M, Messina S, Woodhall MR, Raza N, Everett R, Roca-Fernandez A, et al. Clinical presentation and prognosis in MOG-antibody disease: a UK study. Brain. 2017;140(12):3128-38. doi: 10.1093/brain/awx276, PMID 29136091.