



International Journal of Allied Medical Sciences and Clinical Research (IJAMSCR)

ISSN:2347-6567

IJAMSCR | Volume 7 | Issue 2 | Apr - June - 2019
www.ijamscr.com

Case Report

Medical research

Hypertension induced posterior reversible encephalopathy syndrome in children: A report of two cases

Rishitha Krishna Kantheti, Sowmya Tirumala*, Joseph Priyatham Reddy Thumma, Rajender Penthala, Dr. Devender Kodati

Department of Pharmacy Practice, St. Peters Institute of Pharmaceutical Sciences, Warangal-506001, Telangana State, India.

*Corresponding author: Rishitha Krishna Kantheti

Email: sowmyatirumala68@gmail.com

ABSTRACT

Introduction

Posterior reversible encephalopathy syndrome (PRES) is a reversible disorder with typical radiological findings. Majority of patients with PRES are in adults and rarely seen in children.

Case presentation

In this report two patients with PRES were presented. In both the patients the primary diagnosis was found to be severe hypertension, seizures with loss of consciousness and glomerulonephritis.

Conclusion

As posterior reversible encephalopathy syndrome is rarely seen in children, it should be treated symptomatically to relieve the symptoms, if not treated it may lead to further complications like cerebral haemorrhage, cerebral herniation and refractory status epilepticus.

Keywords: Severe hypertension, Seizures, Glomerulonephritis.

INTRODUCTION

Posterior reversible encephalopathy syndrome (PRES) or reversible posterior leukoencephalopathy syndrome (RPLS) is usually a reversible clinical syndrome which is becoming more increasingly recognised, in large part because of improved and more readily available neuroimaging [1]. It is a distinctive imaging and clinical syndrome characterized by altered sensorium, seizures, acute headaches and visual impairment. It has also been associated with various systemic conditions such as severe hypertension and renal failure [2]. The

pathophysiology of PRES is not clearly known but the vasogenic edema has been established as the pathogenomic change in the brain in patients with PRES [3]. Two theories have been proposed behind the development of vasogenic edema: 1) Severe hypertension leading to failed auto-regulation, subsequent hyperperfusion, with endothelial injury and 2) Hypoperfusion and vasoconstriction leads to brain ischemia and subsequent vasogenic edema [4]. Although there are some limitations, cranial MRI is the gold standard of imaging studies for the detection of lesions in PRES [5]. In this report we present two patients with PRES where the primary diagnosis was seizures disorder with loss of

consciousness. Seizures disorder is a frequently encountered disease by the neurologists and may also display hypertension in their disease course.

CASE REPORTS

Case Presentation 1

A 13 years old male patient was admitted to a local hospital with chief complaints of 2 episodes of seizures at 4'o clock in the morning on the day of admission, each seizure lasting for 5minutes and loss of consciousness for 15minutes each episode and also other complaints include fever since 3days with cold and cough. On physical examination the patient was moderately built weighing 35kgs; blood pressure was 160/100 mmHg. Laboratory tests were as follows: Haemoglobin was 13gm%, WBC 13,500/mm³, Neutrophils 12,150/mm³, Lymphocytes 10,800/mm³, Esinophils 00/mm³, Monocytes 270/mm³, Basophils 00/mm³. Blood urea 55mg/dl and serum creatinine 5.6mg/dl. Urine protein 216mg/dl, potassium 5.3Eq/L, chlorine 115mEq/L. Urine analysis: albumin was positive, epithelial cells were 1-2, pus cells 2-4, RBC's were found to be plenty. ASO 293.7 IU/ml (reference range 0-200IU/ml). The patient was hospitalised with the diagnosis of seizures and loss of consciousness and was treated with the standard therapy. Tablet Furosemide 10mg was given intermittently for hypertension and injection Levetiracetam dosing 1g was given with 100ml Normal saline twice daily to treat seizures. On the 3rd day MRI brain was performed which demonstrated PRES/acute disseminated encephalomyelitis (ADEM) less likely and USG abdomen demonstrated small left pleural effusion and enlarged left adrenal gland where the final diagnosis was made as glomerulonephritis with seizures disorder, LRTI and PRES. Based on the USG abdomen report injection Levetiracetam was replaced with tablet Sodium valproate 300mg in the morning and 500mg at night as levetiracetam excretes renally. EEG revealed febrile encephalopathy. The patient was given with supportive therapy, anti-hypertensives and anti-

epileptics. His clinical status was improved and the patient was discharged and was advised for review after 10 days with MRI.

Case presentation 2

A 13 year old male patient was admitted to a local hospital with the chief complaints of fever since 1 week, shortness of breath since 2 days, 3 episodes of vomitings on the day of admission, one episode of seizure with loss of consciousness for 20 minutes. On Physical examination, the patient was moderately built weighing 45kgs and the patient was conscious and confused. Vitals were found to be: Temperature 100°F, B.P 150/80mmHg, pulse rate 102b/m. Laboratory tests were as follows: haemoglobin 13gm%, WBC 12,600/mm³, neutrophils 12,135/mm³, lymphocytes 4,250/mm³. Dengue check was weakly positive, widal test was also found to be positive and the urine protein was found to be 516.1mg/dl, urine creatinine 81mg/kg, ASO 216.1IU/ml, complement C3-0.06g/L, complement C4-0.07g/L. Potassium 5.8Eq/L, chlorine 93mEq/L. Urine analysis: albumin was positive, epithelial cells 2-4, pus cells 6-8, RBCs 16-18, bacteria and yeast cells were observed. The CT scan of the brain demonstrated hypodensity in the right posterior parietal region and post ictal edema. MRI brain demonstrated posterior reversible encephalopathy syndrome/ acute disseminated encephalomyelitis (ADEM) less likely and USG abdomen demonstrates thickened gallbladder wall and bilateral small pleural effusions. Injection Levetiracetam dosing 1g was given with 100ml NS twice daily to treat seizures. On day 3 B.P was found to be 160/80mmHg and on examination facial puffiness was observed, so tablet Nifedipine 10mg was given if required to treat hypertension and tablet Torsemide 5mg was added once daily to treat facial puffiness. On day3 injection Levetiracetam was replaced with tablet Sodium valproate 300mg in the morning and 500mg at night as levetiracetam excretes renally. Supportive treatment was given and the patient was discharged to review after 10days with MRI report.

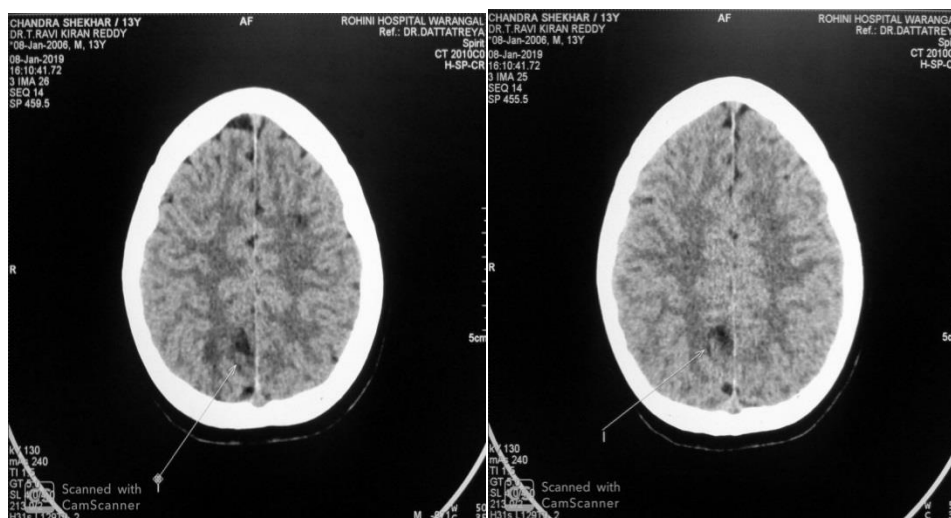


Fig. 1: CT scan of brain demonstrating hypodensity in right posterior parietal region and post ictal edema

DISCUSSION

Posterior reversible encephalopathy syndrome or Reversible leukoencephalopathy syndrome is a neurological disorder characterised by a variety of neurological symptoms often associated with elevated arterial blood pressure, pre-eclampsia, eclampsia, autoimmune disorders where the onset may be sub-acute or acute in which the symptoms develop within few hours up to several days or weeks [1]. The patients may also present with the signs of encephalopathy, epileptic seizures which are common in majority of patients. Patients with glomerulonephritis, stage2 hypertension, High grade fever, seizures with loss of consciousness and enlargement of adrenal gland were reported to develop PRES [6]. The basic clinical features associated with PRES are severe hypertension, seizures, headache, confusion, vomiting, thrombocytopenic purpura, sepsis and infections [4]. The pathogenesis of PRES is not exactly known but there are two widely accepted theories including vasospasm and vasogenic theory. According to vasospasm theory, severe vasospasm occurs with severe rise in blood pressure and hypoperfusion of brain parenchyma occurs as a result of the vasospasm of cerebral vessels. The resulted ischemia leads to development of cytotoxic edema with or without actual cerebral infraction. Hypoxic change leads to endothelial cell damage [7].

As per vasogenic theory rapid rise in blood pressure results in autoregulatory failure of cerebral vasculature and dilation of cerebral arterioles subsequently producing brain hyperperfusion. The opening of endothelial type junctions, extravasation of fluid and blood products into the brain parenchyma causes vasogenic cerebral edema [2]. The first patient had the diagnosis of enlarged left adrenal gland and small left pleural effusion. Enlargement of the adrenal gland may be the main cause of severe hypertension which resulted in seizures which is one of the main cause of PRES. Although increase in blood pressure is the main cause of this syndrome, various superimposable pathological mechanisms facilitate the appearance. Both the elevated blood pressure, seizures and the enlarged adrenal gland and glomerulonephritis played an important role in facilitating the diagnosis of PRES. In the second case, seizures, severe hypertension, confusion, post ictal edema and glomerulonephritis facilitated the diagnosis. There is a resolution of the signs and symptoms almost within a week. Prolonged seizures with loss of consciousness, prolonged increase in blood pressure or both may result in permanent neurological deficits if not treated properly. Early recognition in children is important for prompt control of blood pressure or removal of aggravating factors and treatment of epileptic seizures or status epilepticus [8].

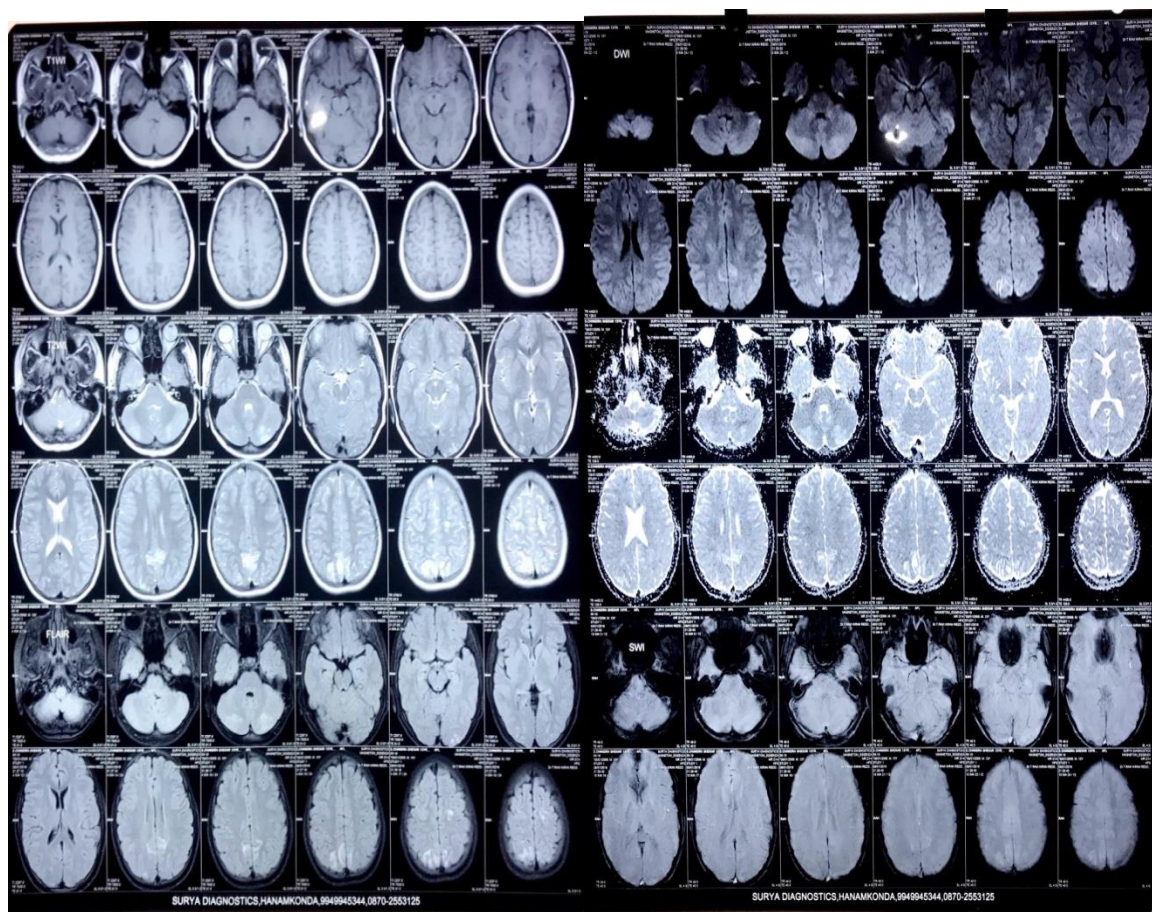


Fig. 2: MRI of brain demonstrating Hyperintensity lesions seen in posterior part of high parietal region along with the surrounding edema suggestive of PRES.

CONCLUSION

Although PRES is a well known condition,

- Initially the patient is to be treated symptomatically.
- Delaying the diagnosis and treatment of this condition may lead to additional morbidity and complications.
- A prompt recognition and precocious treatment may prevent from further complication and also help in speedy recovery of the patient.

ABBREVIATIONS

PRES: Posterior reversible encephalopathy syndrome

RPLS: Reversible posterior leukoencephalopathy syndrome

ASO: Anti streptolysin O

MRI: Magnetic resonance imaging

CT: Computed tomography

EEG: Electroencephalogram

LRTI: Lower respiratory tract infection

USG: Ultrasound sonography

ADEM: Acute disseminated encephalomyelitis

AUTHORS CONTRIBUTIONS

All the authors contributed equally in the completion of the case report.

CONFLICT OF INTERESTS

Declared none

REFERENCES

- [1]. Jennifer E Fugate, Alejandro A Rabinstein. Posterior reversible encephalopathy syndrome: clinical and radiological manifestations, pathophysiology and outstanding questions. *The lancet neurology*. 14(9), 2015, 914-925.
- [2]. Ravindra K Garg, Neeraj Kumar et al. Posterior reversible encephalopathy syndrome in eclampsia. *Neurologia India*. 66(5), 2018, 1316-1323.
- [3]. Kenji Ishikuri, Yuko Hamasaki et al. Posterior reversible encephalopathy syndrome in children with kidney diseases. *Pediatric nephrology*. 27, 2012, 375-384.
- [4]. WS Bartynski. Posterior reversible encephalopathy syndrome, part 2: controversies surrounding pathophysiology of vasogenic edema. *American Journal of Neuroradiology*. 29(6), 2008, 1043-1049.
- [5]. Stott VL, Hurrell MA et al. Reversible posterior leukoencephalopathy syndrome: a misnomer reviewed. *International medical journal*. 35, 2005, 83-90.
- [6]. Marlene Fischer, Erich schmutzhard. Posterior reversible encephalopathy syndrome. *Journal of neurology*. 64, 2017, 1608-1616.
- [7]. Granata G, Greco A et al. Posterior reversible encephalopathy syndrome- Insight into pathogenesis, clinical variants and treatment approaches. *Autoimmune reviews*. 14(9), 2015, 830-836.
- [8]. Giuseppe Servillo, Francesca Bifulco et al. Posterior reversible encephalopathy syndrome in intensive care medicine. *Intensive care medicine*. 33, 2007, 230-236.

How to cite this article: Rishitha Krishna Kantheti, Sowmya Tirumala, Joseph Priyatham Reddy Thumma, Rajender Penthalala, Dr. Devender Kodati. Hypertension induced posterior reversible encephalopathy syndrome in children: A report of two cases. *Int J of Allied Med Sci and Clin Res* 2019; 7(2): 306-310.