International Journal of Allied Medical Sciences and Clinical Research (IJAMSCR)

ISSN:2347-6567

IJAMSCR |Volume 5 | Issue 1 | Jan - Mar - 2017
www.ijamscr.com

Research article *Medical research*

Clinical study of hollow viscous perforation

Dr sreenivasa.P[1], Dr Santosh kumar.V[2] and Dr Avinash gottumukkala[3]

[1]*Assosiate Proffesor, Department of General Surgery, M N R medical College & Hospital, Fasalwwadi, Sangareddy. Telangana. 502294*

[2]*Dr V Santosh kumar, Postgradute, Department of General Surgery, M N R Medical College & Hospital, Fasalwwadi, Sangareddy. Telangana. 502294*

[3]*Dr Avinash Gottumukkala, Postgradute, Department of General Surgery, M N R Medical College & Hospital, Fasalwwadi, Sangareddy. Telangana. 502294*

***Corresponding author: Dr Sreenivasa.P**

Email: drsreenivasms@yahoo.com

ABSTRACT

Peritonitis due to hallow visceral perforation is commonly encountered in surgical practice it is defined as inflammation of the serosal membrane that lines the abdominal cavity and the organs contained therein. Peritonitis is often caused by introduction of an infection into the otherwise sterile peritoneal environment through perforation of bowel, introduction of a chemically irritating material, such as gastric acid from a perforated ulcer. The different modes of presentation of cases may be misleading the diagnosis of its origin. A prospective observation of 50 cases of perforation peritonitis in the Dept. of Surgery in M.N.R Medical college and hospital sangareddy during the period of October 2014 to September 2016 were to be included in the study.

Keywords: Peritonitis, Pneumopetitoneum, Omental patch

INTRODUCTION

The spectrum of etiology of perforation in tropical countries continues to be different from its western counterpart. In contrast to western countries where lower gastro-intestinal tract perforations predominate, upper gastro intestinal tract perforations constitute the majority of cases in India [1]

Peritonitis secondary to perforation of the gastro intestinal tract, a common occurrence in india, requires emergency surgical intervention and is associated with significant morbidity and mortality rates.

Smoking and use of non-steroidal anti inflammatory drugs are important risk factors for perforation [2]

Diagnosis is usually made clinically and confirmed by the presence of pneumoperitoneum on radiographs. The investigations should be such that it gives a definitive diagnosis in a short time. With the research and development in the field on surgery and intensive care facilities the treatment has swing towards operative approach compared to conservative approach. Sir Cuthbert Wallace puts it “it is better, to check than being waiting”. In case of peritonitis i.e. early surgery has got advantages over the late surgery. It is necessary

to know the current surgical procedures for different perforation..

Operative management consists of time honoured practice of omental patch closure, but this can also be done by laparoscopic method.

Ileal perforation is a common surgical emergency in the tropical countries. It is reported to constitute the 5th commonest cause of abdominal emergencies due to high incidence of enteric fever and tuberculosis in these countries

The mortality rate from ileal perforations remains high in developing countries, despite improvement in critical care and timely surgical intervention [3]. In the presence of advanced anaesthesia of today and tremendous improvement of resuscitative measures, every patient with ileal perforation should be recommended for surgery.

Causes of hollow viscus perferation

Source regions	Causes
Stomach	Peptic ulcer perforation Malignancy e.g. adenocarcinoma, lymphoma,
Duodenum	Peptic ulcer perforation
Small bowel	Salmonella enteritis Ischemic bowel, Crohn's disease Meckel diverticulum, intestinal tuberculosis Incarcerated hernia (internal and external) Parasitic peritonitis by round worm Closed loop obstruction
Malignancy (rare)	
Large bowel and appendix	Ishcemic bowel Diverticulitis Malignancy Ulcerative colitis and Crohn's disease Appendicitis Colonic volvulus Amoebic colitis

Antibiotic selection

When selecting an antibiotic for the patient of peritoneum, the following consideration should be kept in mind:

1. It should be directed against the well known typical spectrum of aerobic and anaerobic organisms.
2. It should achieve effective concentration in the blood and peritoneal fluid.
3. It should be backed by the results of valid clinical trials.
4. It should be safe and devoid of serious toxicities.

The emerging concepts concerning antibiotic treatment suggests that less in terms of the number of drugs and the duration of treatment is better.

INVESTIGATIONS LABORATORY STUDIES

A complete blood cell (CBC) count with differential count in patients with suspected peritoneal infection.Most patients have leukocytosis (>11,000 cells/mm^3).

Urine analysis is essential to rule out urinary tract diseases (e.g. pyelonephritis may mimic peritonitis). However patients with lower abdominal and pelvic infection often demonstrate WBC in the urine and microhematuria. The presence of frank pyuria, large number of red

blood cells and bacteria in the specimen suggest an urinary source of patient's symptoms. Serum amylase and lipase levels are raised in patients with possible diagnosis of pancreatitis

Widal test

This is a test for the measurement of H and O agglutins in the patient's sera for typhoid infection. The results are interpreted according to the agglutination titre. The test is taken to be positive if titre is greater than 1/100 for O agglutins and 1/200 or more for H agglutins or rise in titre is demonstrated.

Peritoneal fluid

A peritoneal fluid should be evaluated for glucose, protein, and lactate dehydrogenase, and gram stain, aerobic and anaerobic culture to rule out peritoneal infection.

Routine intraoperative peritoneal fluid cultures is done in defined acute disease entities (i.e. gastro-duodenal ulcer perforation, appendicitis, and diverticulitis, perforation of the colon caused due obstruction or ischemia). A peritoneal fluid amylase should be done if pancreatitis or pancreatic leak is suspected; creatinine level when a urinary leak is suspected. The peritoneal levels should be compared with serum levels. The antibiotic regimen is based on operative culture data in only 8-10% of the time (Bilik, 1998).

Radiographs [4]

The presence of free, intra abdominal gas almost always indicates perforation of a hollow viscus. The commonest cause is perforation of peptic ulcer; other much less common causes are diverticulitis and malignant tumours. About 70% of perforated ulcers will demonstrate free gas, a phenomenon that is also never seen in cases of a perforated appendix. As little as 1 ml of free gas can be demonstrated on a radiograph, either ran erect chest, or a left lateral decubitus abdominal film Radiographic techniques are important and the patient should remain in position for 5-10 minutes.

The clinical condition of the patient will determine the radiographic technique used. Chest films taken with the patient in an upright position ideal for demonstrating free air because the X-ray beam strikes diaphragms tangentially at their highest point.

A lateral decubitus or even a supine radiograph is used in patients are too ill to be moved. Left lateral decubitus views of the abdomen are sensitive for detecting small amount of free air interposed between the edge of the liver and the lateral wall of the peritoneal cavity. Care should taken to include the upper abdomen, because air rises to the highest point of abdomen, which frequently is beneath the lower ribs. Films obtained with patient in the right lateral decubitus position are also helpful, but gas in stomach or colon may obscure small amounts of the free gas. Pneumo- peritoneum can be detected in 76% of cases using an erect film but when a left lateral decubitus projection is included, a pneumoperitoneum can be demonstrated in nearly 90% of cases.

Signs of a pneumoperitoneum on the supine radiograph

Right upper quadrant gas

- Perihepatic
- Subhepatic
- Morrison's pouch
- Fissure for the ligamentum teres

Rigler's or Double wall sign: Ligament visualization Falciform (ligamentum teres)
Umbilical (inverted 'V' sign), medial and lateral
Urachus Triangular air the cupola sign
Football or air dome

Pseudopneumoperitoneum [4]

A number of conditions have been described which simulate free air in the peritoneal cavity, i.e. pseudopneumoperitoneum. These are important because failure to recognize them may lead to an unnecessary laparotomy in search of a perforated viscus. These are

- Chilaiditi syndrome is distended bowel, usually hepatic flexure of the colon, interposed between the liver and the diaphragm.
- Subdiaphragmatic fat
- Curvilinear pulmonary collapse
- Uneven diaphragm
- Distended viscus
- Subphrenic abscess

Pneumoperitoneum without peritonitis [4]

Occasionally, asymptomatic patients or those with very minimal signs and symptoms are found to have a pneumoperitoneum.

Causes of pneumoperitoneum without peritonitis are

1. Silent perforation of a viscus which has sealed itself
2. Postoperative setting
3. Laparoscopy
4. Perforated jejunal diverticulosis
5. Peritoneal dialysis

Use of contrast media in suspected perforation

Not infrequently, a patient presenting with severe upper abdominal pain had equivocal clinical signs and no free gas is demonstrable on plain radiographs. Water soluble contrast medium (about 50 ml) is given by mouth or injected through a naso- gastric tube, with the patient lying on his/her right side.

The patient can be examined fluoroscopically or the abdominal radiographs can be repeated after the patient has remained in this position for 5 minutes. Duodenal ulcers which have perforated but show no free gas will normally demonstrate evidence of a leak of contrast medium. It is used more frequently to delineate anatomy and confirm a contained perforation, especially if non-operative management of the perforated ulcer is being considered. Patients with pancreatitis may have an oedematous stretched duodenal loop. If the patient's clinical state is such that there is risk of it being inhaled and causing pulmonary oedema ionic water soluble contrast medium should not be given

Appendicular perforation [5, 6]

A ruptured appendix may rarely lead to the development of a small amount of free intraperitoneal air. The obstructed appendiceal lumen prevents larger collection of gas from escaping into the peritoneal cavity except in case of a ruptured gas containing abscess. It may show a fecolith in the right lower quadrant.

Ultrasound [5, 6]

Ultrasound examination allows very rapid screening of patients in suspected patients, for triage of patients who are to undergo more invasive imaging testing. Visualization of a interference echo with a shifting phenomenon is very strong indication of the presence of free air in the abdominal cavity. This interference echo can be defined as the interruption of echo transmission due to the space between the parietal peritoneum and the surface of the liver. This free air within the peritoneal cavity can be shifted by changing the patient's position. Unlike free peritoneal fluid, the localised exudates does not change shape or location when the patient's position is altered. Other findigs are subphrenic or subhepatic collections. Moreover ultrasound can detect ascetic fluid as little as 10 ml. Ultrasound guided paracentesis is safe and will yield a fluid aspirate in nearly 100% compared to clinical diagnosis with a sensitivity of 58%.

Computed tomography of abdomen [7]

'CT' scan provides more information and is the preferred diagnostic test if the differential diagnosis remains wide.

The computed tomography diagnosis of perforation was based on the direct findings of extraluminal air or gastrograffin. Indirect findings are an abscess or inflammatory mass surrounding an enterolith in the region of appendix or a bowel wall related phlegmon or abscess with fluid in the mesentery or surrounding radiopaque foreign body. Computed tomography is a valuable method in the diagnosis of alimentary tract perforation. The diagnosis can be established rapidly without patient preparation and with a high sensitivity.

Treatment

Once the clinical diagnosis of peritonitis is made, rapid institution of both physiologic support and aggressive anti-infective therapy are imperative [8].

Early surgical intervention is to be preferred to a wait and see policy

Primary objectives in the treatment of peritonitis are:

1. Resuscitation
2. Initiation of antibiotic therapy
3. Elimination of the source of bacterial contamination
4. Reduction of the bacterial inoculums
5. Continued metabolic support

Surgical Management

Surgery remains an important therapeutic modality for all cases of peritonitis. Operative management should be directed towards the control of the source of contamination. This can be accomplished by closure of the perforation, resection of the perforated viscus, or exclusion of the affected organs from the peritoneal cavity.

The secondary goal of operative management is to reduce the bacterial inoculum with the intent to prevent recurrent sepsis. Standard intraoperative techniques to accomplish these goals include swabbing and debriding fibrin, blood and necrotic material and copious irrigation of the peritoneal cavity which are generally accepted and practiced maneuvers.

Planned repeated laparotomy for generalized peritonitis is a technique developed to prevent recurrent sepsis by repetitive abdominal exploration to debride necrotic material and drain abscesses.

Perforated peptic ulcer

Peptic ulcer perforation has been classified as 'free perforation' when duodenal/gastric contents spill into the peritoneal cavity. It is called 'contained perforation' when a full thickness hole is created by an ulcer but free spillage is prevented by contiguous organs resulting in walling off. The term penetrating ulcer has been used to describe perforation in to the pancreas. It is also type of contained perforation. Perforation is less frequent than bleeding but more common than obstruction.

Pyloroduodenal perforation occurs six to eight times more commonly than gastric perforation. Gastric perforation is more common in elderly. Prepyloric perforation and duodenal perforation occur more often in young men. 90% of perforated duodenal ulcers are seen on anterior wall. 60% of gastric perforations occur lesser curvature and 40% are distributed all over the stomach. A recent review has shown that 52% of patients of perforation are on ulcerogenic agents. Gastrografin study or CT scan of the abdomen may be required to determine the cause of unexplained abdominal pain [9].

There are two types of patients with perforation: Acute perforation in whom history of less than 3 months or no history of ulcer symptoms is present and others who have chronic ulcer perforation with symptoms of more than three months duration.

Acute perforation of duodenum is now estimated to occur in 5-10% of patients. with ulcer most of whom are between the age of 40-50 years of age. A history of peptic ulcer disease is present in 60-70% of patients.

All patients of perforation on NSAID therapy should be operated. The recurrence of ulcer perforation was reported as 7% in case of NSAID users after simple closure. The operation preferred is simple closure followed by 8 weeks – omeprazole therapy

Perforated gastric ulcer tends to occur in older patients and may be associated with adenocarcinoma. This leads to higher mortality rates than the routine perforated duodenal ulcer.The operation of choice is gasterectomy as more than 10% of benign looking ulcers may be malignant[10]

Age over 75 years, coexisting cardiac or pulmonary disease, perforation of the cardia or body of the stomach, lapse of more than 12 hours between start of symptoms and operation, and type of operation had a significant influence on hospital mortality [11].

When a patient with peptic ulcer perforation presents to the surgeon, the surgeons has to make five therapeutic decisions [12].

1. Whether on operation is to be performed or not.
2. Whether patient is stable to undergo operation.
3. Whether to do an omental patch closure or a definitive surgery.
4. Type of definitive surgery to be done.
5. Whether availability of new drugs should influence the choice of operation.

Surgical technique [13]

The perforated duodenal ulcer closure was described by Graham. The two principal techniques used in closure are

1. Simple opposition of the perforation
2. Omental patch technique

Apposition should be performed using three or occasionally four sutures using suture materials such as vicryl, dexon or polydioxonone. The sutures should be through the full thickness of the duodenal wall at least 1 cm from the edge of the defect. The omental patch should be used if the perforation is large or if the duodenum

is so indurated that it is unlikely to hold sutures. Sutures are placed just to bring about apposition but should not be tied to approximate the ulcer edges. Adjacent omentum should be brought up with an intake vascular pedicle. The sutures are then successively tied from the superior to the inferior side of the perforation, so as to tampon the perforation with the living omental pedicle graft. The disadvantage of sewing the ulcer shut, even if this is technically feasible, is that the omental patch placed over such a closure does not have the surface contact with the anterior duodenal serosa.

In cases of large perforation or the scarred, inflexible duodenal wall that makes simple closure difficult two options are available.

1. Conversion of the perforation into a Heineke-Mikulicz pyloroplasty.
2. Serosal patch with proximal Jejunum

Laparoscopic approach [14]

Laparoscopic techniques have been applied to virtually all abdominal procedures and perforated duodenal ulcer is no exception. It was introduced by Nathanson in 1990. Two laparoscopic approaches have been developed

1. Suturing technique
2. Fibrin plug technique

Pneumoperitoneum is established by either open or closed method and a 10 mm trocer is inserted at the umbilicus. Exploratory laparoscopy is performed to confirm the diagnosis and to ensure that laparoscopic closure is technically feasible. Working ports are then placed in the right hypochondrium (for grasper), left hypochondrium (for scissors, needle holder) and epigastrium (for suction irrigator).

Primary closure is performed using a 5 mm needle holder and a no 2-0 absorbable suture mounted on a half circle needle. The omental patch technique is performed as for open procedure. After closure, the peritoneum is cleaned through saline lavage and aspiration. An intraluminal endoscope can be used as necessary to help identify site of perforation, guide the repair and pull omentum into the perforation.

The fibrin plug technique involves delivering solution of fibrinogen and thrombia through separate lumina of a double lumen catheter. As the two solution meet at the perforation, a fibrin plug is formed which seals the perforation.

Laparoscopy seems particularly useful for patients withoutpneumo- peritoneum, or for those who present with atypical symptoms and signs. Postoperative would pain is minimized, allowing early mobilization and a more rapid resumption of daily activities. Laparoscopy is also associated with a significant decrease in the rate of postoperative chest complications.

Perforation associated with hemorrhage

When perforation of a duodenal ulcer in accompanied by overt gastrointestinal bleeding, a concomitant posterior ulcer should be suspected. Duodenum is opened though the anterior perforation for suture control of the posterior bleeding ulcer. An acid reductive procedure is mandatory – two alternatives being truncal vagotomy or proximal gastric vagotomy.

AIMS AND OBJECTIVES

- To study the correlation of clinical, radiological, bio-chemical & operative findings in patients with perforation peritonitis.
- To study the different sites of perforation & their clinical presentation.
- To study the outcome in patients with perforation peritonitis in relation to
  - ✓ Duration of surgery
  - ✓ Post operative pain
  - ✓ Post operative bowel sounds
  - ✓ Oral diet
  - ✓ Hospital stay and post operative complications

MATERIAL & METHODS

- A prospective observation of 50 cases of perforation peritonitis in the Dept. of Surgery in M.N.R Medical college and hospital sangareddy during the period of October 2014 to September 2016 were to be included in the study.
- **Inclusion criteria:** Patients with peritonitis due to perforation.(hollow viscus perforation eg. Gastric perforation, Duodenal perforation Small & Large bowel perforation, Appendicular perforation.)

- **Exclusion criteria:** Patients with peritonitis other than perforation(primary peritonitis eg. Spontaneous, tuberculous & post operative eg. Leak of anastomosis or suture line, stump insufficiency) & patients who are not operated.
- A complete history is taken & all the complaints are noted.
- Thorough examination is done clinically & all important signs & symptoms are noted.
- All routine investigations like CBP, CUE, RBS, urea, creatinine, Sr.electrolytes, X-Ray erect abdomen, X-Ray chest are done & recorded. If any special investigations like USG & CT are required they are done & recorded.
- After thorough resuscitation & pre-operative preparation patient is posted for surgery.
- All the intra-operative findings are noted.
- Site & size of perforation are noted.
- Colour, quantity & smell of peritoneal fluid are noted. Fluid is sent for culture & sensitivity.
- All the cases are followed during the post operative period daily till discharge. After discharge followed at intervals of 1week & 1 month.
- All the above data is collected in a proforma prepared for the study



Figure 1: X-ray abdomen gas under diaphragm

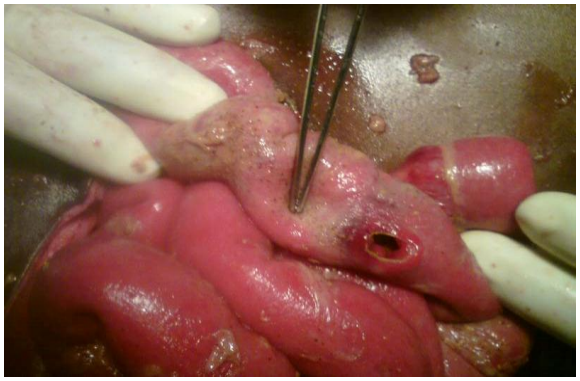

Figure 3: Ileal perforation

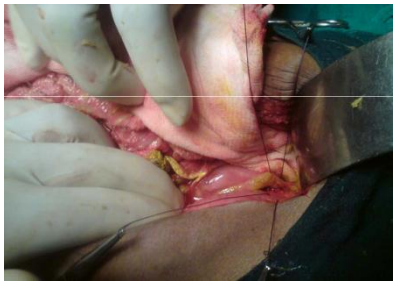

Figure 2: Duodenal ulcer perforation

OBSERVATIONS AND RESULTS

- This study was conducted in MNR HOSPITAL Sangareddy.A total of 50 patients admitted with particular criteria fixed during the study period taken as universe & cases were selected randomly.
- The **age distribution** is as shown in table 1.The highest no. of patients encoutered in this

series were in age group 45 years & above followed by the age group of 19-45 yrs.

- The mean age group in the study was 38.36 years.
- This is comparable with the study by **Rajender Singh Jhobta** who studied 504 cases of perforation peritonitis in which the mean age was 36.8 years (range from 3 to 90 years).
- In this present study the youngest one is about 13 years & the eldest is 80 years.
- The present study is also comparable with the study by **Girish G** study on **peritonitis secondary to hollow viscous perforation** in which the mean age is **38.56** years.
- The mean age was 21.88 years ± 14.51 (range 4–70) in the study **Causes and treatment outcome of perforation peritonitis in north eastern Nigeria** by Nuhu Ali, Bata Mtaku Gali in 2010.
- **Sex distribution**
- The ratio of men to women with all types of perforation irrespective of site & pathological condition was 11.5: 1 in the present study.
- Different authors have find variable results with regards to the sex ratio but ratio of males is high in all the studies.

Males are most commonly effected may be because of the habits like cigarette smoking, alcohol consumption etc.

Table 1 Comparision of M:F ratio with other studies

Author	Period	M : F ratio
Nuhu Ali, Bata Mtaku Gali. (nigeria)[15] (N=153)	2010	2.73 : 1
Mathikere Lingaiah Rama chandra. Et,al[16] (N=50)	2003-2004	9 : 1
Shahida P Afridi & Et,al(pakistan)[17] (N=300)	2008	2.1 : 1
Prajakt V Patil & Et,al[18] (N=150)	2012	5.25 : 1
Thammegowda kemparaj[19] (N=369)	2001-2010	4.5 : 1
Present study (N=50)	2010-2012	11.5 : 1

Site of perforation

In the present study majority of the cases had duodenal perforation about 52%, followed by appendicular perforation about 18%, next is gastric perforation(16%). Small bowel constitutes of 14%(ileal 12%, jejunal 2%.)

Table 2 Comparison of site of perforation with other studies

Author	Duodenal (%)	Gastric (%)	Appendicular (%)	Small bowel (%)	Colon (%)
ShahidaPAfridi,et al[17] (N=300)	43	13	5	31	8
Prajakt V Patil, et al[18] (N=150)	43	13	4	40	0
Shyam kumar gupta, et al[20] (N=400)	44	3	24	14	3
Mathikerelingaiah, et al[16] (N=50)	64	0	12	24	0
Nuhuali,etal[15] (N=153)	16.3	6	14.3	64	0
PresentStudy (N=50)	52	16	18	14	0

Clinical features

- All the cases presented with pain abdomen. And the other predominant symptoms are guarding, rigidity, vomitings, fever, obliteration of liver dullness & constipation.
- Signs include tachycardia, tachypnea, hypotension, dehydration & shock.

- In 26 cases of DU perforation, liver dullness was obliterated in 23 cases.
- Past history of pain abdomen suggestive of peptic ulcer disease was present in 38% of cases.

Table 3 Comparison of clinical features with other studies

Author	Pain (%)	Vomiting (%)	Guarding & rigidity (%)	Fever (%)	Obliteration of liver dullness (%)	Distension of abdomen (%)
Mathikere lingaiah,etal[16] (N=50)	100	64	90	78	72	90
ShyamK Gupta, et al[20] (N=400)	98	80	88	20	-	76
AhmerA Menon,etal (N=311)	97	58	85	91	74	91
Nuhu ali, et al[15] (N=153)	98.9	58	89	70.6	60	70.6
Thammegowda, et al[19] (N=369)	100	81	86	51	72	73
Present study (N=50)	100	76	92	84	76	76

Radiological findings

- The important radiological investigations in cases of perforation peritonitis are X-ray & USG, if needed we can go for CT abdomen.
- If X-ray chest shows pneumoperitoneum that is air under Rt dome of diaphragm it is definite diagnosis of hollow of hollow viscous perforation.In most of the appendicular perforations pneumoperitoneum is absent.
- In the present study one case has multiple air fluid levels in X-ray abdomen suggestive of obstruction.

Table 4 Comparison of presence of pneumo-peritoneum with other studies

Author	year	Pneumoperitoneum(%)
Thammegowda kemparaj, etal[19] (N=369)	2001-2010	75
Ahmer A Menon, et al (N=311)	2008-2010	53
Shahida P Afridi, et al[17] (N=300)	2005-2008	70
Present study (N=50)	2010-2012	70

Bio-chemical tests

As shown in table 8 bio-chemical tests altered in 54% of patients in the present study.

Table 5 Comparison of altered bio-chemical tests with other studies

Author	Hypokalemia (%)	Hyponatremia (%)	Raised RFT's (%)
ShahidaPAfridi,et al[17] (N=300)	60	45	9
AhmerAMenon,et al (N=311)	45	56	30
Thammegowdakemparaj[19](N=369)	16	29	21
Present study (N=50)	58	44	24

Complications

The most common post-op complications are wound infection, wound dehiscence, pulmonary complications, dyselectrolytemia & septicemia. Pulmonary complications include ARDS, pneumonia, pleural effusion, etc. Out of all the post-op complications the most commonest is pulmonary complications followed by wound infection

Table 6 Comparison of post-op complications with other studies

Author	Wound infection (%)	Wound dehiscence (%)	Pulmonary complications (%)	Electrolyte imbalance (%)	Septicemia (%)
Thammegowdakemparaj[19](N=369)	30	12	21	19	16
PrajaktVPatil,etal[18](N=150)	20	20	20	-	-
Shyamkumargupta,etal[20](N=400)	16	3.5	6	4	3
AhmerAMemon (N=311)	10.2	4.5	-	6.7	10.6
ShahidaPAfridi[17] (N=300)	42	26	20	-	20
RajenderSJhobta[1] (N=504)	25	9	28	17	18
Presentstudy (N=50)	16	12	18	12	10

Mortality

- The mortality in the present study is 14% (7 cases).
- Out of the 7cases died 5 cases presented late to hospital.(>3days).
- Main causes of mortality are post operative septicemia, pulmonary complications & electrolyte imbalance.

Comparison of mortality rate of present study with other studies is shown in next page.

Table 7 Comparison of mortality with other studies

Author	Year	Mortality (%)
Nuhu ali, Bata mtaku gali[15]. (N=153)	2010	26.1
Rajender s jhobta, et al[1]. (N=504)	2006	10
Shahida p afridi, et al[17]. (N=300)	2008	10.6
Ahmer A Memon, et al. (N=311)	2008-2010	16.7
Shyam kumar gupta, et al[20]. (N=400)	2006-2008	6
Prajakt V patil, et al[18]. (N=150)	2006	13
Thammegowda kemparaj, et al[19]. (N=369)	2001-2010	13.8
Mathikere lingaiah ramachandra, et al[16]. (N=50)	2003-2004	14
Present study (N=50)	2010-2012	14

SUMMARY

- Total 50 cases are included in the study.
- Out of 50 cases 26 are duodenal perforations the most common, 9 are appendicular perforations, 6 are ileal perforations, 8 are gastric perforations & 1 is jejunal perforation.
- All the cases presented with pain abdomen. In cases of DU perforations pain was initially present on right side of abdomen then involved the whole abdomen. 3 cases presented with pain in the upper abdomen.
- In cases of appendicular perforations pain was initially present in RIF but 1case presented with diffuse pain abdomen.

- 5 cases of ileal perforation, 7 cases of gastric perforation & 1 case of jejunal perforation presented with diffuse pain abdomen.
- 5 cases of gastric perforation presented with pain initially in epigastrium, rt hypochondrium then all over the abdomen.
- History of vomiting was seen in 38 cases. Rigidity & guarding was present in 46 cases. Liver dullness obliterated in 38 cases. Urea & creatinine raised in 12 cases. Potassium levels are altered in 29 cases.
- USG abdomen in 44 cases shows free fluid in abdominal spaces & fossae.
- 1 case of appendicular perforation has multiple air fliud levels in abdominal X-ray suggestive of obstruction.
- 4 cases of DU perforation, 2 cases of gastric perforation & 1 case of ileal perforation had mortality.
- One patient of DU perforation who died after 1 month was on ventilator & was in a renal failure.
- Pt who died after surgery for gastric perforation has raised RFT & was in renal failure.
- Out of 7 patients who died after surgery for hollow viscous perforation 5 patients presented to the hospital with symptoms more than 3 days.
- Causes for mortality are late presentation, septicemia & electrolyte imbalance

CONCLUSION

- Delayed presentation and management of hollow viscous perforation peritonitis increases the chances of post operative complications leading to poor outcome in the form of morbidity and mortality.
- The most common age group affected is 45 years and above.
- Duodenal ulcer perforations were more common in the age group of 45 years and above.
- Most of these patients presented with clinical signs of peritonitis to the hospital between 1-3 days after the onset of pain.
- 92% of the patients were male patients and 8% of the patients were females.
- Duodenum (52%) is the most common site of perforation followed by appendicular (18%) and gastric perforation (16%).
- Diagnosis is made clinically and confirmed by presence of pneumoperitoneum (70%) on radiographs.
- Laparotomy with closure of the perforation with omental patch (68%) is the commonest operative management for perforated peptic ulcer.
- The most common postoperative complication observed was lower respiratory tract infection.
- The overall mortality rate was 14%.
- Causes of mortality are late presentation, electrolyte imbalance & septicemia.
- Out of 26 cases of DU perforation & 8 cases of gastric perforation 18 cases had history of NSAID's abuse.
- Duodenal and gastric perforations forms the majority of cases may be because of the spicy food habits and addictions like alcohol consumption, cigarette smoking

REFERENCES

[1]. Rajender Singh Jhobta, Ashok Kumar Attri, Robin Kaushik, Rajeev Sharma, Anupam Jhobta. Spectrum of perforation peritonitis in India – review of 504 consecutive cases. World J Emerg Surg 2006, 1:26.

[2]. Swanes C, JA Soreide O, Soreide, P Bakke, Vollset SE, A Skarstein Smoking and ulcer performation Gut, 41, 1997, 177-80.

[3]. Capoor MR, Nair D, Chintamani MS, Khanna J, Aggarwal P, Bhatnagar D. Role of enteric fever in ileal perforations; An over stated problem in tropics? Indian Journal of Medical Microbiology. 26(1), 2008, 54-7.

[4]. Stuartifield The Acute Abdomen. Textbook of radiology and imaging vol I David Sutton. 7, 1998, 666-8.

[5]. Chavez MC, Morgan BD. Acute appendicitis with pneumoperitoneum radiographic diagnosis and report of 5 cases. 32, 1968, 604-8.

[6]. Gastro intestinal perforation: Ultrasound diagnosis Springer Verla New York. 7(5), 2000, 263-67.
[7]. Perforation of the alimentary tract: Evaluation with Computed Tomography Springer Verlag New York. 25(4), 2000, 373-9
[8]. Jeremy Thompson. Peritoneum omentum, mesentery and retroperitoneal space. In: Bailey and Love's Short practice of surgery, Russell RCG, Norman S Williams, Christopher JK Bulstrode, eds. London: Hodder Arnold; 25(58.)2008, 995-7.
[9]. Yeo CJ, Zinner MJ. In: Shackelford's Surgery of the alimentary tract, 4, 1995, 64-84.
[10]. David V, Felicano MD, Do perforated duodenal ulcer need an acid decreasing surgical procedure now that omperazole is available? Surg North Amer 72, 1992, 369-377.
[11]. Hermansson M, von Holstein CS, Zilling T. Surgical approach and prognostic factors after peptic ulcer perforation. European Journal of Surgery 165, 1999, 566-72.
[12]. Leigh S, Hamby perforated gastric and duodenal ulcer. An analysis of pro- nostic factors. Am Surgeon, 59, 1993, 319-323.
[13]. Wastell C, Nyhus LM. Surgery of the esophagus stomach and small intestine. . In: Perforated peptic ulcer, Macintyre IMC, ed. 5, 2003, 960-7.
[14]. Thompson. Laproscopic plication of perforated ulcer. Results of a selective approach. South Med J88, 1995, 185-9.
[15]. Nuhu Ali*, Bata Mtaku Gali. Causes and treatment outcome of perforation peritonitis in north eastern Nigeria. Surgical Practice 14, 2010, 92–96.
[16]. Mathikere Lingaiah Ramachandra, Bellary Jagadesh, Sathees B.C. Chandra. Clinical Study and Management of Secondary Peritonitis due to Perforated Hollow Viscous. Arch Med Sci. 3(1), 2007, 61-68.
[17]. Shahida P Afridi*, Faiza Malik, Shafiq Ur-Rahman, Shahid Shamim and Khursheed A Samo. Spectrum of perforation peritonitis in Pakistan: 300 cases Eastern experience World Journal of Surgery doi:10.1186/1749-7922-3-31, 2008, 3(31).
[18]. Prajakt V. Patil, Manmohan M. Kamat, Milan M. Hindalekar. Spectrum of Perforative Peritonitis- A Prospective Study of 150 Cases. Bombay Hospital Journal, 54(1), 2012
[19]. Thammegowda Kemparaj, Syed Iqbalulla Sha Khadri. Gastrointestinal Perforations - Our Experience. The Internet Journal of Surgery ISSN: 1528-8242
[20]. Shyam Kumar Gupta, Rajan Gupta, Gurdev Singh, Sunil Gupta. Perforation Peritonitis:A Two Year Experience. www.jkscience.org. 12(3), 2010.

How to cite this article: Dr sreenivasa.P, Dr Santosh kumar.V and Dr Avinash gottumukkala. Clinical study of hollow viscous perforation. Int J of Allied Med Sci and Clin Res 2017; 5(1): 177-188.
Source of Support: Nil. **Conflict of Interest:** None declared.