



International Journal of Allied Medical Sciences and Clinical Research (IJAMSCR)

ISSN:2347-6567

IJAMSCR /Volume 4 / Issue 3 / July - Sep - 2016
www.ijamscr.com

Case report

Medical research

Reticulate acropigmentation of Kitamura with mental retardation - A rare case report.

Rajwinder Singh¹, Ashish Dalal², Mayank Kaushik³, Jaswinder Kaur⁴.

¹M.D, Assistant Professor, Dept. of DVL, MMMCH, Kumarhatti, Solan (H.P.), India.

²M.D, Senior resident, Department of DVL, Saheed Hasan Khan Mewati, GMC, Nuh, Haryana, India.

³M.D, Senior Resident, Dept. of Dermatology, Venereology and Leprology, ESI hospital, Delhi, India.

⁴M.D, Assistant professor, Dept. of Physiology, M.M. Medical College & Hospital, Kumarhatti, Solan (H.P.), India.

Corresponding author: Rajwinder Singh

Email id: ashishskincare@gmail.com

ABSTRACT

Reticulate acropigmentation of Kitamura (RAPK) is a rare pigmentary disorder characterized by a network of freckle-like areas of pigmentation. Although RAPK was first considered to be confined to Japan, worldwide case reports have since appeared. We hereby report this case due to its rarity in Indian population and associated mental retardation.

Keywords: Reticulate acropigmentation of Kitamura (RAPK) Rare pigmentary disorder.

INTRODUCTION

Reticulate acropigmentation of Kitamura (RAPK) is a rare pigmentary disorder first described by Kitamura and Akamatsu in Japan in 1943 [1]. Although RAPK was first considered to be confined to Japan, worldwide case reports have since appeared. It is characterized by a network of freckle-like areas of pigmentation which develop on the dorsa of the hands in the first two decades, which may subsequently involve most parts of the body. We hereby report this case due to its rarity in North India and associated mental retardation.

CASE SUMMARY

A 35 year old female presented with 10 years history of appearance of slightly depressed

hyperpigmented macules in a reticulate pattern on the upper limbs, neck region and face. There were no symptoms associated with these lesions. Lesions initially appeared on dorsa of both hands and gradually involved both forearms and later on neck region and face. Patient gave history of darkening of lesions on exposure to sunlight. There was no history of any cutaneous or systemic symptoms. There was no family history of similar lesions. There was history of patient having low intelligence quotient (IQ).

On examination multiple, slightly atrophic, sharply demarcated, hyperpigmented macules were present on bilateral dorsa of hands (Fig 1), bilateral forearms (Fig 2), on all sides of neck and upper chest region (Fig 3). Hypopigmented lesions were not observed. Axillary and inguinal region didn't

show any lesions. Rest of the body was also clear of any lesions. On examination of palms and soles, pitting and breaking of dermatoglyphics was observed (Fig 4). Nails and hair didn't show any abnormality. Patient was sent for psychiatric evaluation of her IQ, which came out to be 45 and thus patient was labelled as having moderate mental retardation

A punch biopsy was taken from hyperpigmented macules and sent for histopathological examination which revealed features of slight epidermal atrophy and increased melanin in basal cell layer (Fig 5).

Thus a diagnosis of acropigmentation of kitamura with moderate mental retardation was made and patient's relatives were counselled about the disease and reassured.

DISCUSSION

Reticulate acropigmentation of Kitamura is classically described as a reticulate pattern of ephelide like, depressed macules on the extensor surfaces of the hands and feet with palmar pitting and interruption of epidermal ridge pattern. Some reports have been consistent with an autosomal dominant familial transmission [2-4], but most cases are sporadic. The lesions usually start in the first and second decades of life and gradually extend onto the extremities and rarely on the face and eyelids. The lesions usually slowly darken over time. Sunlight may aggravate the condition. Histopathologic examination of the lesions demonstrates epidermal atrophy, elongation and melanization of the rete ridges, and an increased proportion of dopa-positive basal melanocytes.

The differential diagnosis of RAPK includes several conditions that involve pigmentary changes presenting with reticulate or mottled hyperpigmentation like acropigmentation of Dohi (RAD), Dowling-Degos Disease (DDD), dyskeratosis congenita, dyschromatosis universalis

hereditaria, Franceschetti-Jadassohn's syndrome and dermatopathia pigmentosa reticularis. Acropigmentation of Dohi also exhibits acral reticulate pigmentation [5], however absence of concomitant hypopigmented and hyperpigmented macules in our case excluded this diagnosis. DDD is also an autosomal dominant pigmented skin disorder characterized by reticular hyperpigmentation on flexor areas such as the neck, axilla, antecubital fossa, submammary area and groin. Rarely hypopigmented macules or papules are observed. Histologically there are pigmented filiform epidermal projections involving the follicular infundibulum as well as the epidermis [6, 7]. However in our case axillae, groins and other flexural areas excluding neck were not involved.

Other pigmentary disorders, such as dyschromatosis universalis hereditaria, incontinentia pigmenti, familial progressive hyperpigmentation, and incontinentia pigmenti acromians of Ito are not only generalized in distribution but have a whorled or streaked pattern of pigmentary change [8].

There are very few case reports of RAPK being associated with other abnormalities in body. Bony anomalies in the form of absence of terminal phalanges of the 2nd, 3rd and 4th toes have been reported but it's not clear whether it as coincidental or linked [9].

The association of mental retardation with RAPK, as in our case, has not been reported earlier to the best of our knowledge. It could not be elucidated whether this association is linked or coincidental.

Unfortunately, there are no effective treatment options for these conditions. So reassuring the patient is the best modality that can be offered, the same was done in our case.

This case is thus important due to its rarity in Indian population and association with mental retardation.

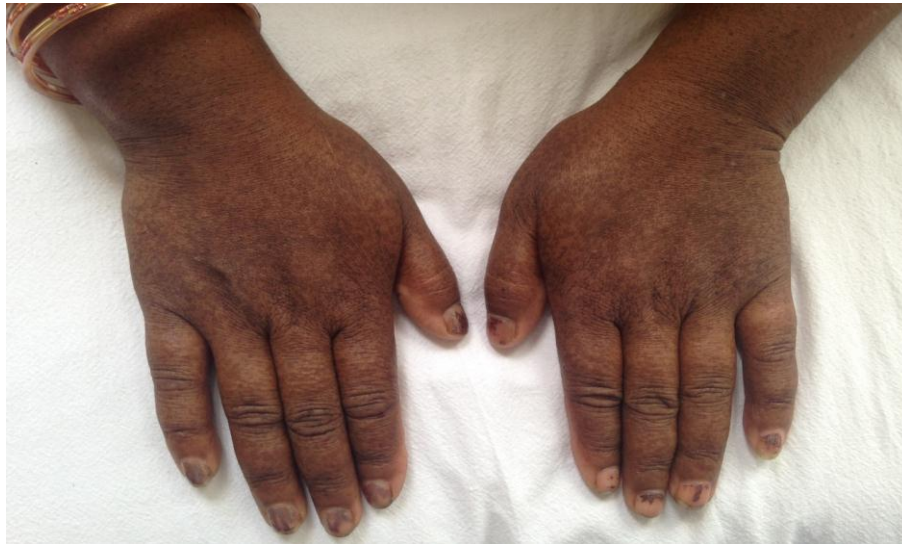

Fig.1 Multiple, slightly atrophic, sharply demarcated, hyperpigmented macules present on bilateral dorsa of hands

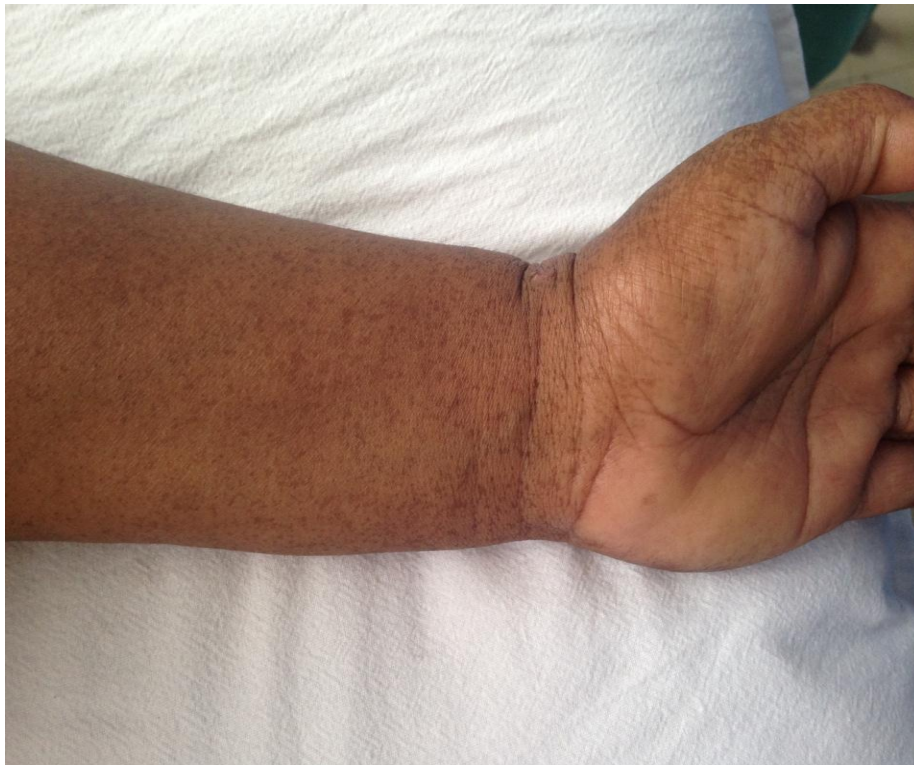

Fig.2 Multiple, slightly atrophic, sharply demarcated, hyperpigmented macules present on forearms

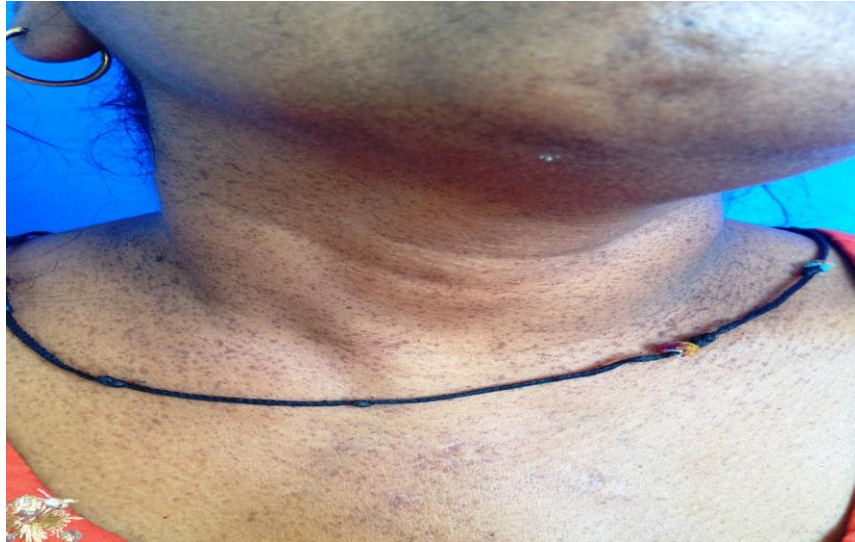

Fig.3 Multiple, slightly atrophic, sharply demarcated, hyper pigmented macules present on all sides of neck and upper chest region

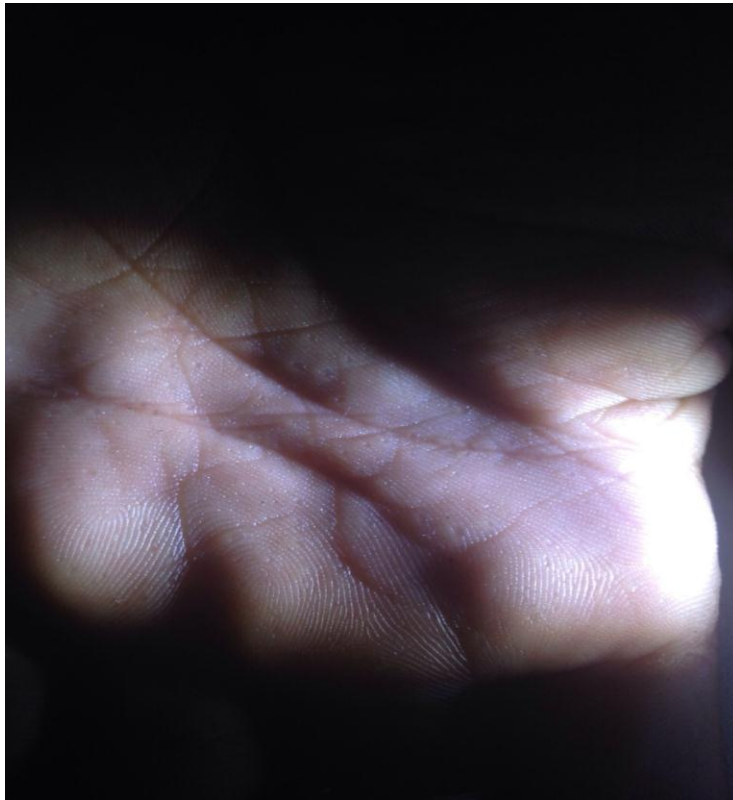


Fig.4 Pitting and breaking of dermatoglyphics was observed on palms

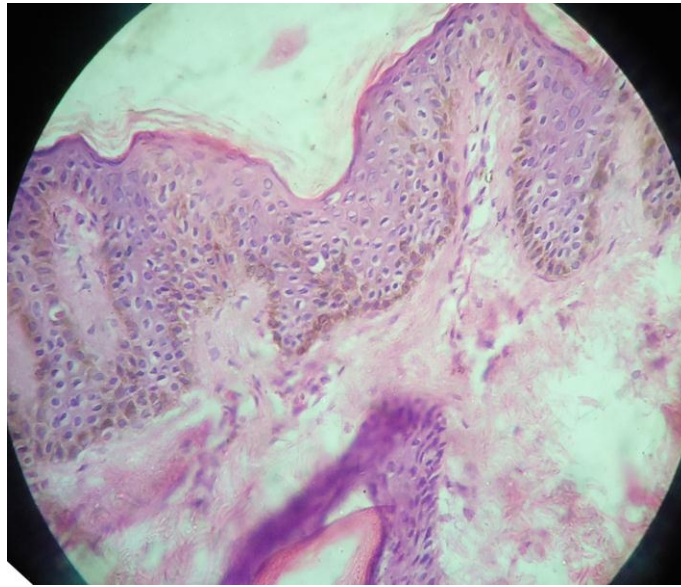


Fig.5 Histopathological examination revealed features of slight epidermal atrophy and increased melanin in basal cell layer.

REFERENCES

- [1]. Kitamura VK, Akamatsu S, Hirakawa K. Eine besondere form der akropigmentation: acropigmentatio reticularis. *Hautarzt* 1953, 152-6. PMID:1306877
- [2]. Kanwar AJ, Kaur S, Rajagopalan M. Reticulate acropigmentation of Kitamura. *Int J Dermatol* 29, 1990, 217-9. PMID:2335418
- [3]. Bajaj AK, Gupta SC. Reticulate acropigmentation of Kitamura. *Dermatologica* 168, 1984, 247-9. PMID:6724082
- [4]. Sharma R, Sharma SC, Radotra BD, et al. Reticulate acropigmentation of Kitamura. *ClinExpDermatol* 14, 1989, 302-3. PMID:2591095
- [5]. Dhar S, Kanwar AJ, Jebrailli R, Dawn G, Das A. Spectrum of reticular flexural and acral pigmentary disorder in Northern India. *J Dermatol* 21, 1994, 598-603. PMID:7962960
- [6]. Alfadley A, Al Ajlan A, Hainau B, Pedersen KT, Al Hoqail I. Reticulate acropigmentation of Dohi: a case report of autosomal recessive inheritance. *J Am Acad Dermatol.* 43, 2000 (1 Pt 1):113-7. PMID:10863235
- [7]. Wu YH, Lin YC. Generalized Dowling-Degos disease. *J Am Acad Dermatol.* 57(2), 2007, 327-34. PMID:17637446
- [8]. Griffiths WAD. Reticulate acropigmentation of Kitamura. *Br J Dermatol* 95, 1976, 437-43. PMID:823955
- [9]. El-Hoshy K, Hashimoto K. Bony anomalies in a patient with reticulate acropigmentation of Kitamura. *J Dermatol* 23, 1996, 713-5. PMID: 8973039.

How to cite this article: Rajwinder Singh, Ashish Dalal, Mayank Kaushik, Jaswinder Kaur. Reticulate acropigmentation of Kitamura with mental retardation - A rare case report.. *Int J of Allied Med Sci and Clin Res* 2016; 4(3): 407-411.

Source of Support: Nil. **Conflict of Interest:** None declared.