



## International Journal of Allied Medical Sciences and Clinical Research (IJAMSCR)

IJAMSCR | Volume 2 | Issue 4 | Oct-Dec- 2014  
www.ijamscr.com

Research article

Medical research

### Prevalence of rare dermtoses manifesting at intertrigenous areas – A prospective study

Praneeth NG, Prasad PVS, Kaviarasan PK.

Department of Dermatology, Venerology and Leprosy, Rajah Muthiah Medical College Hospital,  
Annamalai University, Tamil Nadu, India.

#### ABSTRACT

##### Background

Intertrigo, or intertriginous dermatitis, may be defined as inflammation resulting from moisture trapped in skin folds subjected to friction

Several infections, predominantly fungal, bacterial and mixed infections, eczemas, vesicobullous disorders, papulosquamous diseases can manifest at the intertrigenous areas, when left unattended may lead to chronicity of the illness, serious complications and morbidities.

##### Aims & objectives

To study the rare dermatoses at intertrigenous areas with predisposing factors and clinical presentations and to correlate the dermatoses with obesity.

##### Results

In our study of 180 patients, candidal intertrigo was present in 42 patients, mechanical intertrigo was diagnosed in 30 cases, irritant contact dermatitis was present in 16 patients and acanthosis nigricans in 20 patients. Eleven patients in the study were diagnosed with tinea cruris, 9 with bacterial intertrigo 8 cases with atopic dermatitis. Tinea pedis was present in 7 cases. Intertrigo with both bacterial and fungal infections was diagnosed in 6 cases, seborrhoeic dermatitis in 5 patients and tinea versicolor in 4 patients. Rarer dermatoses like inverse psoriasis were present in 7 cases, Hailey Hailey disease was diagnosed in 3 cases and Darier's disease in 2 cases. 1 case each of hidradenitis suppurativa, pemphigus vegetans and trichomycosis axillaris were present in the study.

##### Conclusion

There was no significant difference in the distribution of dermatoses age group, sex of these patients. Even though a few patients were categorized as grade I and II obese, majority occurred in non obese category. Factors like climate, environment, occlusion and tight dressing were the other predisposing factors. Hence most of the intertrigenous dermatoses could be prevented by taking all measures to prevent occlusion and improving skin hygiene.

**Keywords:** Intertrigo, rare intertriginous dermatoses, obesity, incidence and prevalence of various intertrigenous dermatoses, predisposing factors.

## INTRODUCTION

Intertrigo can be defined as the superficial inflammatory dermatitis occurring where two skin surfaces are in apposition<sup>1</sup>. Apart from the most common intertriginous disorders enlisted in various literatures, the following were noted as rarer entities which could occur in the intertriginous areas<sup>2,3</sup>:

Inverse psoriasis (IP) is a variant of psoriasis, which is localized to flexures and intertriginous areas, in contrast to classical psoriasis, which is classically found over extensor surfaces. IP is usually found in the groins, vulva, axillae, submammary folds, gluteal cleft, umbilicus, intergluteal crease, penis, lips, and web spaces<sup>4</sup>. The aggravating factors are anxiety, smoking, alcohol abuse, steroid medications, excessive perspiration, infections and extremely hot or cold climates, scratching, friction, hard soaps and skin care products, and stress<sup>5</sup>. The lesions are smooth, dry areas of skin that are deep red, inflamed, glistening without any scaling. Topical steroid creams are used as first line of treatment but with caution. Topical tacrolimus, pimecrolimus, cyclosporine are given as long term therapies. Oral methotrexate, cyclosporine, retinoids and biologicals are used for severe and extensive cases<sup>6</sup>.

Hidradenitis suppurativa (HS) is a chronic recurrent, inflammatory, debilitating follicular disease that usually presents after puberty with painful deep-seated, inflamed lesions in the inverse skin areas<sup>7</sup>. The apocrine gland bearing skin is commonly affected and it is predominant in females<sup>8</sup>. It is of autosomal dominant mode of inheritance<sup>9, 10, 11</sup>. Predisposing factors are smoking<sup>12</sup>, obesity<sup>13</sup> and alterations in host defense mechanisms<sup>14</sup>. The onset is insidious, usually developing in otherwise healthy post-pubertal individuals starting initially with slight discomfort or pruritus followed by a tender papule or deep-seated nodule. The disease may also affect the female breast, the neck, the posterior aspect of the ears and the adjacent scalp, the back, and the buttocks. The common sites of involvement are the axillae, submammary, inguinal, pubic and perianal regions. This nodule may slowly resolve; however, it often expands and coalesces with surrounding nodules to form large, painful inflammatory abscesses that may rupture spontaneously, yielding a purulent discharge. The lesion then heals with fibrosis. Sinus tracts may also develop. Treatment of HS is challenging and includes either topical or systemic antibiotics, immunosuppressive drugs or surgical excision or skin grafting. Oral isotretinoin, intralesional steroids are also tried with varying success rates<sup>15</sup>.

Hailey–Hailey disease (HHD) also known as familial benign chronic pemphigus, is a rare autosomal dominant dermatosis<sup>16</sup>. HHD is caused by heterozygous mutations in the ATP2C1 gene on chromosome 3q21–q24, which encodes ATPase 1 (SPCA1), a magnesium-dependent enzyme. This enzyme catalyses the hydrolysis of ATP and also helps to transport calcium ions to the golgi apparatus<sup>17</sup>. Keratinocytes mainly rely on SPCA 1 pumps for loading the golgi stores with calcium in maintaining cytoplasmic calcium homeostasis. When calcium is depleted, it leads to acantholysis there by instability of the desmosomes by altering glycosylation or arrangement of desmosomal proteins<sup>18</sup>. The disease is characterized by recurrent blisters, crusted erosions and warty papules occurring mainly in the sites of friction and flexures, particularly the groin, neck, and axillary, perianal, and submammary regions<sup>19, 20</sup>. Histology reveals acantholysis of the epidermis, giving the appearance of a dilapidated brick wall appearance. Corticosteroids with antibiotics are given either topically or systemically. For persistent recalcitrant plaques, wide excision of the involved area with replacement by split thickness skin grafts are done<sup>19</sup>.

Darier's disease (DD) is a rare congenital acantholytic disorder transmitted as an autosomal dominant trait. Both sexes are affected with equal frequency<sup>21</sup>. The disease usually begins during childhood but can manifest at anytime. The onset is often insidious and slowly progressive. The disease tends to flare up with heat and humidity. Mutations in the ATP2A2 gene located at chromosome 12q-24.1 is responsible for encoding 'sarco (endo)- plasmic reticulum calcium ATPase type 2. This intracellular calcium pump in turn causes severe disruption of calcium homeostasis by the defects in protein expression and/or transport function causing the disease<sup>22</sup>. Multiple, dirty, warty, papular excrescences, symmetrically involving the face, trunk and flexures of the limbs start as small, firm, skin-colored papules that soon become covered with dark, dirty-looking, greasy crusts. These papules coalesce to form large plaques and vegetating growths and rarely large papillomatous and malodorous growths especially on the flexures<sup>23</sup>. Treatment is with high doses of vitamin A, C, E. Oral etretinate, topical flouro uracil, tazarotene are the other modalities<sup>21</sup>.

Pemphigus vegetans (PV) is a rare variant of pemphigus vulgaris, characterized by vegetating plaques in the flexural regions which has two clinical subtypes: the Neumann type and the Hallopeau type<sup>24</sup>. Both types are

characterized by vegetating plaques, the Neumann type begins with bullae and the Hallopeau type begins with grouped pustules. Although the lesions of pemphigus vegetans can occur at any site of the body, intertriginous areas (including axillae, periumbilical, inguinal, and perianal areas) are most commonly involved in PV. The characteristic microscopic findings show intraepidermal vesicles filled with eosinophils and direct immunofluorescence examination demonstrates staining of immunoglobulin G and complements in the intercellular cement substance of the epidermis<sup>25</sup>. Oral or parenteral corticosteroid as pulsed doses is the treatment of choice along with adjuvant oral immunosuppressive drugs, azathioprine and cyclophosphamide.

Trichomycosis axillaris (TA) is a superficial bacterial infection of axillary and pubic hair caused by *Corynebacteria* species<sup>26</sup> with the formation of yellow, red, or black adherent granular nodules visible on the hair shafts. The most common clinical variant is trichomycosis flava (yellow), while rubra (red) and nigra (black) are other less frequent variants<sup>27, 28, 29</sup>. TA occurs in both temperate and tropical climates and is not limited by race or sex. It is usually asymptomatic and the patient is often

unaware of its presence. Yellow, black or red concretions are present on the hair shaft and these may be hard, or soft and nodular, or more diffuse with yellowish sweat or malodor. Itching is rarely observed in few cases. Clipping the affected hairs and the application of 1% aqueous formalin, benzoic acid compound ointments are effective treatments. Anhydrous aluminum chloride is a rapid means of therapy.

## METHODOLOGY

All patients presenting with intertrigo, willing for the study, aged above 14 years, of the both genders were included in the study. Detailed history of the illness was taken according to a predesigned case report form consisting of various details like age, sex, body mass index (B.M.I), obesity grading, symptomatology, predisposing factors, and associated diseases. Thorough clinical examination of the patient was done and findings were noted.

The B.M.I was calculated using the Quetelet index and the patients were divided in to the following groups depending on the BMI values respectively.

$$\text{BMI} = \frac{\text{Mass(kg)}}{(\text{Height (m)})^2}$$

**Table.1** Various grades of obesity with corresponding B.M.I values.

OBESITY GRADE	B.M.I VALUE
Very severely underweight	Less than 15
Severely underweight	From 15.0 to 16.
Underweight	From 16.0 to 18.5
Normal (healthy weight)	From 18.5 to 25
Overweight	From 25 to 30
Obese Class I (Moderately obese)	From 30 to 35
Obese Class II (Severely obese)	From 35 to 40
Obese Class III (Very severely obese)	Over 40.

## RESULTS

A total of 180 patients with symptoms in the intertriginous areas were studied in a 2 year period.

The dermatoses and their distribution patterns were tabulated and shown in table no.2 and table no.3.

## DISCUSSION

IP was observed in 7 patients in our study. Males predominated over females. There was no difference in the age groups. But we found that 5 out of 7 patients were weighing normally with normal body mass index values. Only one patient was obese. There were only sporadic case reports of inverse psoriasis<sup>30</sup>. There were no co morbid conditions in any of our patients. Treatment of psoriasis is also effective for inverse psoriasis. All our patients improved with topical corticosteroids. In flexural/inverse areas, koebner's phenomenon of constant local mechanical and irritation of flexural areas could perpetuate the condition<sup>30</sup>.

Three cases of HHD were reported in our study, with two middle aged females and a male case aged 55 years. In all the cases of HHD, the diagnosis was confirmed by histopathological examination. Except a positive family history in one patient, there were no predisposing factors. Out of three cases, one 48 year old female belonged to grade II obesity.

Darier's disease was diagnosed in 2 cases in the study series, both being middle aged non obese women who had the disease only for the past few years without any family history, contrary to the usual presentation of occurrence of the disease in younger age with recurrences and family history. They were working in hot environment and humid climate. Both the patients had multiple warty papules extensively all over the body. The papules in the retro auricular folds, neck and axillae ruptured to form large erosions, while the lesions on the body had resolved. These patients were diagnosed by the presence of classical clinical features. In addition, they also had lesions in the groin.

Hidradenitis suppurativa was diagnosed in a 42 year old obese grade I male patient, with multiple nodules over his axillae and inguinal folds for the past 6 years with multiple adjacent scars. Though seen in all age groups after puberty and also in both the sexes, predilection for

post pubertal and young age and higher rates of female cases were reported in studies by Greoger et al<sup>31</sup>. The patient had a history of severe stress and was a chronic smoker for many years. Patient was psychologically disturbed with hindrance to his daily activities due to the illness; Patient was treated with oral retinoids and improved symptomatically and retinoids were repeated when the lesions exacerbated.

Pemphigus vegetans was reported in a 58 year old normal weighing male patient in the study group who presented with greasy plaques in his groin bilaterally, associated with itching for 6 months. Pemphigus vegetans is a clinical variant of pemphigus vulgaris mostly associated or followed by vesicobullous lesions on extensor skin surfaces and mucous membranes. There was no history of any drug intake or excess garlic consumption, but history of sun exposure for longer duration was present. Absence of other cutaneous and mucous membrane lesions lead to many differential diagnosis in these skin folds. Skin biopsy was taken and which confirmed the diagnosis. The patient was started on a course of oral steroids and adjuvant immunosuppressive drugs for long term use, following which lesions resolved.

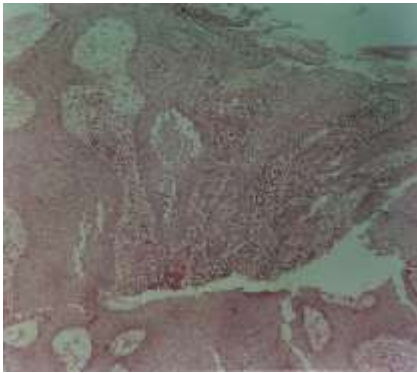
Trichomycosis axillaris was diagnosed in a 32 year old non obese house wife who came for the treatment of facial acne and alopecia and was further examined as the patient was also complaining of bromhidrosis. On examination, multiple yellowish casts were present on both axillary hairs. The patient was asymptomatic except for the malodor. KOH mount and fungal culture were negative, while *Corynebacterium tenuis* was found on bacterial culture. Patient was advised to clip the hair and was prescribed a short course of oral antibiotics. Aluminum hydroxide 1% lotion was prescribed for topical application. The lesions completely cleared with resolution of bromhidrosis.

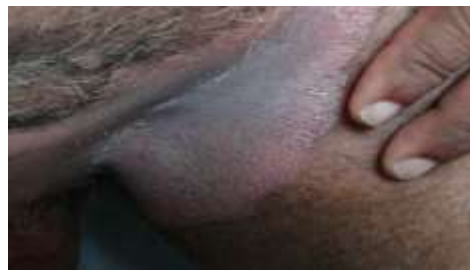

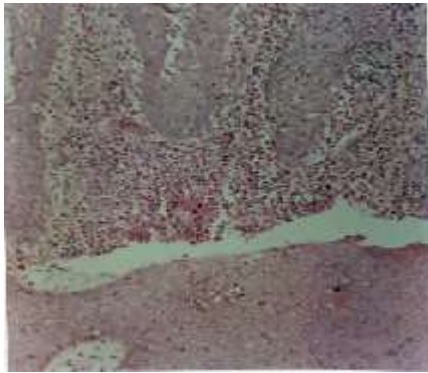
figure.1: IP having erythematous scaly plaques present bilaterally in the groins.

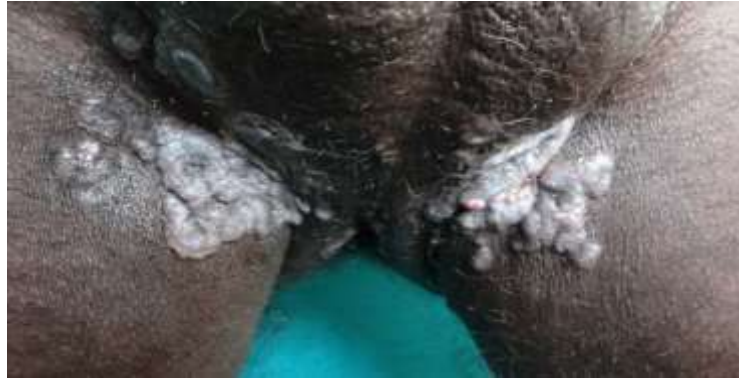

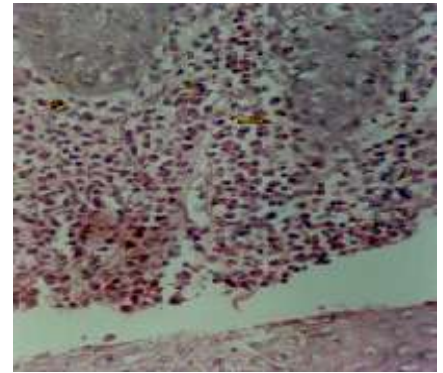
Figure 2: PV with greasy plaques in the groin.



4X



10X



20X

Figure 3: Histopathological section of pemphigus vegetans showing intraepidermal abscesses with eosinophils.

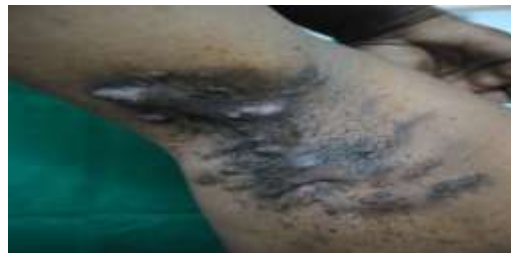

Figure 4: HS with multiple nodules and hypertrophic scars in the axilla.



Figure 5: Yellow hair casts adherent to the axillary hair in trichomycosis axillaris.

Table no.2: Distribution pattern of twenty one dermatoses.

S no	Intertrigenous dermatoses	No	%	M/F	Obesity grade					Age group				
					UW	N	OW	O I	O II	18-30	31-40	41-50	51-60	60>
1	Candidal intertrigo	42	23.3	23/19	4	14	12	11	1	11	7	11	7	6
2	Mechanical intertrigo	30	16.6	19/11	1	11	10	6	2	10	7	4	4	5
3	Acanthosis nigricans	20	11.1	13/7	0	4	2	9	5	11	4	4	1	0
4	Irritant contact dermatitis	16	8.9	5/11	1	10	2	1	2	4	5	3	3	1
5	Tinea cruris	11	6.1	10/1	0	6	4	1	0	5	4	1	1	0
6	Bacterial intertrigo	9	5	5/4	0	8	1	0	0	2	2	2	3	0
7	Atopic dermatitis	8	4.4	6/2	1	3	3	1	0	6	1	0	0	1
8	Inverse psoriasis	7	3.9	6/1	0	5	1	1	0	3	0	2	1	1
9	Tinea pedis	7	3.9	4/3	0	5	0	1	1	2	1	0	4	0
10	Mixed infection	6	3.3	3/3	1	5	0	0	0	2	1	2	0	1
11	Seborrhoeic dermatitis	5	2.8	5/0	0	3	1	1	0	1	1	1	1	1
12	Tinea versicolor	4	2.2	4/0	0	0	2	1	1	0	2	1	1	0
13	Hailey Hailey disease	3	1.7	1/2	0	1	1	0	1	0	0	2	1	0
14	Dariers disease	2	1.1	0/2	0	2	0	0	0	0	0	2	0	0
15	Tinea corporis	2	1.1	2/0	0	0	0	0	2	1	0	1	0	0
16	Tinea manum	2	1.1	1/1	0	1	1	0	0	1	0	1	0	0
17	Vulvovaginal candidiasis	2	0.6	0/2	0	2	0	0	0	1	0	1	0	0
18	Hidradenitis suppurativa	1	0.6	1/0	0	0	0	1	0	0	1	0	0	0
19	Pemphigus vegetans	1	0.6	1/0	0	1	0	0	0	0	0	0	1	0
20	Tinea incognito	1	0.6	1/0	0	1	0	0	0	1	0	0	0	0
21	Trichomycosis axillaris	1	0.6	0/1	0	1	0	0	0	0	1	0	0	0
TOTAL		180	100	110/70	8	83	41	34	14	61	37	38	28	16

No: Number of cases; %: Percentage of cases; M/F: Male and female cases affected by the disease; UW: Underweight; N: Normal; OW: Overweight; O I: Obesity grade I; O II: Obesity grade II.

**Table no.3: Rare intertrigenous dermatoses.**

S N O	DERMAT OSIS	TOTAL	MALE	FEMALE	AGE					OBESITY					SYMPT OMS/ SIGNS	SITE	PREDISP OSING FACTOR S/ ASSOCIA TIONS	OTHE R LESION S
					18-30	31-40	41-50	51-60	60>	U W	N	0	0	0				
					W	W	1	2										
1	INVERSE PSORIASIS	7	6	1	3	-	2	1	1	-	5	1	1	-	Itching-5 Scaling-2 Erythema-6	Groin-5 Umbilicus-4 Axilla-3	Hyperhidrosis-4 Alcoholism-3 Stress-3 Obesity-1	Scaly plaques on Hands-2 Trunk-2 Scalp-1
2	HAILEY HAILEY DISEASE	3	2	1	-	-	2	1	-	-	1	1	-	1	Erosions-3 Blisters-2 Crusting-1	Submammary area-2 Axillae-2	-	-
3	DARIER'S DISEASE	2	-	2	-	-	2	-	-	-	2	-	-	-	Warty papules, Itching	Retroauricular area-2 Neck-1 Axillae-1	Hot working conditions-2 Hot climate-2	Erosions on Trunk-2 Dirty papules on Face-1
4	HIDRADE NITIS SUPPURATIVA	1	1	-	-	-	-	-	-	-	-	-	1	-	Nodules, scars, itching	Axillae, Groin	Obesity, Smoking, 6 years, recurrence	Multiple hypertrrophic scars in axillae
5	PEMPHIGUS VEGETANS	1	1	-	-	-	-	1	-	-	1	-	-	-	Greyish plaques, itching	Groin	Chronic, recurrent	-
6	TRICHOMYCOSIS AXILLARIS	1	-	1	-	1	-	-	-	-	1	-	-	-	Itching, Yellow nodules, malodor	Axillae	Hyperhidrosis, hot working environment & climate.	-

**CONCLUSION**

Intertrigenous areas are commonly affected by various dermatoses. We in our series of 180 patients have

observed 6 rare entities in 15 patients. There was no difference in the age group, sex of these patients. Even though a few patients were categorized as grade I or II



obese, majority occurred in non obese category. This was an interesting observation. Factors like climate, environment, occlusion and tight dressing were the other

predisposing factors. Hence to conclude, intertrigenous dermatoses could be prevented by taking all measures to prevent occlusion and improving skin hygiene.

## REFERENCES

- [1] Patriek Mistiaen, Meike van Halm-Walters, Prevention and treatment of intertrigo in large skin folds of adults: a systematic review. *Mistiaen and Van Halm-Walters BMC Nursing*. 2010; 9: 1-9
- [2] Vary Jay C, O'Connor Kim M. Common dermatologic conditions. *MCNA*. 2011; 98: 445-485.
- [3] Richard AF, Clark and Terrence T Hopkins. The other eczemas. From Moschella and Hurley *Dermatology*, Vol. 1, 3rd Edition, 1992; 486.
- [4] Griffiths CEM, Barker JNWN. Psoriasis. In: Burns T, Breathnach S, Cox N, Griffiths C (eds). *Rook's Textbook of Dermatology*, 8<sup>th</sup> edition. West Sussex: Wiley Blackwell Publishers; 2010: 20.11-5.
- [5] James WD, Berger TG, Elston DM (eds). *Andrew's Disease of the Skin*, 10th edition. Canada: Saunders Elsevier; 2009.
- [6] Guglielmetti Antonio, Conlledo Rodrigo, Bedoya Juliana, Ianiszewski Correa Francisco Julio. Inverse psoriasis involving genital skin folds: Successful therapy with Dapsone. *DermatolTher*. 2012; 15: 1-9.
- [7] Kim de Winter, Hessel H. van der Zee and Errol P Prens. Is mechanical stress an important pathogenic factor in hidradenitis suppurativa?. *Experimental Dermatology*; 2012; 21: 176-177.
- [8] Jemec GBE, Heidenheim M, Nielson NH. The prevalence of hidradenitis suppurativa and its potential precursor lesions. *J Am Acad Dermatol*. 1996; 35:191-4.
- [9] Fitzsimmons JS, Fitzsimmons EM, Bilbert G. Familial hidradenitis suppurativa: evidence in favour of single genetransmission. *J Med Genet* 1984;21: 281-285.
- [10] Fitzsimmons JS, Guilbert PR, Fitzsimmons EM. Evidence of genetic factors in hidradenitis suppurativa. *Br J Dermatol* 1985;113: 1-8.
- [11] Von der Werth J, Williams HC. The natural history of hidradenitis suppurativa. *J Eur Acad Dermatol* 2000; 14:389-393.
- [12] König A, Lehman C, Rompel R, et al. Cigarette smoking as a triggering factor of hidradenitis suppurativa. *Dermatology* 1999;198: 261-264.
- [13] Jemec GBE. Hidradenitis suppurativa. *J Cutan Med Surg* 2003; 7 : 47-56.
- [14] Jemec GBE, Faber M, Gutschick E. Microbiology of hidradenitis suppurativa. *Dermatology* 1996; 193: 203-206.
- [15] Buimer MG, Wobbes T, Klinkenbijnl HG. Hidradenitis suppurativa. *Br J Surgery* 2009; 96: 350-60.
- [16] Cullen DR. Genetic features of familial benign pemphigus. *Br J Dermatol*. 1965; 77:20-23.
- [17] Hu Z, Bonifas JM, Beech J. Mutations in ATP2C1, encoding a calcium pump, cause Hailey-Hailey disease. *Nat Genet*. 2000; 24:61-65.
- [18] Dhitavat J, Fairclough RJ, Hovnanian A. Calcium pumps and keratinocytes: lessons from Darier's disease and Hailey-Hailey disease. *Br J Dermatol*. 2004;150:821-8.
- [19] Palmer DD, Perry HO. Benign familial chronic pemphigus. *ArchDermatol*. 1962;86:493-502.
- [20] Burge SM. Hailey-Hailey disease: the clinical features, response to treatment and prognosis. *Br J Dermatol*. 1992;126:275-82.
- [21] Munro CS. The phenotype of Darier's disease: penetrance and expressivity in adults and children. *Br J Dermatol*. 1992;127:168-171.
- [22] Burge SM, Wilkinson JD. Darier-White disease: a review of the clinical features in 163 patients. *J Am Acad Dermatol*. 1992; 27:40-50.
- [23] Miyauchi Y, Daiho T, Yamasaki K. Comprehensive analysis of expression and function of 51 sarco(endo)plasmic reticulum Ca<sup>2+</sup>-ATPase mutants associated with Darier disease. *J Biol Chem*. 2006; 281:22882-95.
- [24] Burge SM. Bullous eruptions. In: Champion RH, Burton JL, Burns DA. *Textbook of dermatology*. Oxford (UK): Blackwell Scientific Publications; 1998. p. 1874-90.
- [25] Cohen LM, Skopicki DK, Harrist TJ. *Lever's histopathology of the skin*. Philadelphia: Lippincott-Raven, 1997.
- [26] Crissey JT, Rebell GC, Laskas JJ. Studies on the causative organisms of trichomycosis axillaris. *J Invest Dermatol* 1952; 19: 187-97.



- [27] Freeman RG, McBride ME, Knox JM. Pathogenesis of trichomycosis axillaris. Arch Dermatol. 1969;100:90–5
- [28] McBride ME, Duncan WC. Trichomycosis axillaris. Arch Dermatol. 1972; 105:459–60.
- [29] Zavar V. Photoletter to the editor: Trichomycosis (trichobacteriosis) axillaris. J Dermatol Case Rep. 2011;5:36–7.
- [30] Mondal Ashim kumar, Kumar Piyush, Chowdhury Satyendra Nath, Pal Subrata, Debbarman Panchami, Barbhuiya J N, et al. Erythematous plaques in axillae- a report of two cases. J Pak Asso Dermatol. 2011;21: 219-22.
- [31] Gregor BE, Jemec, Heidhenheim Maichel, Neilson Neils Henrik. The prevalence of hidradenitis suppurativa and its potential precursor lesions. J Am Acad Dermatol. 1996; 35: 191-4.